

Volume 10, Number 2, April 2019

p. 112 - 228

Issue online since Tuesday April 09, 2019

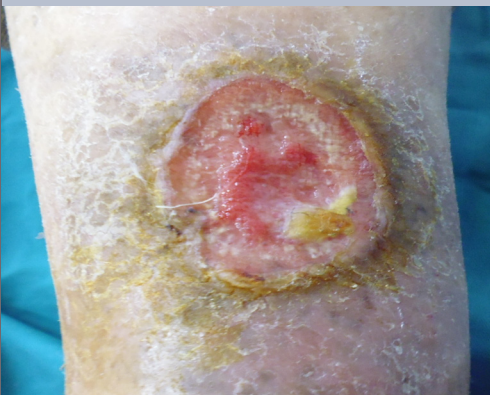ISSN: 2081-9390

DOI: 10.7241/ourd

Our

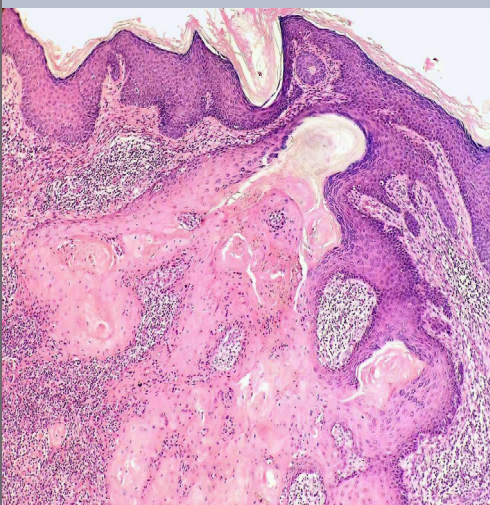
Dermatology Online

www.odermatol.com



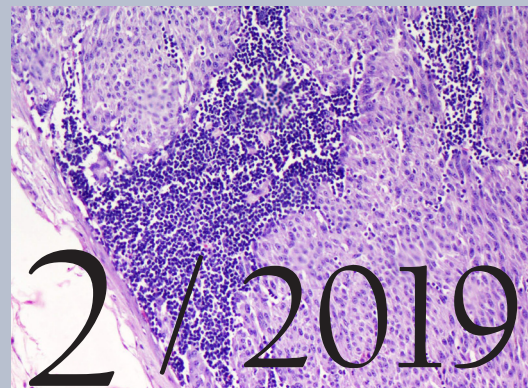
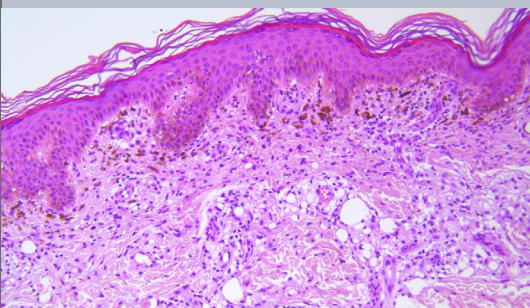
- Anissa Zaouak, Leila Bouhajja, Faten Rebhi,
Raja Jouini, Houda Hammami, Samy Fenniche
Basal cell carcinoma of the leg: an unusual
location

- Vladimír Bartoš
Cutaneous squamous cell carcinoma arising
from the hair follicle



- Ann Sterkens, Vasiliki Siozopoulou,
Evelyne Mangodt, Julien Lambert, An Bervoets
Generalized hyperpigmentation after
pyrimethamine use

- Archana Shivamurthy, Ranjini Kudva,
Annappa Kudva, Padmapriya Jaiprakash
Metastatic spindle cell melanoma on
cytology – a diagnostic challenge



Editorial Pages

e-ISSN: 2081-9390
DOI: 10.7241/ourd

Quarterly
Our Dermatol Online

published since 01/06/2010 years

www.odermatol.com

Editor in Chief:

Piotr Brzeziński, MD Ph.D

Address:

ul. Braille'a 50B, 76200 Słupsk, Poland
tel. 48 692121516, fax. 48 598151829
e-mail: brzezoo77@yahoo.com

Publisher:

Our Dermatology Online

Address:

ul. Braille'a 50B, 76200 Słupsk, Poland
tel. 48 692121516, fax. 48 598151829
e-mail: brzezoo77@yahoo.com

Associate Editor:

Ass. Prof. Viktoriya Kazlouskaya (USA)

Indexed in:

Universal Impact Factor for year 2012 is = 0.7319
system of opinion of scientific periodicals INDEX COPERNICUS (8,69)
(Academic Search) EBSCO
(Academic Search Premier) EBSCO
MNiSW (kbn)-Ministerstwo Nauki i Szkolnictwa Wyższego (7.00)
DOAJ (Directory of Open Access Journals)

Geneva Foundation for Medical Education and Research (GFMER), Google Scholar, Open J-Gate, NewJour,
International Committee of Medical Journal Editors (ICMJE), Genamics JournalSeek, Hinari,
Bielefeld Academic Search Engine (BASE), WorldCat, e-journal, WorldWideScience.org, National Science Library,
LibSearch, Sciencegate, Virtual Science Library (VSL), Wanfang Data, COncnecting REpositories (CORE),
CAB Abstracts, Global Health, Journal Indexed in Directory of Research Journals Indexing,
OAIster: The Open Access Initiative, OAJSE - Open Access Journals Search Engine, Scirus

Previous website:

issue 1.2010

www.ndermatol.like.pl

since issue 2.2010 to issue 3.2011

www.odermatol.like.pl

since issue 4.2011

www.odermatol.com

Previous shortcut:

since issue 1.2010 to issue 3.2011

N Dermatol Online

since issue 4.2011

Our Dermatol Online

Open access journal:

This is an open access journal which means that all content is freely available without charge to the user or his/her institution. Users are allowed to read, download, copy, distribute, print, search, or link to the full or texts of the articles in this journal without asking prior permission from the publisher or the author.

Our Dermatology Online is a international journal that publishes original contributions in the field of dermatology, including papers on biochemistry, morphology and immunology of the skin.

The journal is among the few not related to dermatological associations or belonging to respective societies which guarantees complete independence. Offers a platform for review articles in areas of interest for dermatologists.

OurDermatologyOnline offers article in English as well as in other languages. This is in accordance with the BOAI definition of open access.

Editorial Board

- Abdel-Naser, Mohamed Badawy, Prof. (Egypt)
Abdul-Lateef Mousa Haider, MD (Iraq)
Al Aboutd Khalid, MD (Saudi Arabia)
Al-Kamel Mohamed A., MD (Yemen)
Al-Mashaleh Manal Sulaiman, MD (Jordan)
Abreu-Velez Ana Maria, Prof. (USA)
Abreu Hilda, MD (Uruguay)
Adaskevich Uladzimir, Prof. (Belarus)
Afifi Mustafa, MD (United Arab Emirates)
Aghaei Shahin, Ass. Prof. (Iran)
Akpaka Patrick Eberechi, Prof. (Trinidad and Tobago)
Akyshbayeva Kulbarshin, Prof. (Kazakhstan)
Amichai Boaz, MD (Israel)
Arakelyan Hayk S. Prof. (Armenia)
Arenas Roberto, Prof. (Mexico)
Arif Tasleem, MD (India)
Asuquo Maurice Efana, Prof. (Nigeria)
Auto James, Ass. Prof. (Solomon Islands)
Fatou Barro-Traoré, Prof. (Burkina Faso)
Christian Muteba Baseke, MD (Democratic Republic of the Congo)
Beigi Pooya Khan Mohammad, Prof. (Canada)
Bharti Rakesh, MD (India)
Bonifaz Alexandro, Prof. (Mexico)
Borowska Katarzyna, Ass. Prof. (Poland)
Borruto Franco, Prof. (Monaco)
Bouadjar Bakar, Prof. (Algeria)
Bukhari Iqbal A., Prof. (Saudi Arabia)
Cabo Horacio, Prof. (Argentina)
Chamcheu Jean Christopher, Ph.D (USA)
Chang Patricia, MD Ph.D (Guatemala)
Chihanga Simon, MD (Botswana)
Choon Siew Eng, MD (Malaysia)
Chuh An Tung Antonio, Prof. (Hong Kong)
Crump Vincent, MD (New Zealand)
Daboul Mohamed Wael, MD (Syria)
Daisley Hubert, Prof. (Trinidad and Tobago)
Darlenski Razvigor, MD Ph.D (Bulgaria)
Diouf Assane, Ass. Prof. (Senegal)
Dobrev Hristo, Prof. (Bulgaria)
Doganay Mehmet, Prof. (Turkey)
Dong Huiting, Prof. (China)
Dori Geme Urge, PhD (Ethiopia)
Draganita Ana Maria, MD PhD (Romania)
Drljević Irdina, MD, Ph.D. Ass. Prof. (Bosnia and Herzegovina)
Dubakienė Rūta, Prof. (Lithuania)
Edwards Carl, Ass. Prof. (USA)
Elhassan Elizabeth, MD (Senegal)
Farkas Arpad, MD PhD (Hungary)
Fernandez-Flores Angel, MD Ph.D (Spain)
Fortuna Giulio, Ass. Prof. (USA)
Gołąb Elżbieta, Prof. (Poland)
Gómez Cuevas Alina, Prof. MD (Nicaragua)
Grattan Clive (United Kingdom)
Grivcheva-Panovska Vesna, Prof. (Macedonia)
Guzmán Antonio, MD (Paraguay)
Hashimoto Takashi, Prof. (Japan)
Hassan Iffat, Prof. (India)
Hegyí Vladimir, Prof. (Slovakia)
Hidalgo-Matlock Benjamin, MD (Costa Rica)
Hysi Katerina, MD (Albania)
Janjua Shahbaz, MD (Pakistan)
Jeseňák Miloš, Ass. Prof. (Slovakia)
Jeewon Rajesh, Ph.D. (Mauritius)
Jordán Rodríguez Ramiro, Prof. (Bolivia)
Julian Rolando, Prof. (El Salvador)
Kaszuba Andrzej, Prof. (Poland)
Kaštelan Marija, Prof. (Croatia)
Katsambas Andreas, Prof. (Greece)
Khawaja Shakeel Ahmed, PhD (Eritrea)
Kibbi Abdul-Ghani, Prof. (Lebanon)
Kossi Metowogo, Ph.D (Togo)
Kuiate Jules-Roger, Prof. (Cameroon)
Lan Cheng-Che E., Ass. Prof. (Taiwan)
Lopez-Granja Jorge, MD (Belize)
Lotti Torello, Prof. (Italy)
Mahassadi Alassan Kouamé, Ass. Prof. (Côte d'Ivoire)
Mahdi Juma Husain Ali, MD (Bahrain)
Maibach Howard I., Prof (USA)
Maio Paula, MD (Portugal)
Mekokishvili Lali, Prof. (Georgia)
Mikkelsen Carsten Sauer, MD (Denmark)
Mourad Mokni, Prof. (Tunisia)
Mota Luiz Alberto Alves, Prof. (Brazil)
Mrisho Fatma, MD (Tanzania)
Muvunyi Claude Mambo, MD (Rwanda)
Ndugwa Christopher, Prof. (Uganda)
Nedelciuc Boris, Ass. Prof. (Moldova)
Nhlengethwa Winnie, Prof. (Swaziland)
Nigam Pramod Kumar, Prof. (India)
Nikolic Milos, Prof. (Serbia)
Nowicki Roman, Prof. (Poland)
Nwabudike Lawrence Chukwudi, MD Ph.D (Romania)
Odeh Samuel, Prof. (Gabon)
Olszański Romuald, Prof. (Poland)
Oranje Arnold, Prof. (Netherlands)
Parajuli Sudip, MD (Nepal)
Parvin Rukhsana, MD (Bangladesh)
du Plessis Jeanetta, Prof. (South Africa)
Puri Neerja, MD (India)
Pusahai-Riman Paula, BSc, MS (Papua New Guinea)

Editorial Board

Qurashi Mohd, MD (Sudan)
Riedl Elisabeth, Ass. Prof. (Austria)
Ríos Yuil José Manuel, Prof. (Panama)
Ranotsi Amelia, PhD (Lesotho)
Rubio-Teixeira Marta Ph.D. (Belgium)
Rusnak Martin, Prof. (Slovakia)
Sayad Ibrahim, Prof. (Kuwait)
Sharquie Khalifa E., Prof. (Iraq)
Shawa Mary, MD (Malawi)
Shkilna Mariia, MD Ph.D (Ukraine)
Sinclair Rodney Daniel, Prof. (Australia)
Singh Harjeet, MD (Qatar)
Slavic Vjerolva, MD PhD (Montenegro)
Srinivasan Sundaramoorthy, Prof. (India)
Sumathipala Gayan Saranga, MD (Sri Lanka)
Tapia Felix J., Ass. Prof. (Venezuela)

Tatu Alin, MD (Romania)
Teixeira Roni Leonardo, MD (Brazil)
Tincopa-Wong Oscar Wilfredo, MD (Peru)
Tresh Amani, MD (Libya)
Tylewska-Wierzbanowska Stanisława, Prof. (Poland)
Uraga Pazmiño Enrique, MD (Ecuador)
Usha Rani Anaparthi, Prof. (India)
Valdebran Manuel, MD (Dominican Republic)
Vok Marko, MD (Slovenia)
Win Oo Soe, MD (Myanmar)
Wollina Uwe, Prof. (Germany)
Wortsman Ximena, Ass. Prof. (Chile)
Yamamoto Toshiyuki, Prof. (Japan)
Yuil de Ríos Emma, MD (Panama)
Zabielski Stanisław, Prof. (Poland)
Zawar Vijay, Prof (India)

Contents

ORIGINAL ARTICLES

- Standardization of modified Limberg flap technique by using an acetate template for the treatment of pilonidal disease 112
Mehmet Eren Yuksel
- Controlled trial comparing the efficacy of 88% phenol versus 100% trichloroacetic acid for chemical matricectomy in the management of ingrown toenail 116
Kaoutar Moustaid, Niema Aqil, Salim Gallouj, Fatima Zohra Mernissi
- Skin prick test for the evaluation of patients with idiopathic generalized pruritus: preliminary results 121
Funda Tamer, Mehmet Eren Yuksel
- Lichen planus pigmentosus and association with autoimmune diseases: A case-control study 125
Monia Youssef, Ines Lahouel, Mouna Korbi, Yosra Soua, Hela Marmouch, Hayet Akkari, Meriem Mohamed, Hichem Belhajali, Asma Belghith, Jameleddine Zili
- Immunoglobulin levels in maternal blood, cord blood and breast milk of Nigerian pregnant women using hydroquinone and non-hydroquinone containing skin lightening creams 131
Agatha Obiageli Nwosu, Arinola Olatunbosun Ganiyu

BRIEF REPORTS

- Perception of Dermatology by Medical Students in the Faculty of Health Sciences, University of Lomé (Togo) 138
Julienne Noudé Teclessou, Bayaki Saka, Séfaco Aba Akakpo, Abas Mouhari-Toure, Kassang Panawè, Koussake Kombate, Palokinam Pitche
- Topical corticosteroid abuse – a prospective clinico-epidemiological study 142
Mrinal Gupta

CASE REPORTS

- Case series: Three cases of dermatitis artefacta 145
Gangadhar Harsha, Jithin Bijina, Anjan Kumar Patra
- Persistent pemphigus vulgaris and pemphigus foliaceus showing features of tufted hair folliculitis just on the scalp 148
Maral Nouriyani, Fatemeh Montazer, Fatemeh Rouzbeh, Ramina Mofarrah, Ramin Mofarrah
- Diffuse primary B-cell lymphoma of large B-cell, leg- type. A case report 151
Beatriz Di Martino Ortiz, Rosalba Riveros, Lourdes Rodriguez, Silvia Aguilar, Mirtha Rodriguez, Oilda Knopfmacher, Lourdes Bolla
- Acquired vulvar lymphangioma circumscriptum: A report of 3 cases 156
Siham Mansouri, Sara Mai, Nadia Ismaili, Laila Benzekri, Badr Hassam
- Metastatic spindle cell melanoma on cytology – a diagnostic challenge 159
Archana Shivamurthy, Ranjini Kudva, Annappa Kudva, Padmapriya Jaiprakash
- Vulvar bowen disease treated successfully by Photodynamic therapy: about two cases 163
Hanane Bay Bay, Selma Benkirane, Loubna Benchat, Sara Elloudi, Mariame Meziane, Fatima Zahra Mernissi
- Squamous cell carcinoma developing in an epidermal inclusion cyst 166
Hubert Daisley Jr, Arlene Rampersad, Oneka Acco, Edmond Ramirez, Dinelle Sirjuesingh

Contents

Unusually localised cutaneous multifocal squamous cell carcinoma	170
<i>Radhika Varma, N. Asokan, A. Sarin, Nadiya Rahman</i>	
A case report of Baboon Syndrome due to azithromycin.....	173
<i>Munise Daye, Koray Durmaz, Pembe Oltulu</i>	
Generalized hyperpigmentation after pyrimethamine use	176
<i>Ann Sterkens, Vasiliki Siozopoulou, Evelyne Mangodt, Julien Lambert, An Bervoets</i>	
Dyschromatosis universalis hereditaria: A rare case report from Northeast India.....	179
<i>Romita Bachaspatimayum, Priyanka Das, Nandita Bhattacharjee</i>	
Facial granulomatous periorificial dermatitis in a Tunisian child	181
<i>Anissa Zaouak, Leila Bouhajja, Selima Ben Jannet, Olfa Khayat, Houda Hammami, Samy Fenniche</i>	
Simultaneous occurrence of papulonecrotic tuberculid and extra pulmonary tuberculosis (cervical lymphadenopathy) in an adult man. A Case report	184
<i>Th Bijayanti Devi, Angila Dorjee</i>	
Striking papular dermatosis in a patient with Down syndrome.....	187
<i>Lucía González-Ruiz, Monserrat Franco-Muñoz, María Rogel-Vence, Violeta Herrera-Montoro</i>	
REVIEW ARTICLE	
Pruritic papular eruption of HIV: a review article.....	191
<i>Obioma Ekpe, Gerald Dafe Forae, Chibuzor Ifeanyi Okpala</i>	
CLINICAL IMAGES	
Epidermal cysts of scrotum.....	197
<i>Ouiame El Jouari, Anas Zaougui, Ghita Senhaji, Salim Gallouj, Moulay Hassan Farih, Fatima Zahra Mernissi</i>	
Lichen planus arising through the Koebner phenomenon in areas of Hijama	198
<i>Nabeel K. Al Hamzawi</i>	
A case of widespread non-pigmented hair regrowth in diffuse alopecia areata	200
<i>Younes Barbach, Hanane Baybay, Mohammed Chaouche, Sara Elloudi, Fatima Zahra Mernissi</i>	
LETTER TO THE EDITORS	
Comment to: Erythroderma due to iatrogenic immunosuppression: A case of Norwegian scabies	202
<i>Hubert Daisley Jr., Arlene Rampersad, Oneka Acco</i>	
A rare coexistence of alopecia areata and lichen planus	204
<i>Funda Tamer, Haldun Umudum</i>	
Bilateral eyelid swelling: Floppy eyelid syndrome with obstructive sleep apnea	206
<i>Mika Yamanaka-Takaichi, Hidenori Mito, Nao Kusutani, Daisuke Tsuruta</i>	
Cutaneous squamous cell carcinoma arising from the hair follicle.....	208
<i>Vladimír Bartoš</i>	
Basal cell carcinoma of the leg: an unusual location	211
<i>Anissa Zaouak, Leila Bouhajja, Faten Rebhi, Raja Jouini, Houda Hammami, Samy Fenniche</i>	
Pigmented fungiform papillae of the tongue: clinical and dermoscopic features.....	213
<i>Niema Aqil, Mounia Bennani, Aicha Nassiri, Mariame Meziane, Salim Gallouj, Fatima Zahra Mernissi</i>	

Contents

Pigmented fungiform papillae of the tongue: Moroccan case..... 215
Ouiam El Anzi, Safae Maouni, Ilham Mekkassi, Badredine Hassam

Cutaneous siderosis after extravasation of intravenous iron infusion 217
Mrinal Gupta

HISTORICAL ARTICLES

Dermatology Eponyms – sign –Lexicon (T). Part 1..... 219
Piotr Brzeziński, Yasmeeen Jabeen Bhat, Ouiame El Jouari, Rakesh Bharti, Patricia Chang, Anca Chiriac, Lorenzo Martini, Ashwin Devasya

Dermatology Eponyms – sign –Lexicon (T). Part 2..... 224
Piotr Brzeziński, Lorenzo Martini, Beatriz María Di Martino Ortiz, Vijaya Sajjan, Masashi Narita, Yuko Ono, Ramesh Parajuli, Biswajit Dey, Guilherme Moraes Krüger, Patrice Bourée

Standardization of modified Limberg flap technique by using an acetate template for the treatment of pilonidal disease

Mehmet Eren Yuksel

Aksaray University School of Medicine, Department of General Surgery, Aksaray, Turkey

Corresponding author: Dr. Mehmet Eren Yuksel, E-mail: doctormehmeteren@yahoo.com

ABSTRACT

Background: Pilonidal disease is a common condition that usually affects young men. The disease presents with pain, cysts, abscesses, pits, sinus tracts, retained hairs and draining in the sacrococcygeal area. Various surgical techniques have been described in the treatment of pilonidal disease. Modified Limberg flap is a commonly used procedure, however, studies which compared the outcomes of modified Limberg flap technique have reported different results. Diverse geometric rhomboid excisions in shape and size, and varied lateralization distance can lead to differences in healing time, complication and recurrence rates. Standardization of the modified Limberg flap technique can help to compare the end results of the surgical intervention more accurately. Therefore, we developed an acetate template to draw a sketch map of Limberg/modified Limberg flap preoperatively, in order to standardize the procedure. **Materials and Methods:** A Limberg/modified Limberg flap template was prepared by using an online drawing program. Rhomboid flaps with four different sizes were drawn. The template was printed onto an acetate sheet. With the help of a sewing needle, pin holes were performed on the acetate template. The borders of the rhomboid excision and the Limberg/modified Limberg flap were defined with the acetate template and drawn on the gluteal region by using a water resistant multi-purpose pen. The surgeon decided which rhomboid flap size to choose according to the dispersion of the pilonidal sinus openings. All pilonidal pits and abscess orifices stayed within the resected area. The size of modified Limberg flap was standardized by the help of the acetate template. **Results:** This study included 10 male patients with pilonidal disease between the ages of 20 to 35. The mean disease duration of the patients was 4.2 years. All the patients underwent modified Limberg flap surgery using an acetate template. The follow-up period was three months. We observed surgical site infection only in one patient within seven days, postoperatively. **Conclusions:** We suggest that using a standardized template while performing a modified Limberg flap procedure for the treatment of pilonidal disease may help to evaluate and compare the outcomes of this surgical procedure more accurately.

Key words: Flap; Limberg; Modified Limberg; Pilonidal disease; Pilonidal sinus; Surgery

INTRODUCTION

Pilonidal disease is a common condition among young adults. The exact cause remains controversial. However, obstruction of hair follicles in the natal cleft has been implicated in the etiology of pilonidal disease. It is more common in men than in women. Pilonidal disease usually starts in patients under the age of 30. The risk factors in the development of pilonidal disease include male gender, obesity, sitting for long periods, chronic

trauma to the sacrococcygeal area, excess body hair and poor hygiene [1].

Pilonidal disease clinically presents with cyst, abscess with retained hair, pits, sinus tracts with or without draining in the gluteal cleft [2,3]. Acute pilonidal abscess leads to erythema, edema, tenderness and pain while chronic pilonidal abscess is characterized by chronic pilonidal sinus cavity with recurrent drainage as a result of retained hair and infected residue [3].

How to cite this article: Yuksel ME. Standardization of modified Limberg flap technique by using an acetate template for the treatment of pilonidal disease. Our Dermatol Online. 2019;10(2):112-115.

Submission: 12.11.2018; **Acceptance:** 30.01.2019

DOI: 10.7241/ourd.20192.1

The diagnosis of pilonidal disease is made based on typical clinical findings like inflammation adjacent to the gluteal cleft with associated midline pits [4]. Acute pilonidal abscess is treated with incision and drainage. Antibiotic use is not recommended except for the immunosuppressed or toxic appearing patients, and patients who have risk for endocarditis or methicillin-resistant *Staphylococcus aureus* infection [4].

Some pilonidal abscesses have been associated with a malignant change, which is called Marjolin's ulcer [5]. Therefore, a biopsy should be performed in patients who do not respond to conservative management to rule out squamous cell carcinoma [4].

A definitive treatment should be performed following the regression of acute inflammation. Treatment options include excision and laying open/primary closure, minimally invasive procedures like crystallized phenol treatment, pit picking surgery and endoscopic sinus treatment, off-midline procedures like Limberg flap and Karydakias flap, advancement flaps like Karydakias procedure, Z flap and V-Y flap [6,7]. However, none of these procedures has been considered as the gold standard [7].

Modified Limberg flap procedure is a safe and effective technique in the treatment of pilonidal disease with low complication and recurrence rates [8]. However, there is no standardized rhomboid shape and excision style between general surgeons while performing modified Limberg flap surgery (Fig. 1). Hereby, a modified Limberg flap technique performed by using a template has been described.

MATERIALS AND METHODS

With the help of an online drawing program (<https://www.draw.io/>), a sketch was prepared. Rhomboid flaps with four different sizes were drawn (Fig. 2). Each rhomboid was a parallelogram with all equal sides. Inner angles of the rhomboid were 60° and 120°. In order to apply modified Limberg flap technique, shifting of the midline/intergluteal sulcus to the left was also drawn. The template was printed onto an acetate sheet (Canon Pixma, MG 2550). With the help of a sewing needle, pin holes were performed on the acetate sheet template (Figs. 3a – 3c). A water resistant multi-purpose pen (edding 149M, Japan) was applied onto the pin holes on the acetate template. Finally, the borders of the rhomboid excision and the Limberg/modified

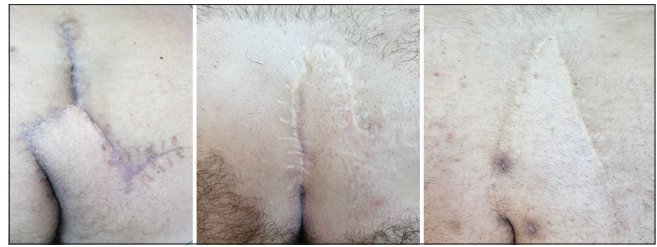

Figure 1: Patients who underwent transposition flap surgery for the treatment of pilonidal sinus disease: All surgical operations above were claimed to be done with modified Limberg flap technique. However, the shape and the size of the raised flaps were different postoperatively. The comparison of the end-results of these patients give different outcomes, even if they are operated with the same surgical technique. Therefore, the surgical technique should be standardized in order to be able to compare the end-results more efficiently.

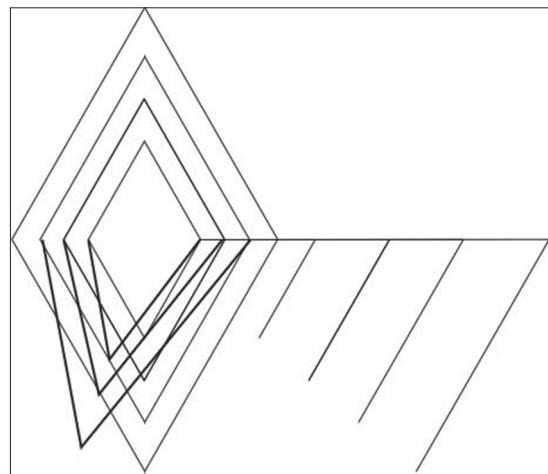


Figure 2: Both Limberg and modified Limberg flap templates with four different rhomboid flap sizes were drawn by using an online drawing program (<https://www.draw.io/>). Each side of the rhomboids are 2.5, 3.5, 4.5, 5.5 cm, respectively. The rhomboid part of the template defines the resection area. The line stretching to the right, with arms dangling to the left, helps to define the borders of the flap which is intended to be raised. All sides of the rhomboid and the flap should be equal. The surgeon decides which rhomboid flap size to choose according to the dispersion of the pilonidal sinus openings. All pilonidal pits and abscess orifices should stay within the resected area. The size of Limberg flaps are standardized by the help of the acetate template.

Limberg flap were defined and drawn onto the gluteal region by using the acetate template.

RESULTS

This study included 10 male patients with pilonidal disease at the age of 20 to 35. The mean disease duration of the patients was 4.2 years. Two patients were treated with crystallized phenol technique previously, however, the symptoms recurred within 12 months. Eight patients did not receive any prior treatment except for non-steroidal anti-inflammatory

drugs to relieve pain. The past medical history and family history were both unremarkable. All the patients underwent surgery using the technique described above (Figs. 4a – 4c). No complications have been observed intraoperatively. The patients were discharged on postoperative day one. The follow-up period was three months. The surgical site infection was observed in a patient within seven days, postoperatively. The patient was treated with oral administration of ciprofloxacin 500 mg and metronidazole 500 mg twice daily for one week without any adverse effect.

DISCUSSION

Pilonidal disease can be treated with various surgical methods, however, risk of recurrence remains high [9]. Recurrence rate of 20-40% has been reported regardless of the surgical technique [10]. Flap techniques provide a flattened intergluteal sulcus, tension-free repair, less hairy tissue and reduced sweating [9]. The classic Limberg flap consists of symmetrical rhomboid shaped excision in which the apices are placed on the midline. Recurrence can be observed in the excision site at the lower midline apex of the rhomboid flap following the classic Limberg flap. Therefore, the classic Limberg flap




Figure 3: The template was printed onto an acetate sheet. a. The acetate sheet template was placed on the gluteal region. Rhomboid flaps with four different sizes were drawn on the acetate template for both Limberg and modified Limberg flap technique. b. Pin holes were created on the acetate with the help of a sewing needle. c. A water resistant multi-purpose pen was applied along the pin holes to draw the borders of rhomboid excision and Limberg/modified Limberg flap.

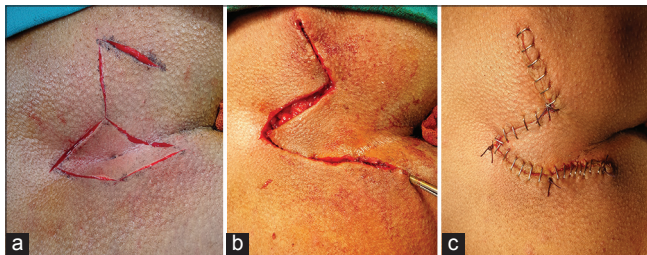


Figure 4: a. The borders of the modified Limberg flap was drawn on the gluteal region by using the standardized modified Limberg flap template. b. The tip of the pincette shows the lateralization of the midline/intergluteal sulcus to the left, which gives the technique its name "modified". c. The postoperative view of the standardized modified Limberg flap operation.

was modified in 2004 to prevent this complication. The rhomboid-shaped excision is made asymmetrically to move away the apex of the flap 1 to 2 cm lateral side to the inferior midline [11].

Modified Limberg flap is one of the most commonly used procedure with satisfactory outcomes, short healing time and good long-term results [12,13]. However, modified Limberg flap can lead to disfigurement in the sacrococcygeal area as a result of creating a geometric shaped flap. The procedure may not be appropriate for patients with extensive pilonidal disease which requires larger flaps [12]. Modified Limberg flap closure has been compared with other surgical techniques which are used in the treatment of pilonidal disease. Shabbir et al. reported that modified Limberg flap closure has less infection and recurrence rates, short hospital stay and better patient comfort when compared with excision and direct primary closure [13]. Khan et al. compared early outcome of modified Limberg and Karydakis flap procedures. Khan et al. reported significantly less wound infection and seroma formation in patients treated with modified Limberg procedure [14]. Sit et al. compared the Karydakis, modified Limberg and Limberg flap techniques in the treatment of pilonidal disease. Modified Limberg had significantly low maceration, recurrence, and hypoesthesia rates. Mean off-work period, time to walk without pain, and period to take the drainage off were shorter in modified Limberg compared to Karydakis and Limberg flap techniques [15].

However, Tokac et al. reported no significant difference in patient comfort and recurrence risk between modified Limberg flap and Karydakis flap surgeries. Patients treated with modified Limberg flap had shorter healing time, while better cosmetic results have been achieved in Karydakis flap procedure [16]. Can et al. compared modified Limberg flap and Karydakis flap procedures in the treatment of pilonidal disease. Complication and recurrence rates were similar in both techniques. Patients underwent Karydakis flap reported shorter healing time postoperatively [17]. Abdelnaby et al. compared the outcomes of modified Limberg flap and rotational gluteal flap. Both modified Limberg flap and rotational gluteal flap have low recurrence rates, however, rotational gluteal flap had shorter healing time, lower complication rate and better cosmetic appearance [12]. Studies that compared surgical techniques especially modified Limberg flap and Karydakis flap in the treatment of pilonidal disease had different results. Differences in

shape and size of a geometric rhomboid excision and different lateralization distance can lead to controversy in healing time, complications rates and recurrence rates in comparing modified Limberg flap procedure to other techniques.

CONCLUSION

In conclusion, we have developed an acetate template to draw a sketch map of Limberg/modified Limberg flap preoperatively, in order to standardize the procedure. Using a standardized template while performing a modified Limberg flap surgery may help to evaluate the outcomes of this technique more accurately.

REFERENCES

1. Segre D, Pozzo M, Perinotti R, Roche B. Italian Society of Colorectal Surgery. The treatment of pilonidal disease: Guidelines of the Italian Society of Colorectal Surgery (SICCR). *Tech Coloproctol*. 2015;19:607-13.
2. Srihari RS, Naveen AM, Sreekar H. The Limberg flap reconstruction - the optimal surgery for pilonidal sinus disease. *Our Dermatol Online*. 2016;7:271-5.
3. Khanna A, Rombeau JL. Pilonidal disease. *Clin Colon Rectal Surg*. 2011;24:46-53.
4. Kuckelman JP. Pilonidal disease: Management and definitive treatment. *Dis Colon Rectum*. 2018;61:775-7.
5. Brzezinski P, Solovan C, Chiriac A. Malignant degeneration of scars in elderly people (Marjolin's ulcers). *Int Wound J*. 2016;13:1047-8.
6. Iesalnieks I, Ommer A, Petersen S, Doll D, Herold A. German national guideline on the management of pilonidal disease. *Langenbecks Arch Surg*. 2016;401:599-609.
7. Boshnaq M, Phan YC, Martini I, Harilingam M, Akhtar M, Tsavellas G. Limberg flap in management of pilonidal sinus disease: Systematic review and a local experience. *Acta Chir Belg*. 2018;118:78-84.
8. Hussain SM, Farees SN, Abbas SJ, Vakati Raghavendra SK. Rhomboid excision with modified Limberg flap in the treatment of sacrococcygeal pilonidal disease. *Arch Int Surg*. 2015;5:74-7.
9. Singh PK, Gohil RK, Saxena N. Limberg flap procedure for sacrococcygeal pilonidal sinus: A prospective study. *Int Surg J*. 2017;4:2238-42.
10. Aithal SK, Rajan CS, Reddy N. Limberg flap for sacrococcygeal pilonidal sinus a safe and sound procedure. *Indian J Surg*. 2013;75:298-301.
11. Bessa SS. Comparison of short-term results between the modified Karydakis flap and the modified Limberg flap in the management of pilonidal sinus disease: A randomized controlled study. *Dis Colon Rectum*. 2013;56:491-8.
12. Abdelnaby M, Emile SH, El-Said M, AbdelMawla A, Elgendy H, Sakr A, et al. Rotational gluteal flap versus modified Limberg flap in treatment of sacrococcygeal pilonidal disease. *J Surg Res*. 2018;223:174-82.
13. Shabbir F, Ayyaz M, Farooka MW, Toor AA, Sarwar H, Malik AA. Modified Limberg's flap versus primary closure for treatment of pilonidal sinus disease: A comparative study. *J Pak Med Assoc*. 2014;64:1270-3.
14. Khan KJ, Ghaffar A, Choudhry S, Irshad K. Comparison of early outcome between modified Limberg and Karydakis flap procedures in patients with sacrococcygeal pilonidal sinus. *PJHMS*. 2016;10:631-4.
15. Sit M, Aktas G, Yilmaz EE. Comparison of the three surgical flap techniques in pilonidal sinus surgery. *Am Surg*. 2013;79:1263-8.
16. Tokac M, Dumlu EG, Aydin MS, Yalcin A, Kilic M. Comparison of modified Limberg flap and Karydakis flap operations in pilonidal sinus surgery: Prospective randomized study. *Int Surg*. 2015;100:870-7.
17. Can MF, Sevinc MM, Hancerliogullari O, Yilmaz M, Yagci G. Multicenter prospective randomized trial comparing modified Limberg flap transposition and Karydakis flap reconstruction in patients with sacrococcygeal pilonidal disease. *Am J Surg*. 2010;200:318-27.

Copyright by Mehmet Eren Yuksel. This is an open access article distributed under the terms of the Creative Commons Attribution License, which permits unrestricted use, distribution, and reproduction in any medium, provided the original author and source are credited.
Source of Support: Nil, Conflict of Interest: None declared.

Controlled trial comparing the efficacy of 88% phenol versus 100% trichloroacetic acid for chemical matricectomy in the management of ingrown toenail

Kaoutar Moustaide, Niema Aqil, Salim Gallouj, Fatima Zohra Mernissi

Department of Dermatology, University Hospital Hassan II, Rte Sidi Hrazem, Fes, Morocco

Corresponding author: Dr. Kaoutar Moustaide, E-mail: Moustaidek@gmail.com

ABSTRACT

Background: The ingrown toenail results from a painful conflict between the nail plate and the adjacent soft parts. **Material and methods:** We conducted a prospective, comparative trial of the long-term efficacy of two methods: phenolization (88%) and matricolysis by trichloroacetic acid (TCA) (100%). Adult, consenting patients with ingrown toenails were alternately allocated into two treatment, to receive either 88% phenol or 100% TCA chemical matricectomy. The patients as well as the statistician were blinded to the agent being used. Post-procedure follow-up evaluated median duration of pain, discharge, and healing along with recurrence, if any, in both the groups. The group wise data was statistically analyzed. **Results:** On comparing the two groups, pain lasted 9.34 days in the TCA group and 18.62 days in the phenol group, this difference was not statistically significant ($P = 0.202$). The tissue condition took 9.30 days to normalize in the the TCA group, while it took 17.63 days to normalize in the phenol group. This difference was found to be statistically significant ($P < 0.007$). The aesthetic result and the cost of the care were similar in the 2 groups. **Conclusion:** Chemical matricectomy using TCA is as efficacious as phenolisation, with the advantage of faster tissue normalization.

Key words: Ingrown; Matricectomy; Phenol; Toenail; TCA

INTRODUCTION

Ingrown toenail is a widespread affection and a frequent reason for consultation in dermatology. It leads to economic losses, affecting quality of life, sporting and work activities.

Most cases require surgical management in the form of lateral partial nail avulsion of the ingrowing edge. Several surgical and non-surgical methods have been described for treating ingrown nails. however, a simple avulsion is associated with high chances of recurrence [1].

Lateral matricectomy is essential to the management of ingrown toenail. Many methods can be used to destroy the lateral matrix, this may be achieved by surgical, or more commonly, a chemical destruction. Phenol and sodium hydroxide are commonly used agents but both

are frequently linked to excessive healing times [2,3]. Trichloroacetic acid (TCA) is an analogue of acetic acid. It is a well-known caustic agent extensively used in dermatology, mainly in cosmetic peelings. It causes coagulative necrosis of cells through wide protein denaturation and resultant structural cell death. It can be also used in the treatment of ingrown nail, with less postoperative drainage; however, long-term efficacy data are lacking [4].

We conducted a prospective, comparative trial of the long-term efficacy of chemical matricectomy using phenol and TCA; as well as to compare the healing times and postoperative morbidity associated with the two agents. To our knowledge, this is the first study comparing these two methods.

How to cite this article: Moustaide K, Aqil N, Gallouj S, Mernissi FZ. Controlled trial comparing the efficacy of 88% phenol versus 100% trichloroacetic acid for chemical matricectomy in the management of ingrown toenail. Our Dermatol Online. 2019;10(2):116-120.

Submission: 16.07.2018; **Acceptance:** 01.12.2018

DOI:10.7241/ourd.20192.2

METHODS

The trial protocol was approved by the Institutional Ethical Committee of the Hassan II University Hospital. Patients, aged between 18 and 60 years, presenting to our dermatology department with a clinical diagnosis of an ingrown toenail were included. Patients with significant peripheral arterial disease, known allergy to agents being used, severe systemic disease, or conditions associated with delayed wound healing (e.g., uncontrolled diabetes mellitus) were excluded from the study.

Informed, written consent of all participants was taken prior to enrolment.

Predisposing factors were evaluated at the first visit: excessive curvature of the nail plate, toe rotation, thin nails, heavy nail folds, hyperhidrosis, bad nail clipping and the regular use of constricting footwear. Suitable antibiotic therapy was used in cases of infection.

The affected toe and foot were evaluated at baseline for the stage and type of ingrown toenail and the condition of the nail structures using the following criteria: Stage 1 was defined as the presence of only mild erythema or edema, with pain on applying pressure, Stage 2 as significant erythema or edema with sero-purulent drainage from the affected nail fold and Stage 3 as significant drainage, formation of granulation and lateral wall hypertrophy [2]. At baseline, a potassium hydroxide (KOH) mount of the nail clipping was examined to rule out fungal infection for all patients with nail thickening, distal onycholysis, or subungual debris. Only mycologically negative cases were included in the study.

All included patients were asked to grade their pain on a visual analog scale (VAS) of 0 to 10 (0 being no pain and 10 being unbearable pain). The patients were then allocated alternately to the two treatment groups in the order in which they joined the study. Group 1 patients were treated with 88% phenol chemical matricectomy while Group 2 patients received 100% TCA application. The allocation was done by the nursing assistant not otherwise involved in the study. The corresponding solution (phenol or TCA) was provided to the operator.

The surgical procedure consisted of digital block to anesthetize the digit, exsanguination and tourniquet application to assist hemostasis followed by partial avulsion of the lateral nail plate to remove the full

length of the ingrown nail plate sliver. The lateral tunnel created was then curetted to remove any granulation tissue/crust if present.

Chemical matricectomy was then done with the appropriate agent (as per group allocation). It was provided by the operating assistant onto a cotton tipped applicator, which was vigorously rubbed onto the lateral horn of the nail matrix. The application time used for both the agents was 2 min. Care was taken to prevent contact with surrounding structures as this could cause more extensive damage than intended and delay wound healing. Following this, the excess solution was neutralized.

The operated toe was then dressed with a paraffin gauze and bandage. Patients were instructed to rest the foot for the rest of the day and keep it in an elevated position. Analgesics were advised to be taken only when required and patients were asked to record their use. Dressings with topical antibiotics were used in all patients.

After their operations, all patients were examined at the 72-hour mark to evaluate drainage or potential complications of the surgical technique (such as hemorrhage, infection, pain or necrosis). At that point, patients measured pre-operative and post-operative (24 and 72 hours) pain using a visual analogic scale (from 1 to 10). Patients were then examined on day 30 (1 month), day 180 (6 months), day 270 (9 months) and day 360 (1 year), after surgery. During each visit, the wounded area was checked and any complication or sign of recurrence was noted. Bacterial cultures from the nail bed were taken in case of clinical suspicion of infection, if present, was appropriately treated.

A photographic record of each visit was maintained.

RESULTS

The study flow is outlined in (Fig. 1). SPSS version 20.0 was used to analyze the data.

A total of 120 patients were included in the study protocol (Fig. 1).

From the potential contributing factors for the disease that were assessed, we found that 55% had an excessive trimming of the lateral nail plate, 38% suffered from plantar hyperhidrosis, and 35% showed heavy lateral nail folds., 29% regularly used constricting footwear, 25%

had thin nails, 17% an excessive curvature of the nail plate and 09% a rotation of the toe (Table 1).

A baseline assessment of the two treatment groups is shown in (Table 1). It can be seen that both the groups were comparable with respect to their demographic characteristics and disease severity.

The intended outcome measures for the two groups are compared in (Table 2). On comparing the two groups, pain lasted 9.34 days in the TCA group and 18.62 days in the phenol group, this difference was not statistically significant ($P = 0.202$). The tissue condition took 9.30 days to normalize in the the TCA group, while it took 17.63 days to normalize in the phenol group. This difference was found to be statistically significant ($P < 0.007$).

Treatment was successful in all the treated patients of both the groups with resolution of all symptoms caused by the ingrown nails as noted in serial clinical photographs of the patients from both groups. Four patients

each in both groups were found to have secondary infection with bacteriological cultures showing *Staphylococcus aureus*. All the eight patients responded to standard courses of anti-staphylococcal antibiotics.

However, the rate of redicive was not related to the agent of matricolysis but was associated with the way of cutting the nails. No other side effects were recorded in any of the treatment groups.

And finally, the aesthetic result and the cost of the care were similar in the 2 groups.

DISCUSSION

Ingrown toenail is one of the most common painful nail conditions presenting to a dermatologist. It is a result of the lateral edge of the nail plate getting embedded in the nail fold (where it acts as a foreign body) resulting in a cascade of inflammation, infection and the reparative process [2,5].

The condition most commonly involves the great toes and mainly affects young adults [6], as was seen in our study, where the average age was 27 and 25.9 years in both the groups. This may be related to increased chances of sustaining minor trauma to the feet owing to an active lifestyle. Rarely, elderly individuals or infants may be affected. There is no consensus on the choice of treatment for ingrown toenails.

Surgical management is the mainstay of treatment as conservative methods have a low rate of success in the long run [1].The standard surgical approach for the management of an ingrown toenail is avulsion of the nail plate with destruction of the underlying matrix [5,6]. The matrix destruction should be selective to minimize damage to the surrounding normal structures, but at the same time it must be complete and reliable to prevent recurrences [7].

Selective matricectomy can be performed using surgical or chemical methods. Chemical matricectomy uses various chemical agents to destroy the lateral nail matrix.

Among these, phenol is the most common agent used in most clinics. It is an effective protein denaturant which shows its cauterizing effect by producing a coagulation necrosis in the matrix and the surrounding soft tissue [8,10]. It has been widely studied and is reported to be more effective at preventing symptomatic recurrences (recurrence rates ranging

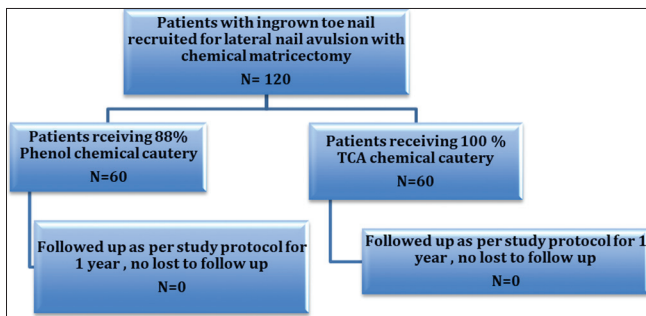


Figure 1: The study protocol.

Table 1: Baseline assessment of both treatment groups

Baseline characteristic	Group 0 : TCA	Group 1 : Phenol
Total number of patients(N)	60	60
Sexe ratio : Male / Female	39/21	37/23
Mean age (in years)	27	25,9
Severity of ingrown toenail		
Stage 1	08	08
Stage 2	19	17
Stage 3	33	35
Mean duration of complaints (in months)	5,2	9,3

Table 2 : Predisposing factors gor the ingrown nail

Excessive trimming of the lateral nail plate	55%
Plantar hyperhidrosis	38%
Heavy lateral nail folds	35%
Use of constricting foot wear	29%
Thin nails	25%
Excessive curvature of the nail plate	17%
Rotation of the toe	09%

from 1% to 9.6%) as compared to nail avulsion alone (42-83%) [1,11]. However, due to the prolonged healing time of necrosed tissue, it carries an increased risk of postoperative infection [1]. The post-operative discharge generally lasts for about 2-4 weeks but may continue for up to 6 weeks [2]. In addition, phenol is contraindicated in those with moderate or severe vascular disease of the foot, conditions predisposing to delayed wound healing, allergy to the chemical and in pregnancy [12,13].

In recent years, matricectomy with sodium hydroxide has been found to be as effective as phenol matricectomy, with shorter healing periods and a lower risk of local or systemic toxicity [3,14-16]. Sodium hydroxide causes less burns and liquefaction necrosis, resulting in less postoperative drainage and faster healing. However prolonged application of can cause excessive damage due to slowly progressing liquefaction necrosis [17].

Trichloroacetic acid is one of the most commonly used agents for chemical peeling. Depending on the concentration, it achieves superficial to medium depth chemical peeling. It is a caustic chemical agent that causes coagulation necrosis, like phenol. It produces both epidermal and dermal necrosis and then neutralizes by itself without serious systemic toxicity. In a recent study, Kim et al. performed chemical matricectomy with 100% TCA in 25 patients with ingrowing toenail edges, and reported that the success rate was 95%. They reported that adverse effects such as postoperative pain, drainage and infection were mild; postoperative drainage generally decreased within one week and did not last more than two weeks [15].

Other methods used are surgical matricectomy and ablative methods such as carbon dioxide laser [15,17], electrocautery and radiofrequency [18-20]. The latter techniques are more technically demanding and more expensive compared with chemical matricectomy, and hence not used as commonly.

Previous studies have compared sodium hydroxide and phenol but had differing results [2,14]. However we didn't find any study comparing TCA to Phenol. Our study shows that: the two techniques studied allow good results in terms of recidivism and aesthetic result. On the other hand one can obtain a faster cicatrization and avoid the patients the postoperative oozing by using the TCA.

CONCLUSION

The TCA method is also fast, easy to perform, and with less postoperative oozing with faster healing. The destruction by TCA is therefore considered as a technique of choice and allows good aesthetic results with a low recurrence rate as evidenced by our study. To our knowledge, this is the first study comparing these two methods, and other studies are needed to confirm our results and to adopt this technique of matricolysis.

Statement of Human and Animal Rights

All procedures followed were in accordance with the ethical standards of the responsible committee on human experimentation (institutional and national) and with the Helsinki Declaration of 1975, as revised in 2008.

Statement of Informed Consent

Informed consent was obtained from all patients for being included in the study.

REFERENCES

1. Camurcu Y, Sofu H, Issin A, Kockara N, Saygili H. Operative treatment of the ingrown toenail with a less-invasive technique: flashback to the original winograd technique. *foot ankle spec.* 2018;11:138-41.
2. Tatlican S, Eren C, Yamangokturk B, Eskioglu F. Letter: Retrospective comparison of experiences with phenol and sodium hydroxide in the treatment of ingrown nail. *Dermatol Surg.* 2010;36:432-4.
3. Zaraq I, Dorbani I, Hawilo A, Mokni M, Ben Osman A. Segmental phenolization for the treatment of ingrown toenails: technique report, follow up of 146 patients, and review of the literature. *Dermatol Online J.* 2013;19:18560.
4. Terzi E, Guvenc U, Türsen B, Kaya Tİ, Erdem T, Türsen Ü. The effectiveness of matrix cauterization with trichloroacetic acid in the treatment of ingrown toenails. *Indian Dermatol Online J.* 2015;6:4-8.
5. Bostanci S, Kocuyigit P, Parlak N, Gungor HK. Chemical matricectomy with sodium hydroxide: long-term follow-up results. *Dermatol Surg.* 2014;40:1221-4.
6. Tatlican S, Yamangokturk B, Eren C, Eskioglu F, Adiyaman S. Comparison of phenol applications of different durations for the cauterization of the germinal matrix: An efficacy and safety study. *Acta Orthop Traumatol Turc.* 2009;43:298-302.
7. Eekhof JA, Van Wijk B, Knuistingh Neven A, van der Wouden JC. Interventions for ingrowing toenails. *Cochrane Database Syst Rev.* 2012;4:CD001541.
8. Vural S, Bostanci S, Kocuyigit P, Çaliskan D, Baskal N, Aydin N. Risk Factors and Frequency of Ingrown Nails in Adult Diabetic Patients. *J Foot Ankle Surg.* 2018;57:289-95.
9. Jia C, Li P, Wu Y, Qiu Y, Cao L, Chang C, et al. Modified surgical repair of severe ingrown toenail. *Zhongguo Xiu Fu Chong Jian Wai Ke Za Zhi.* 2013;27:869-71.
10. Karaca N, Dereli T. Treatment of ingrown toenail with proximolateral matrix partial excision and matrix phenolization. *Ann Fam Med.* 2012;10:556-9.
11. Vaccari S, Dika E, Balestri R, Rech G, Piraccini BM, Fanti PA.

- Partial excision of matrix and phenolic ablation for the treatment of ingrowing toenail: a 36-month follow-up of 197 treated patients. *Dermatol Surg.* 2010;36:1288-93.
12. Di Chiacchio N, Di Chiacchio NG. Best way to treat an ingrown toenail. *Dermatol Clin.* 2015;33:277-82.
 13. Chiacchio ND, Belda W Jr, Chiacchio NG, Kezam Gabriel FV, de Farias DC. Nail matrix phenolization for treatment of ingrowing nail: Technique report and recurrence rate of 267 surgeries. *Dermatol Surg.* 2010;36:534-7.
 14. Richert B. Surgical management of ingrown toenails - an update overdue. *Dermatol Ther.* 2012;25:498-509.
 15. Becerro de Bengoa Vallejo R, Cordoba Diaz D, Cordoba Diaz M, Losa Iglesias ME. Alcohol irrigation after phenol chemical matricectomy: an *in vivo* study. *Eur J Dermatol.* 2013;23:319-23.
 16. Eekhof JA, Van Wijk B, Knuistingh Neven A, van der Wouden JC. Interventions for ingrowing toenails. *Cochrane Database Syst Rev.* 2012;(4):CD001541.
 17. Pérez-Rey J, Mediavilla-Saldaña L, Martínez-Nova A. Exploring postoperative outcomes for ingrown toenails. NaOH vs wedge resection techniques. *Dermatol Surg.* 2014;40:281-7.
 18. Becerro de Bengoa Vallejo R, Losa Iglesias ME, Viejo Tirado F, Serrano Pardo R. Cauterization of the germinal nail matrix using phenol applications of differing durations: A histologic study. *J Am Acad Dermatol.* 2012;67:706-11.
 19. Cocunubo-Blanco HA, González-Sixto B, Pérez-Paredes G, Rodríguez-Prieto MÁ. Partial nail matricectomy with carbon dioxide laser. *Actas Dermosifiliogr.* 2014;105:418-9.
 20. Heidelbaugh JJ, Lee H. Management of the ingrown toenail. *Am Fam Physician.* 2009;79:303-8.

Copyright by Kaoutar Moustaid, et al. This is an open-access article distributed under the terms of the Creative Commons Attribution License, which permits unrestricted use, distribution, and reproduction in any medium, provided the original author and source are credited.

Source of Support: Nil, Conflict of Interest: None declared.

Skin prick test for the evaluation of patients with idiopathic generalized pruritus: preliminary results

Funda Tamer¹, Mehmet Eren Yuksel²

¹Ufuk University School of Medicine, Department of Dermatology, Ankara, Turkey

²Aksaray University School of Medicine, Department of General Surgery, Aksaray, Turkey

Corresponding author: Dr. Funda Tamer, E-mail: fundatmr@yahoo.com

ABSTRACT

Background: Pruritus is an unpleasant sensation which can decrease the patient's quality of life by leading to anxiety and sleep disturbances. Pruritus can present due to various dermatological and systemic diseases like eczema, xerosis, diabetes mellitus, cholestasis and uremia. However, no etiologic factor can be detected in some patients. Idiopathic generalized pruritus is used to describe pruritus without any underlying dermatosis or systemic disorders. Skin prick test is used for the evaluation of patients with generalized pruritus to determine the causative agent. **Material and Methods:** The skin prick test results of the patients with idiopathic generalized pruritus who were admitted to dermatology outpatient clinic between April 2017 and May 2018 were reviewed retrospectively. **Results:** This study included 18 patients (12 female, 6 male) with idiopathic generalized pruritus. The mean age of the patients was 38.5. The mean disease duration was 3.4 years. Eleven (61.1%) patients had at least one positive reaction to skin prick testing. However, 7 (38.9%) patients did not react to any allergens. The most common allergies were to trees mixture and *Aspergillus* mix. **Conclusions:** Skin prick testing can be helpful in the management of patients with idiopathic generalized pruritus. Hereby, the most common allergens were detected as trees mixture and *Aspergillus* mix. However, a larger sample size is needed to characterize the most common allergens in Turkish patients with idiopathic generalized pruritus.

Key words: Allergy; Generalized; Idiopathic; Itching; Pruritus; Skin prick test

INTRODUCTION

Pruritus is the unpleasant sensation that leads to scratching and irritation of the skin [1]. Pruritus may be generalized or localized [2]. It is one of the most common subjective symptoms in dermatology. Pruritus lasting more than six weeks is called chronic pruritus. The prevalence of chronic pruritus in the general adult population has been reported 13.5%, recently [1]. It has been suggested that 60% of the elderly individuals aged 65 and over suffer from moderate or severe pruritus [1]. However, the prevalence of pruritus in elderly varies in studies. Goyal et. reported that pruritus was observed in only 5% of the patients aged 60 and above [3]. Pruritus can decrease the patient's quality of life by leading to anxiety, sleep disturbances, sexual dysfunction and attention problems [1].

Pruritus usually occurs as a result of dermatological conditions like xerosis and eczema [4]. However, various systemic disorders including diabetes mellitus, cholestasis, uremia, thyroid disorders, iron deficiency, polycythemia vera, essential thrombocytosis, malignancy, human immunodeficiency virus infection, hepatitis C infection and drug reactions may be the underlying cause of pruritus [2,4]. It has been suggested that a systemic etiology can be detected in 14% to 24% of patients complaining of generalized pruritus without any primary cutaneous cause [5].

Detailed medical history of patients with chronic pruritus is required to determine the etiology. Diagnostic assessment should include clinical characteristics of pruritus, presence of cutaneous lesions, previously diagnosed systemic and dermatological diseases, family

How to cite this article: Tamer F, Yuksel ME. Skin prick test for the evaluation of patients with idiopathic generalized pruritus: preliminary results. Our Dermatol Online. 2019;10(2):121-124.

Submission: 31.07.2018; **Acceptance:** 30.10.2018

DOI:10.7241/ourd.20192.3

history, medications, allergies, and susceptibility to atopic dermatitis [6]. Evaluation of laboratory tests including complete blood count, liver function tests like alkaline phosphatase, alanine aminotransferase and aspartate aminotransferase, blood urea nitrogen, serum creatinine, ferritin and thyroid-stimulating hormone levels is recommended in patients without any dermatological and physical findings [4,7]. However, in 8% of all patients complaining of pruritus, no underlying dermatosis or systemic disorder can be detected. This condition is termed as idiopathic generalized pruritus [7,8].

Hereby, we report the skin prick test results of the patients who had generalized pruritus without any underlying disorder or primary skin lesions.

MATERIALS AND METHODS

Medical reports of the patients with idiopathic generalized pruritus who were admitted to dermatology outpatient clinic between April 2017 and May 2018 were reviewed retrospectively. The exclusion criteria were pregnancy, malignancy, renal failure, use of systemic antihistamines, corticosteroids, tricyclic antidepressants, mast cell stabilizers and immunosuppressive drugs within four weeks.

The skin prick test was made on the flexural surfaces of the forearms (Figure 1). The test area was disinfected with 70% ethanol.

The skin prick test was performed using allergen extracts including *Betula verrucosa*, salicaceae, trees mixtures (locust, linden, horse chestnut

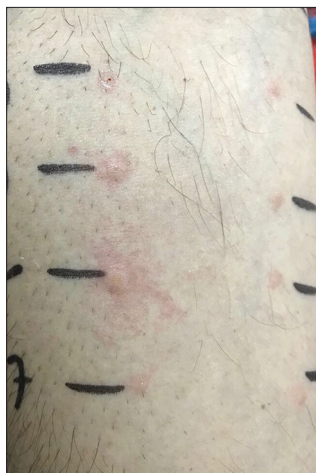

Figure 1: Erythematous papules on the flexor surface of the right forearm of the patient indicate a positive response.

and plane tree), compositae, mixture of grasses, *Dermatophagoides farinae*, *Dermatophagoides pteronyssinus*, Cladosporium, Aspergillus mix, Felis domesticus (cat), dog hair, mixed feathers (duck, goose, hen), *Poa pratensis*, *Pinus sylvestris*, mixtures of cereals (barley, wheat, oats, corn), *Secale cereale*, latex, cockroach, mosquito, cocoa, olive, onion, paprika, pepper, tea, wheat flour, cereal grain mix, apple, banana, orange, peach, strawberry, peanut, hazelnut, walnut, tomato, egg (whole), chicken, positive control and negative control (Table 1).

Allergen solutions were placed on the flexural surfaces of both forearms at a two cm distance from each other. Small pricks were made into the skin through allergen extract drops using disposable plastic lancet. The excess solutions were removed gently using a paper towel to prevent the mixing of allergens with each other. The results were evaluated 15 minutes after the skin pricks. Allergen reactions were considered positive when the wheal diameter was 3 mm or larger than the negative control (Figure 1).

RESULTS

The study included 18 patients (12 female, 6 male) with idiopathic generalized pruritus. The mean age of the patients was 38.5 (range: 18-47). The mean disease duration was 3.4 years (range: 2 months-15 years).

The past medical history was remarkable for angioedema in one patient, rosacea in one patient, allergic rhinitis in two patients and hyperlipidemia in two patients. Seven

Table 1: Allergen extracts used for the skin prick test

Allergens used for skin prick test	
1 Positive control	21 Mosquito
2 Negative control	22 Cocoa
3 <i>Betula verrucosa</i>	23 Olive
4 Salicaceae	24 Onion
5 Trees mixture	25 Paprika
6 Compositae	26 Pepper
7 Mixture of grasses	27 Tea
8 <i>Dermatophagoides farinae</i>	28 Wheat flour
9 <i>Dermatophagoides pteronyssinus</i>	29 Cereal grain mix
10 Cladosporium	30 Apple
11 Aspergillus mix	31 Banana
12 <i>Felis domesticus</i> (cat)	32 Orange
13 Dog hair	33 Peach
14 Mixed feathers	34 Strawberry
15 <i>Poa pratensis</i>	35 Peanut
16 <i>Pinus sylvestris</i>	36 Hazelnut
17 Mixtures of cereals	37 Walnut
18 <i>Secale cereale</i>	38 Tomato
19 Latex	39 Egg
20 Cockroach	40 Chicken

patients did not receive any prior treatment. However, 11 patients were treated with topical corticosteroids, emollients, oral antihistamines or intramuscular injections of corticosteroids previously.

The skin prick test results of the patients are depicted in Table 2. Eleven (61.1%) patients had at least one positive reaction to skin prick testing. However, 7 (38.9%) patients did not react to any allergens (Table 2).

DISCUSSION

Skin prick test is a quick, safe and minimally invasive method to detect reactions to food, drug, inhalant and occupational allergens [9]. Skin prick test is usually performed to investigate the allergens in patients with rhinoconjunctivitis, contact urticaria, asthma, atopic eczema, and suspected food allergy [10]. As the reaction to a specific allergen is localized, various allergens can be used at the same time. The prick test can be repeated to identify new sensitization in case of exposure to a new suspicious environmental allergen. Moreover, epidemiologic studies which determine sensitization rates in different areas contribute to create standardized allergen solutions [9]. Most common aeroallergens are house dust mites, pet dander, pollens and moulds, whereas commonly detected food allergens in adults include shellfish, nut and fruit allergies [11].

The skin prick test results of the patients with idiopathic generalized pruritus have been reported in a few study. Colgecen et al. reviewed skin prick test results

of 190 patients with idiopathic generalized pruritus, atopic dermatitis, chronic idiopathic urticaria, allergic rhinitis and asthma. The study revealed that 28 of the 53 patients with idiopathic generalized pruritus (52.8%) had at least one or more positive reaction to the skin prick test. Banana, *Dermatophagoides pteronyssinus* and latex were the most common allergies in the group of idiopathic generalized pruritus. However, pine pollen, wheat pollen and dog epithelium were the most common allergies in all of the patients [12].

Furthermore, Baz et al. investigated the skin prick test results of 127 patients with idiopathic generalized pruritus, atopic dermatitis and chronic idiopathic urticaria. Baz et al. revealed that 23 of the 52 patients with idiopathic generalized pruritus (44.2%) had at least one or more positive reaction to the skin prick test. *Dermatophagoides pteronyssinus* was the most common allergen in the group of idiopathic generalized pruritus. However, *Dermatophagoides farinae* and *Dermatophagoides pteronyssinus* were the most common allergens in all patients, respectively [13].

Stockli et al. reported a 26-year-old male patient with a 2-month history of generalized itching without any specific skin lesion. The past medical history was remarkable for non-seasonal rhinoconjunctivitis and consumption of cannabis and tobacco. Prick test showed positive reaction to the patient's cigarette and cannabis. Following the avoidance of only cannabis the symptoms regressed partially, without any treatment [14].

Vakaljan et al. presented a patient with chronic pruritus following the initiation of vitamin B12 supplementation for the treatment of pernicious anemia. Skin prick testing to nickel, cobalt chloride, and palladium chloride were identified as positive. Vakaljan et al. reported that the patient healed three days after the cessation of oral vitamin B12 supplementation. Sensitization to cobalt was reported to be a triggering factor for chronic pruritus [15].

In our study, skin prick test results of 18 patients with idiopathic generalized pruritus were reviewed. Most of the patients (61.1%) showed positive reaction to various allergen extracts. The most common allergies in Turkish patients were to trees mixture and *Aspergillus mix*. The test result of a patient showed a positive reaction even to tea, which is frequently consumed in Turkey. Hereby, the preliminary results of skin prick test for the evaluation of patients with generalized pruritus have been reported. As our data increase, we would like to

Table 2: The skin prick test results of the patients

Patients	Allergens with positive skin reaction
1	Hazelnut
2	-
3	-
4	-
5	-
6	<i>Aspergillus mix</i> , mosquito, chicken
7	Mixture of grasses, <i>poa pratensis</i> , mixtures of cereals, <i>secale cereale</i> , banana
8	-
9	Trees mixture, <i>compositae</i> , <i>felis domesticus</i> , cocoa, olive, paprika, tea
10	<i>Aspergillus mix</i> , mosquito, banana
11	Mixture of grasses, strawberry, egg
12	Peanut, hazelnut
13	Trees mixture, <i>poa pratensis</i>
14	-
15	Trees mixture, <i>aspergillus mix</i>
16	Tomato
17	Peach, strawberry, peanut
18	-

determine and share the most common allergens in Turkish patients with idiopathic generalized pruritus with our colleagues.

Statement of Human and Animal Rights

All procedures followed were in accordance with the ethical standards of the responsible committee on human experimentation (institutional and national) and with the Helsinki Declaration of 1975, as revised in 2008.

Statement of Informed Consent

Informed consent was obtained from all patients for being included in the study.

REFERENCES

1. Rajagopalan M, Saraswat A, Godse K, Shankar DS, Kandhari S, Shenoj SD, et al. Diagnosis and management of chronic pruritus: an expert consensus review. *Indian J Dermatol.* 2017;62:7-17.
2. Feramisco JD, Berger TG, Steinhoff M. Innovative management of pruritus. *Dermatol Clin.* 2010;28:467-78.
3. Goyal A, Balai M, Mittal A, Khare AK, Gupta LK. Pattern of geriatric dermatoses at a Tertiary Care Teaching Hospital of South Rajasthan, India. *Our Dermatol Online.* 2017;8:237-41.
4. Nowak D, Yeung J. Diagnosis and treatment of pruritus. *Can Fam Physician.* 2017;63:918-24.
5. Reamy BV, Bunt CW, Fletcher S. A diagnostic approach to pruritus. *Am Fam Physician.* 2011;84:195-202.
6. Grundmann S, Ständer S. Chronic pruritus: clinics and treatment. *Ann Dermatol.* 2011;23:1-11.
7. Millington GWM, Collins A, Lovell CR, Leslie TA, Yong ASW, Morgan JD, et al. British Association of Dermatologists' guidelines for the investigation and management of generalized pruritus in adults without an underlying dermatosis, 2018. *Br J Dermatol.* 2018;178:34-60.
8. Yosipovitch G, David M. The diagnostic and therapeutic approach to idiopathic generalized pruritus. *Int J Dermatol.* 1999;38:881-7.
9. Heinzerling L, Mari A, Bergmann KC, Bresciani M, Burbach G, Darsow U, et al. The skin prick test - European standards. *Clin Transl Allergy.* 2013;3:3.
10. Berger A. Skin prick testing. *BMJ.* 2002;325:414.
11. Coetzee O, Green RJ, Masekela R. A guide to performing skin-prick testing in practice: tips and tricks of the trade. *S Afr Fam Pract.* 2013;55:415-9.
12. Colgecen E, Ozyurt K, Intepe YS, Kapsuz Gencer Z, Ozkiris M, Ede G, et al. Skin prick test results in patients with atopic symptoms in Yozgat district. *J Clin Exp Invest.* 2014;5:64-8.
13. Baz K, Guvenc U, Cordan Yazici A, Kokturk A, Ikizoglu G, Tasdelen B. Atopy and skin diseases in Mersin. *Turkiye Klinikleri J Dermatol.* 2007;17:105-11.
14. Stockli SS, Bircher AJ. Generalized pruritus in a patient sensitized to tobacco and cannabis. *J Dtsch Dermatol Ges.* 2007;5:303-4.
15. Vakaljan S, Ohayon Hamilton J. Cobalt as the culprit: vitamin B12 supplementation as a trigger for chronic pruritus. *Ann Allergy Asthma Immunol.* 2017;119:S17-96.

Copyright by Funda Tamer, et al. This is an open-access article distributed under the terms of the Creative Commons Attribution License, which permits unrestricted use, distribution, and reproduction in any medium, provided the original author and source are credited.

Source of Support: Nil, Conflict of Interest: None declared.

Lichen planus pigmentosus and association with autoimmune diseases: A case–control study

Monia Youssef¹, Ines Lahouel¹, Mouna Korbi¹, Yosra Soua¹, Hela Marmouch², Hayet Akkari¹, Meriem Mohamed¹, Hichem Belhajali¹, Asma Belghith³, Jameleddine Zili¹

¹Dermatology Department, Fattouma Bourguiba Hospital, University of Monastir, Tunisia, ²Endocrinology Department, Fattouma Bourguiba Hospital, University of Monastir, Tunisia, ³Community Medicine Department, Fattouma Bourguiba Hospital, University of Monastir, Tunisia

Corresponding author: Dr Ines Lahouel, E-mail: lahouel.iness@gmail.com

ABSTRACT

Background: Studies on the co morbidities seen with lichen Planus Pigmentosus (LPP) are limited. **Aims:** We sought to determine the prevalence of auto immune diseases (AD) associated with LPP. **Methods:** A total of 30 patients with LPP and 30 age and sex matched controls were examined. Both groups were evaluated for the presence of AD using physical examination and immunological tests. **Results:** We collected 30 LPP patients. There were 9 men and 21 women. Prevalence of AD was higher in LPP patients (40.0%) than in the control group (3.3%). LPP was significantly associated with AD, the age and gender adjusted OR was 22.9; P: 0.005. Twelve patients had an associated AD. There was no statistically significant difference between the group with ADs and without ADs concerning the sex, the age of onset of the disease, the extent of the lesions and the evolution. The immunological tests were positive in only one patient. **Limitations:** This study was performed in a little sample with a geographically restricted population. **Conclusion:** We found a frequent association of LPP with ADs. We suggest that autoimmunity might be a pathogenic factor of LPP.

Key words: Lichen planus pigmentosus; Autoimmune diseases; Case–control study

INTRODUCTION

Lichen planus pigmentosus (LPP) is an uncommon variant of lichen planus (LP), characterized by the insidious onset of dark brown macules in sun-exposed areas and flexural folds with or without slight pruritus [1,2]. It was originally reported from India, but it tends to occur also in other racial and ethnic groups such as Latin Americans, Middle Eastern population, Japanese and Koreans [3-5].

The epidemiologic and physiopathologic characteristics of LPP have not yet been defined. LPP has rarely been described in association with other diseases. The autoimmune pathogenesis of LPP is a controversial subject. No clear association between LPP and auto immune diseases (AD) exists. In our clinical experience, we have observed that patients with LPP often have an AD. A careful

review of literature did not find studies that specifically address the prevalence of ADs in patients with LPP. Therefore, we realized this study with a purpose to determine the prevalence of AD in patients with LPP.

MATERIALS AND METHODS

Study Design

A case–control study was performed to assess the prevalence of AD in patients with LPP. The patients and controls were matched on age and sex, and recruited over a 6- year period (2011-2016).

Patients

We aimed to enroll, consecutively, all patients with a diagnosis of LPP who were admitted to the clinics of

How to cite this article: Youssef M, Lahouel I, Korbi M, Soua Y, Marmouch H, Akkari H, Mohamed M, Belhajali H, Belghith A, Zili J. Lichen planus pigmentosus and association with autoimmune diseases: A case–control study. Our Dermatol Online. 2019;10(2):125-130.

Submission: 08.09.2018; **Acceptance:** 11.02.2019

DOI: 10.7241/ourd.20192.4

the dermatology department of Monastir hospital in Tunisia.

Inclusion criteria for cases were the presence of largely asymptomatic bluish / blackish brown, macules, distributed mainly on the face, neck and upper extremities. The histological criteria were: (a) epidermal changes: minimal change in epidermal thickness; keratinocyte apoptosis; and vacuolar degeneration of the basal cell layer and (b) dermal changes: presence of band like or perivascular lymphohistiocytic inflammatory infiltrate; scattered melanophages; and melanin incontinence. 30 patients with a diagnosis of LPP were enrolled as the patient group.

Controls

The control group consisted of 30 age and sex matched individuals (Table 1). The controls were selected among patients with skin diseases other than LPP (chronic pruritus with no specific lesions). The source population for cases and controls was the same.

Collection of Data

All cases and controls were examined by a dermatologist who registered demographic, biometric and other relevant data on a case report form.

The age of onset, duration of the disease, site of onset of pigmentation, associated symptoms and family history were recorded.

The information was also obtained regarding any related external factors (such as drug intake prior to the onset or use of cosmetics), associated auto immune diseases, cutaneous diseases or other systemic diseases.

A record was made for the morphology and distribution of lesions, extent of lesions, and mucosal, hair and nail involvement.

For all patients and controls, laboratory tests were performed including complete blood count (CBC), sedimentation rate (SR), blood sugar test (BS), antinuclear antibodies (ANA), anti thyroglobulin

antibodies (TgAb), anti-thyroid peroxidase antibodies (TPOAb) and serology tests for hepatitis B and C.

The age of onset of the disease, the sex, the site of early lesions, the extent of the lesions, the inversus type, were compared between the two groups of LPP patients with and without ADs, in order to establish if there is or not any factors that may influence this association.

Statistical Analysis

Statistical analysis was performed on the Software Statistical Package for the Social Sciences (SPSS 21). For between-group comparisons, the independent samples t-test was used for normally distributed continuous variables and Pearson chi-squared test or Fisher exact test was used for nominal data where appropriate. Multiple logistic regressions were performed to calculate the odds ratio (OR) and 95% confidence interval (CI) after adjusting for age and gender. The statistical significance was fixed with p inferior to 0.05.

RESULTS

The study included 30 cases and 30 controls. For patients, there were 9 men and 21 women (M/F = 0.42) and the average age at onset was 37.6 years (range 6–68 years). There were 3 children (1 aged 6 years, 2 aged 13 years). The duration of the disease ranged from 1 month to 10 years. Six (20%) patients reported mild pruritus. There was no history of previous inflammatory process on the affected areas for all the patients. A causal relationship with drugs, recent sun exposure, cosmetics or trauma were not identified for all patients. Family history of a similar skin disorder was negative in all the 30 patients.

The clinical pattern of pigmentation within LPP patients was mostly diffuse. The face and trunk (Fig. 1) were the commonest sites affected. Inversus type of LPP was seen in seven patients (23.3%) with most of them localized in the axillae (Fig. 2). Mucosal lesion (oral involvement) was noticed in one patient. The palms, soles, scalp and nails were spared in all patients.

Skin biopsies were performed from all the patients. Most of the patients had overlapping features of the two patterns (pattern of inflammatory infiltrate and superficial perivascular pattern), with predominance of one of them. Melanin incontinence and melanophages

Table 1: Distribution of cases and controls

	Cases (n=30)	Controls (n=30)	p
Gender (%)			
Man	9 (30%)	9 (30%)	1
Woman	21 (70%)	21 (70%)	1
Mean age (years)	37.6+-16.4	38.5+-15.3	0.82

were constant findings in all cases (Fig. 3). Hyperkeratosis was marked in 11 (36.6%).

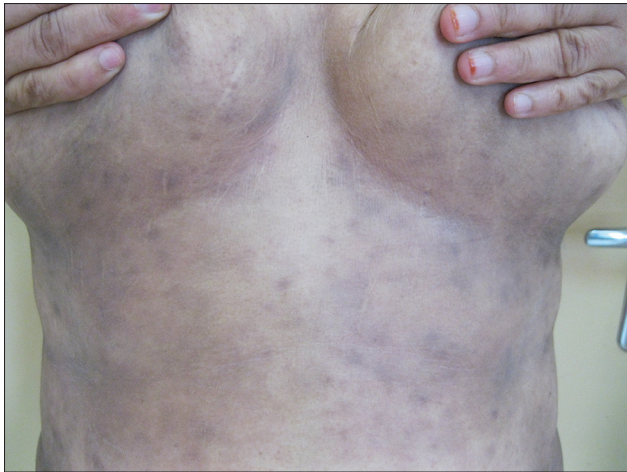

Figure 1: Brown macules localized at the trunk.

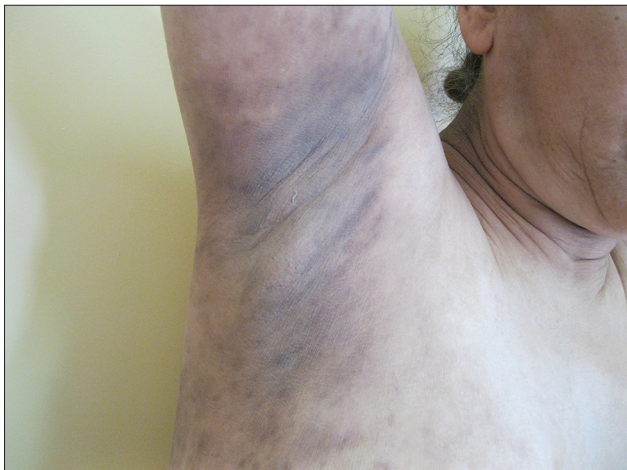

Figure 2: Inversus subtype of lichen planus pigmentosus: brown macules in the axillary fold.

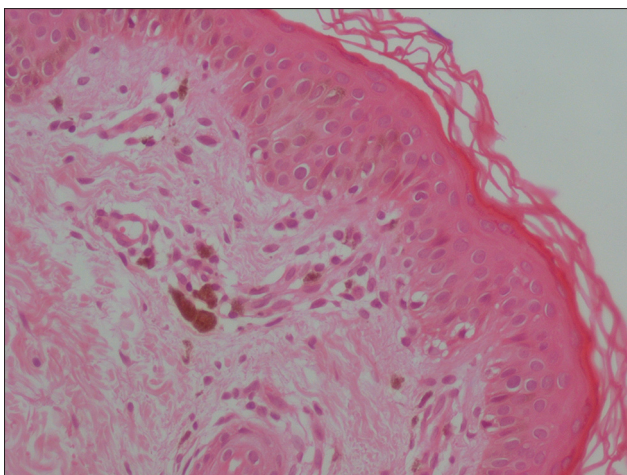


Figure 3: Melanin incontinence and melanophages in the upper dermis (H & E, x200).

Prevalence of AD was higher in LPP patients (40.0%) than in the control group (3.3%). LPP was significantly associated with AD, the age and gender adjusted OR was 22.9; CI 95%: 2.62-199.82; P: 0.005 (Table 2).

Twelve patients (40%) with AD were collected. No significant difference was observed in the extent of lesions in groups with and without AD.

Six patients were diabetic (three patients had diabetes type 1 (DT1) and three patients had Latent Autoimmune Diabetes in Adults (LADA). Three patients had chronic inflammatory bowel diseases (one patient had Crohn’s disease, one patient had ulcerative colitis and one patient had lymphocytic colitis). The patient who had lymphocytic colitis had also hypothyroidism. One patient had rheumatoid arthritis, one patient had anti phospholipid antibody syndrome and one patient had Gougerot Sjogren syndrome.

The diagnosis of AD preceded LPP in 9 cases, was made simultaneously with LPP in 2 patients (LADA, autoimmune thyroiditis). One patient developed LADA one year after the diagnosis of LPP.

For all patients the CBC, SR were within normal limits. Hepatitis B and C serology tests were negative for all patients.

The recommended immunological tests were positive in only one patient, who had rheumatoid arthritis. In fact, ANA, anti-nucleosome antibodies, anti TgAb and anti TPO Ab were significantly positive (TPOAb=93UI/ml, Tg Ab=390UI/ml, ANA=1/800, anti nucleosome Ab=222 UI/ml) while the patient was asymptomatic and had no previous history for lupus nor dysthyroidism.

There were no significant differences regarding the serum levels of CBC, SR, ANA, TgAb, TPOAb and Hepatitis B and C serology tests between cases and controls (P = 1, 049, 1, 1 and 1 respectively).

The results of the characteristics of patients with AD are summarized in Table 3.

Table 2: Association with AD for cases and controls

	Association with AD		p	ORa*	CI 95% (ORa)
	Positive	Negative			
Cases	12 (40%)	18 (60%)	0.005	22.86	2.63-199.83
Controls	1 (3.3%)	29 (96.7%)			

ORa*: Age and sexe adjusted OR

Table 3: Clinical, histological, and therapeutic features of patients with LPP associated to AD

Sex/age	Duration	Associated AD	Site	Histological examination	Treatment	Course
F/29	3 months	DT 1	Thigh	Perivascular lymphohistiocytic infiltrate, pigmentary incontinence, keatinocyte necrosis	Topical betamethasone	No improvement
M/36	2 months	DT 1	Face, axillary folds	Hypergranulosis, melanin incontinence, perivascular lymphohistiocytic infiltrate	Topical betamethasone	Aggravation
F/54	4 months	LADA	Face, abdomen, axillary folds	Hyperkeratosis, hypergranulosis, Band-like lymphocytic infiltrate	Topical betamethasone	No improvement
F/62	3 months	LADA	Back, Upper and lower limbs	Thinning of the epidermis, hyperkeratosis, pigmentary incontinence, perivascular lymphohistiocytic infiltrate	Topical betamethasone	No improvement
F/56	2 months	LADA	Back	Hyperkeratosis, pigmentary incontinence, melanophages	Topical betametasone	No improvement
F/30	4 months	D T 1	Lower limbs	hypergranulosis, Band-like lymphocytic infiltrate, pigmentary incontinence	Topical betametasone	No improvement
M/30	4 months	Lymphocytic colitis+hypothyroidism	Trunk	Hyperkeratosis, hypergranulosis, Band-like lymphocytic infiltrate, pigmentary incontinence	Topical betametasone	Slight improvement
F/31	6 months	SAPL	Back	Hyperkeratosis, pigmentary incontinence, lymphohistiocytic infiltrate, melanophages	Topical betametasone	Slight improvement
F/68	6 months	Rheumatoid arthritis	Back, upper and lower limbs	Hyperkeratosis, hypergranulosis band-like lymphocytic infiltrate and melanophagia in the papillary dermis	Topical betametasone	No improvement
F/37	1 year	Gougerot Sjogren syndrome	Lower members, axillary folds	Lichenoid dermatitis, pigmentary incontinence	Topical betametasone	No improvement
M/52	3 months	Crohn 's disease	Face	Hyperkeratosis, pigmentary incontinence, lymphohistiocytic infiltrate, melanophages	Topical betametasone	Slight improvement
F/42	8 months	Ulcerative colitis	Face, upper and lower limbs	Keatinocyte necrosis, melanin incontinence, perivascular lymphohistiocytic infiltrate, melanophages	Topical betametasone	Slight improvement

DISCUSSION

Our study is a pilot study and the first study from Tunisia seeking for LPP associated diseases. Our results were in agreement with previous studies from Japan, India and Kuwait regarding the clinico- epidemiologic aspects of LPP [3-6]. Nevertheless, we report a significant association between LPP and ADs (more than the quarter of our patients had associated ADs). This association has not been reported before. Analysis of the prevalence of ADs in patients with or without LPP and possible associated risk factors, particularly sex, age, site of early lesions, extent of lesions, itching and the course after topical corticosteroid, did not show statistically significant differences.

Although the association between LP and ADs is well known, a similar prevalence in LPP patients has not been established. In fact, an Italian epidemiologic study had reported data supporting the association between LP and alopecia areata and ulcerative colitis, which are considered immune-mediated diseases [7]. A significant association between oral lichen planus (OLP) and thyroid gland disease specifically with

hypothyroidism had been reported [8]. It had also been reported that, in Chinese patients with OLP, 21% have TgAb and 24% have TMA autoantibodies compared with 1.9% of healthy control subjects [9].

Recently, Chung PI et al [10] reported a significant association with systemic lupus erythematosus, Sjögren's syndrome, dermatomyositis, vitiligo and alopecia areata among patients with LP.

A case of LPP associated with minimal change nephrotic syndrome have been reported [11]. Authors suggested that this association may reflect common immunological abnormalities. Otherwise, three cases of frontal fibrosing alopecia associated to LPP have been reported [12-14].

In our study, auto-immune diabetes was the most frequent AD associated to LPP (20%). The association between LPP and diabetes had not been reported before. However, the relationship between LP and diabetes was studied previously. A study concerning the prevalence of OLP in diabetes mellitus according to the type of diabetes [15], found that the prevalence

of OLP in type 1 diabetic patients was 5.76%, in type 2, 2.83%, and 1.82% in the controls. Giving the fact that DT 1 and OLP are characterized with auto immune phenomena and T cell immune responses respectively, the authors suggested that the immune system may play a role in the appearance of OLP in patients with DT1.

We suggest that immunological mechanisms mediate the pathogenesis of LPP, as evidenced by association with diseases of altered immunity.

We didn't found studies seeking for the association between LPP and AD but we found a study published recently looking for the association between LPP and thyroid dysfunction [16]. Thyroid disorder was found to be an associated factor in LPP especially hypothyroidism. Levels of thyroid peroxidase antibody in the LPP patients were found to be significantly higher than those of controls. These results support our hypothesis concerning the autoimmune pathogenesis of LPP.

Otherwise, LPP have been reported associated with a non AD which is Hepatitis C. In fact, in the study of Al-Mutairi, 60.6% of patients with LPP had positive hepatitis C serology tests. These patients had significantly elevated serum ALT and AST levels, and they were also significantly of older age group and their skin disease was of longer duration compared with patients with negative serology for HCV. In our study, serology tests for Hepatitis B and C were negative for all patients.

Limitations

Because of the rarity of LPP, and that this study was done in a geographically restricted population, other studies with larger sample sizes from different parts of the world are needed to add further evidence for this association of LPP and AD.

CONCLUSION

As it has been shown in our study, there is an increased risk multiplied by 22.8 for patients with AD to develop LPP. Patients with LPP are at increased risk of multiple co morbidities such as auto immune diabetes, chronic inflammatory bowel diseases, hypothyroidism, rheumatoid arthritis, anti phospholipid antibody syndrome and Gougerot Sjogren syndrome, which support the key role of autoimmunity in the pathogenesis of LPP. Further researches are required to elucidate the

underlying mechanism of the association of these autoimmune co morbid diseases with LPP. Regarding our findings, immunological tests in patients with LPP are required, especially if an AD is suspected based upon a review of symptoms. We suggest also that LPP patients should be supervised because they could develop AD.

Statement of Human and Animal Rights

All procedures followed were in accordance with the ethical standards of the responsible committee on human experimentation (institutional and national) and with the Helsinki Declaration of 1975, as revised in 2008.

Statement of Informed Consent

Informed consent was obtained from all patients for being included in the study.

REFERENCES

1. Youssef M, Lahouel I, Héla M, Hadhri R, Akkari H, Mohamed M, et al. Childhood lichen planus pigmentosus. *Our Dermatol Online*. 2017;8:104-5.
2. Nag F, Ghosh A, Chatterjee G, Choudhary N. Lichen planus pigmentosus: two atypical presentation. *Our Dermatol Online*. 2013;4:78-9.
3. Kashima A, Tajiri A, Yamashita A, Asada Y, Setoyama M. Two Japanese cases of lichen planus pigmentosus-inversus. *Int J Dermatol*. 2007;46:740-2.
4. Hassan I, Rather PA, Sajad P. Linear lichen planus pigmentosus and coincidental ipsilateral facial nerve palsy: An unusual observation. *Our Dermatol Online*. 2012;3:361-2.
5. Mortazavi M, Saad El-Din SA. Bilateral linear lichen planus along the lines of Blaschko: Report of a rare case and brief review. *Our Dermatol Online*. 2017;8:322-5.
6. Al-Mutairi N, El-Khalawany M. Clinicopathological characteristics of lichen planus pigmentosus and its response to tacrolimus ointment: an open label, non-randomized, prospective study. *J Eur Acad Dermatol Venereol*. 2010;24:535-40.
7. Gruppo Italiano Studi Epidemiologi in Dermatologia (GISED). Epidemiological evidence of the association between lichen planus and two immune-related diseases. Alopecia areata and ulcerative colitis. *Arch Dermatol* 1991;127:688-91.
8. Siponen M, Huuskonen L, Laara E, Salo T. Association of oral lichen planus with thyroid disease in a Finnish population: a retrospective case-control study. *Oral Surg Oral Med Oral Pathol Oral Radiol Endod*. 2010;110:319-24.
9. Chang JY, Chiang CP, Hsiao CK, Sun A. Significantly higher frequencies of presence of serum autoantibodies in Chinese patients with oral lichen planus. *J Oral Pathol Med*. 2009;38:48-54.
10. Chung P, Hwang C, Chen Y, Lin MW, Chen TJ, Hua TC, et al. Autoimmune comorbid diseases associated with lichen planus: a nationwide case-control study. *J Eur Acad Dermatol Venereol*. 2015;29:1570-5.
11. Mancuso G, Berdondini RM. Coexistence of lichen planus pigmentosus and minimal change nephrotic syndrome. *Eur J Dermatol*. 2009;19:389-90.
12. Rao R, Sarda A, Khanna R, Balachandran C. Coexistence of frontal fibrosing alopecia with lichen planus pigmentosus. *Int J Dermatol*.

- 2014;53:622-4.
13. Dlova NC. Frontal fibrosing alopecia and lichen planus pigmentosus: is there a link? *Br J Dermatol.* 2013;168:439-42.
 14. Berliner JG, McCalmont TH, Price VH, Berger TG. Frontal fibrosing alopecia and lichen planus pigmentosus. *J Am Acad Dermatol.* 2014;71:e26-7.
 15. Petrou-Amerikanou C, Markopoulos AK, Belazi M, Karamitsos D, Papanayotou P. Prevalence of oral lichen planus in diabetes mellitus according to the type of diabetes. *Oral Dis.* 1998;4:37-40.
 16. Karn D, Kc S, Timalina M. Lichen Planus Pigmentosus: A study for association of Thyroid Dysfunction. *Kathmandu Univ Med J (KUMJ).* 2016;14:36-40.

Copyright by Monia Youssef, et al. This is an open-access article distributed under the terms of the Creative Commons Attribution License, which permits unrestricted use, distribution, and reproduction in any medium, provided the original author and source are credited.
Source of Support: Nil, **Conflict of Interest:** None declared.

Immunoglobulin levels in maternal blood, cord blood and breast milk of Nigerian pregnant women using hydroquinone and non-hydroquinone containing skin lightening creams

Agatha Obiageli Nwosu, Arinola Olatunbosun Ganiyu

Department of Chemical Pathology, College of Medicine University of Ibadan, Ibadan, Nigeria

Corresponding author: Prof. Arinola Olatunbosun Ganiyu, E-mail: drarinolaog64@yahoo.com

ABSTRACT

Background: Skin lightening is practiced by pregnant women whose skin gets darker due to increased skin pigmentation arising from pregnancy associated hormonal changes but report on the levels of immunoglobulin (Ig) classes in pregnant users of skin lightening creams or their babies was not encountered. This study was carried out to assess immunoglobulin levels in maternal blood, cord blood and breast milk of Nigerian pregnant women using hydroquinone and non hydroquinone containing skin lightening creams. **Method:** Sixty participants were recruited for this study. Thirty of them were daily users of skin lightening creams for six to seven years, while the remaining thirty participants never used skin lightening creams served as controls. Skin lightening creams were classified as hydroquinone containing or hydroquinone lacking based on manufacturer instructions. Levels of mercury (Hg) and Ig classes (IgG, A and M) were measured in maternal sera, cord sera and breast milk plasma using Atomic Absorption Spectrophotometry (AAS) and enzyme-linked immunosorbent assay (ELISA) respectively. The data were presented as mean \pm SD and analyzed using Student t-test. **Results:** The levels of Hg in maternal sera ($0.37 \pm 0.05 \mu\text{g/dl}$) of users of hydroquinone containing skin lightening creams was statically significantly higher when compared with the levels of Hg ($0.32 \pm 0.05 \mu\text{g/dl}$) in users of non-hydroquinone containing creams ($p < 0.05$). Maternal serum IgG, cord IgG and breast milk IgG of the pregnant women using skin lightening creams were significantly higher when compared with the controls. Also, the mean maternal IgM, cord IgM and breast milk IgM of the pregnant women using skin lightening creams were significantly higher when compared with the controls ($p < 0.05$). Statically significant differences were observed when the mean levels of maternal IgA ($246.08 \pm 90.30\text{mg/dl}$), cord IgA ($256.21 \pm 111.91\text{mg/dl}$) and breast milk IgA ($244.07 \pm 104.08\text{mg/dl}$) in users of hydroquinone containing skin lightening creams were compared with the levels of maternal IgA ($253.39 \pm 78.02\text{mg/dl}$), cord IgA ($264.74 \pm 86.16\text{mg/dl}$), and breast milk IgA ($260.54 \pm 78.98\text{mg/dl}$) in users of non – hydroquinone containing skin lightening creams ($p > 0.05$). **Conclusion:** Raised IgG and IgM in mothers and babies of skin lightening creams users could be a result of polyclonal B lymphocyte activation which may lead to autoimmune disease later in life. Also, Hg but not hydroquinone had negative effect on babies' immunoglobulin levels. **Recommendation:** There is need for public awareness programs to enlighten the populace about the danger involved in the use of skin lightening creams particularly among pregnant women.

Key words: Immunoglobulins; Pregnancy; Skin lightening creams

INTRODUCTION

Skin lightening cream, refers to any substance or mixture used for the purpose of lightening the skin color. It lightens the skin by inhibiting the production

of tyrosinase, an enzyme used in synthesis of melanin, the dark skin pigment. This action does not bleach the existing skin pigment but stops the formation of new dark pigment. A significant proportion of individuals misuse these products thereby over lightening their skins.

How to cite this article: Nwosu AO, Ganiyu AO. Immunoglobulin levels in maternal blood, cord blood and breast milk of Nigerian pregnant women using hydroquinone and non-hydroquinone containing skin lightening creams. Our Dermatol Online. 2019;10(2):131-137.

Submission: 29.12.2018; **Acceptance:** 16.02.2019

DOI: 10.7241/ourd.20192.5

Though this practice is seen at all ages in both sexes, some studies have reported a much higher prevalence among pregnant women whose skin gets darker during pregnancy due to increased skin pigmentation arising from pregnancy associated hormonal changes [1]. Apart from pregnancy, other reasons for skin lightening is either for fame, cosmetic purposes or also due to the presumed superiority and desirability of fair skin [2]. Yet the effect of skin lightening creams on the health of pregnant women is given little attention.

The active components of these skin lightening products include hydroquinone, mercury and steroid [1] which with constant use may cross the placenta and cause harm to the fetus or pass to the breast milk and cause harm to the infant. Misuse of skin lightening products is becoming rampant in Africa, and especially in Nigeria [1,3,4]. Disruption of primary innate function of the epidermis in the process of skin lightening through the chemical agents in these skin lightening creams have been reported and may possibly lead to susceptibility of the users to localized or systemic infections [5]. Hence the need to assess humoral immunity in pregnant women using skin lightening creams.

Topical application of mercury products lead to absorption and eventual mercury poisoning which is manifested by a range of symptoms including psychiatric, neurological and kidney problems [6]. Mercury has been reported to cause immunologically mediated diseases such as glomerulonephritis, acrodynia, contact allergy and fetal abnormalities [7]. Pregnant women using skin lightening creams containing steroid are more likely to have smaller placenta and give birth to low - birth -weight babies though baby's stomach was shown not to absorb steroids [8].

Since skin lightening creams has been shown to cause immunologically mediated diseases skin inflammation and suppression of innate immunity. Moreover, pregnancy is a known state of immunomodulation. Thus, there is need to assess the level of immunoglobulin (Ig) classes and Hg in maternal blood, cord blood and breast milk of Nigerian women using skin lightening creams.

SUBJECTS AND METHODS

Subjects

A total of sixty (60) pregnant Nigeria women participated in this study. Thirty (30) of them were daily

users of skin lightening creams for between 6-7 years, while the remaining thirty subjects were pregnant non-users of skin lightening creams served as controls. The subjects were recruited from two maternity centers in Ibadan, Nigeria. Those on special medication, history of recent blood transfusion, those with various infections, those with complicated pregnancy, those on special diet and those with pre- term delivery were excluded from the study. The subjects aged between 26 years – 32 years.

Classification of Skin Lightening Creams

The trade names of the skin lightening creams used by the pregnant women are Movate, Carotone, Pure skin, Skin Light, Perfect White, Caro White, Looking Good and Clear Essence. The creams were classified those containing hydroquinone (Caro White, Carotone, Skin Light and Looking Good) and those not containing hydroquinone (Movate, Perfect White, Pure Skin and Clear Essence) based on manufacturers instruction. The creams were diluted 1:64 with de-ionized water before Hg analysis.

Sample Collection

Institutional ethical approval was obtained from University of Ibadan/University College Hospital Ibadan Ethical Review Committee. Informed consent was obtained from mothers before sample collection. Five milliliters (5ml) of venous blood and colostrum were collected from each mother. Also 5ml of cord blood was collected from babies after cord clamping during delivery. The blood samples were collected into sterile plain tubes and spun at 3000rpm for 5 minutes to obtain serum and stored at -20°C until analysis. Breast milk samples were collected by manual expression into sterile plain tubes, spun at 3000rpm for 5 minutes. The fat layer was carefully removed to obtain fat free milk plasma and then stored at -20°C until analysis. The samples were collected with the assistance of a Gynecologist.

Determination of Mercury levels by (AAS) Technique

Atomic absorption Spectrophotometry (AAS) is a spectro analytical procedure for the quantitative determination of chemical elements using the absorption of optical radiation (light) by free atoms in the gaseous state. The technique makes use of absorption spectrometry to assess the concentration of

an analyte in a sample. It requires standards with known analyte content to establish the relation between the measured absorbance and the analyte concentration and relies on the Beer-Lambert Law. The electrons of the atoms in the atomizer can be promoted to higher orbitals (excited state) for a short period of time (nanoseconds) by absorbing a defined quantity of energy (radiation of a given wavelength). This amount of energy, that is, wavelength, is specific to a particular electron transition in a particular element. Generally, each wavelength corresponds to only one element, and the width of an absorption line is only of the order of a few picometers (pm), which gives the technique its elemental selectivity. The radiation flux without a sample and with a sample in the atomizer is measured using a detector, and the ratio between the two values (the absorbance) is converted to analyte concentration or mass using the Beer-Lambert Law.

Measurement of Immunoglobulin Classes (IgG, IgA and IgM) by ELISA Technique

Levels of immunoglobulin classes (IgG, IgA and IgM) were determined by enzyme-linked immunosorbent assay (ELISA) as previously described [9]. A fixed volume per well of appropriate sample dilution buffer, antigen standard cocktail, or an experimental sample was pipetted into microtiter plates. This sample was incubated at room temperature (25-27°C) for a specified length of time based on the micronutrient being analyzed. The ELISA immunoplate was washed 3 times with 350µl/well of washing buffer. Then 100µl per well of detection antibodies was added. This mixture was incubated at room temperature for 60 minutes. The immunoplate was rewashed 3 times with 350µl/well of washing buffer. A concentration of 100µl/well of diluted Avidin-HRP conjugate was added, after which the plate was incubated at room temperature for 30 minutes in darkness. The plate was washed 4 times and 100µl/well of developing solution was added. The reaction was stopped with 100µl/well of Stop Solution and the optical density (OD) was read at specified wavelength within 30 minutes following the addition of Stop Solution. The average absorbance value of each OD was plotted against corresponding cytokine values to create a standard curve. The average absorbance of each serum sample was used to determine corresponding immunoglobulin values by interpolating from the curve. The samples were run in duplicates and with the technician being unaware of which fuel group the samples came from.

Statistical Analysis

The results obtained were expressed as mean \pm standard deviation ($\bar{x} \pm S.D$) and compared using student t-test, Pearson analysis was used to correlate the levels of immunoglobulin classes with levels of Hg. The differences were statistically regarded as significant at $p < 0.05$.

RESULTS

A total of sixty (60) pregnant Nigeria women participated in this study. Thirty (30) of them were daily users of skin lightening creams for between 6-7 years, while the remaining thirty subjects were pregnant non-users of skin lightening creams served as controls. The subjects were recruited from two maternity centers in Ibadan, Nigeria. Those on special medication, history of recent blood transfusion, those with various infections, those with complicated pregnancy, those on special diet and those with pre-term delivery were excluded from the study. The mean age of users of skin lightening cream was 27.8 ± 3.7 years while that of the control was 28.0 ± 5.6 years.

Table 1 presents the levels ($\bar{x} \pm SD$) of IgA, IgG and IgM in the maternal sera, cord blood sera and breast milk plasma of pregnant women using skin lightening creams compared with controls. The mean levels of maternal IgA, cord IgA and breast milk IgA of the of the pregnant women using skin lightening creams were 240.02 ± 86.63 mg/dl, 252.56 ± 105.16 mg/dl and 236.55 ± 97.81 mg/dl respectively, while the corresponding values in the control subjects were 236.87 ± 59.53 mg/dl, 238.57 ± 73.06 mg/dl and 234.74 ± 79.57 mg/dl respectively. The levels of maternal IgG, cord IgG and breast milk IgG of the of the pregnant women using skin lightening creams were 1102.87 ± 243.46 mg/dl, 1123.49 ± 208.35 mg/dl and 1056.36 ± 203.42 mg/dl respectively, while the corresponding values in the control subjects were 697.14 ± 175.50 mg/dl, 702.15 ± 215.03 mg/dl and 690.87 ± 234.18 mg/dl respectively. The levels of maternal IgM, cord IgM and breast milk IgM of the pregnant women using skin lightening creams were 221.36 ± 34.59 mg/dl, 229.78 ± 50.33 mg/dl and 215.56 ± 46.73 mg/dl respectively while the corresponding values in the controls were 185.10 ± 46.59 mg/dl, 186.43 ± 57.09 mg/dl and 183.44 ± 62.18 mg/dl respectively. There were no statistical significant difference between the levels of maternal IgA, cord IgA and breast milk IgA in the test participants when compared with the

controls. Maternal serum IgG, cord IgG and breast milk IgG of the pregnant women using skin lightening creams were significantly higher when compared with the controls. Also, the mean maternal IgM, cord IgM and breast milk IgM of the pregnant women using skin lightening creams were significantly higher when compared with the controls ($p < 0.05$ in each case). Table 2 presents the levels ($\bar{x} \pm SD$) of Ig classes (IgA, IgG and IgM) in maternal sera, cord sera and breast milk plasma in users of hydroquinone containing skin lightening creams compared with the levels in users of non – hydroquinone containing creams.

No statistical significant differences were observed when the mean levels of maternal IgA (246.08 ± 90.30 mg/dl), cord IgA (256.21 ± 111.91 mg/dl) and breast milk IgA (244.07 ± 104.08 mg/dl) in users of hydroquinone containing skin lightening creams were compared with the levels of maternal IgA (253.39 ± 78.02 mg/dl), cord IgA (264.74 ± 86.16 mg/dl), and breast milk IgA (260.54 ± 78.98 mg/dl) in users of non – hydroquinone containing skin lightening creams ($p > 0.05$ in each case). No statistical significant differences were observed when the mean levels of maternal IgG (1093.68 ± 219.21 mg/dl), cord IgG (1093.64 ± 171.80 mg/dl) and breast milk IgG (1047.30 ± 156.13 mg/dl) in users of hydroquinone containing skin lightening creams when compared with the levels of maternal IgG (1067.80 ± 294.78 mg/dl), cord IgG

(1092.79 ± 247.25 mg/dl) and breast milk IgG (1045.33 ± 288.43 mg/dl) in users of non– hydroquinone containing skin lightening creams ($p > 0.05$ in each case). Also no statistical significant differences were observed when the mean levels of maternal IgM (223.80 ± 35.05 mg/dl), cord IgM (229.17 ± 55.49 mg/dl) and breast milk IgM (218.78 ± 49.65 mg/dl) in users of hydroquinone containing skin lightening creams were compared with the levels of maternal IgM (225.47 ± 30.04 mg/dl), cord IgM (233.62 ± 32.33 mg/dl) and breast milk IgM (221.41 ± 35.11 mg/dl), in users of non–hydroquinone containing skin lightening creams ($p > 0.05$ in each case).

Table 3 shows the levels ($\bar{x} \pm SD$) of Hg in the maternal sera, cord sera and breast milk plasma of pregnant women using skin lightening creams compared with the control. No statistical significant differences were observed when Hg levels in the maternal sera (0.35 ± 0.06 μ g/dl), cord blood sera (0.36 ± 0.07 μ g/dl) and breast milk plasma of users of skin lightening creams when compared with levels of Hg in the maternal sera (0.36 ± 0.09 μ g/dl), cord blood sera (0.35 ± 0.08 μ g/dl) and breast milk plasma (0.38 ± 0.07 μ g/dl) of non users of skin lightening creams.

Table 4 presents the Mean Hg levels in maternal sera, cord blood sera and breast milk plasma of users of hydroquinone containing skin lightening

Table 1: The levels ($\bar{x} \pm SD$) of IgA, IgG and IgM in the maternal sera, cord blood sera and breast milk plasma of pregnant women using skin lightening creams compared with controls

Parameters	Pregnant women using skin lightening creams (n=30)	Controls (n=30)	t- values	P- values
Maternal IgA (mg/dl)	240.02±86.63	236.87±59.63	0.150	0.882
Cord IgA (mg/dl)	252.56±105.16	238.57±37.06	0.546	0.587
Breast Milk IgA (mg/dl)	236.55±97.81	234.74±79.57	0.072	0.943
Maternal IgG (mg/dl)	1102.87±43.46	697.14±175.50	6.76	0.000*
Cord IgG (mg/dl)	1123.49±208.35	702.15±215.03	7.04	0.000*
Breast Milk IgG (mg/dl)	1056.36±03.42	690.87±234.18	5.89	0.000*
Maternal IgM (mg/dl)	221.36±34.59	185.10±46.59	3.12	0.003*
Cord IgM (mg/dl)	229.78±50.33	186.43±57.09	2.85	0.006*
Breast Milk IgM (mg/dl)	215.56±46.73	183.44±62.18	2.07	0.044*

*Statistically significant.

Table 2: The levels ($\bar{x} \pm SD$) of Ig classes (IgA, IgG and IgM) in maternal sera, cord sera and breast milk plasma of users of hydroquinone containing skin lightening creams compared with the levels in users of non – hydroquinone containing creams

Parameters	Users of hydroquinone containing creams (n=14)	Users of non-hydroquinone containing creams (n=16)	t-values	p-values
Maternal IgA (mg/dl)	246.08±90.30	253.39±78.02	0.194	0.848
Cord IgA (mg/dl)	256.21±111.91	264.74±86.16	0.190	0.851
Breast Milk IgA (mg/dl)	244.07±104.08	260.54±78.98	0.379	0.709
Maternal IgG (mg/dl)	1093.68±219.21	1067.80±294.78	-0.231	0.820
Cord IgG (mg/dl)	1093.64±171.80	1092.79±247.25	0.190	0.851
Breast Milk IgG (mg/dl)	1047.30±156.13	1045.33±288.43	0.379	0.709
Maternal IgM (mg/dl)	223.80±35.05	225.47±30.04	0.115	0.910
Cord IgM (mg/dl)	229.17±55.49	233.62±32.33	0.214	0.833
Breast Milk IgM (mg/dl)	218.78±49.65	221.41±35.11	0.136	0.894

Table 3: The levels ($\bar{x} \pm SD$) of Hg in the maternal sera, cord sera and breast milk plasma of pregnant women using skin lightening creams compared with the controls

Parameters	Test (n=30)	Controls (n=30)	t-values	p-values
Maternal Hg ($\mu\text{g}/\text{dl}$)	0.35 \pm 0.06	0.36 \pm 0.09	0.982	0.331
Cord Hg ($\mu\text{g}/\text{dl}$)	0.36 \pm 0.07	0.35 \pm 0.08	0.439	0.663
Breast Milk Hg ($\mu\text{g}/\text{dl}$)	0.35 \pm 0.08	0.38 \pm 0.07	1.721	0.920

Table 4: Mean Hg levels in maternal sera, cord blood sera and breast milk plasma of users of hydroquinone containing skin lightening creams compared with the levels in users of non – hydroquinone containing creams.

Parameters	Users of hydroquinone containing creams (n=14)	Users of non-hydroquinone containing creams (n=16)	t-values	p-values
Maternal Hg ($\mu\text{g}/\text{dl}$)	0.37 \pm 0.05	0.32 \pm 0.05	2.181	0.042*
Cord Hg ($\mu\text{g}/\text{dl}$)	0.38 \pm 0.06	0.36 \pm 0.05	0.861	0.400
Breast Milk Hg ($\mu\text{g}/\text{dl}$)	0.35 \pm 0.06	0.35 \pm 0.10	0.236	0.816

*Statistically significant.

creams compared with the levels in users of non-hydroquinone containing creams. There was no statistical significant difference between cord plasma Hg ($0.38 \pm 0.06 \mu\text{g}/\text{dl}$) and breast milk Hg ($0.35 \pm 0.06 \mu\text{g}/\text{dl}$) of users of hydroquinone containing skin lightening creams when compared with levels in cord blood sera ($0.36 \pm 0.05 \mu\text{g}/\text{dl}$) and breast milk plasma ($0.35 \pm 0.10 \mu\text{g}/\text{dl}$) of users of non-hydroquinone containing skin lightening creams but statistical significant difference existed between the levels of Hg in maternal sera ($0.37 \pm 0.05 \mu\text{g}/\text{dl}$) of users of hydroquinone containing skin lightening creams when compared with the levels of Hg ($0.32 \pm 0.05 \mu\text{g}/\text{dl}$) in users of non-hydroquinone containing creams.

Table 5 presents the correlation between levels of IgA, IgG and IgM with Hg levels in the maternal sera, cord sera and breast milk plasma of the pregnant women using skin lightening creams. While there were positive correlations between maternal IgA with maternal Hg ($r = 0.584$), maternal IgM with maternal Hg ($r = 0.567$) and negative correlation between cord IgG with cord Hg ($r = -0.518$), no correlation existed between cord IgA with cord Hg ($r = 0.051$), breast milk IgA with breast milk Hg ($r = 0.040$), maternal IgG with maternal Hg ($r = -0.348$), breast milk IgG with breast milk Hg ($r = -0.332$), cord IgM with cord Hg ($r = -0.126$) and breast milk IgM with breast milk Hg ($r = -0.211$).

DISCUSSION

Mercury and hydroquinone are the two most common active ingredients in most skin lightening creams. Numerous potentially life-threatening consequences of these agents have been identified to include skin lesions, epidermal atrophy (thinning of the skin), exogenous ochronosis, eczema, bacterial and

Table 5: Correlation of levels of IgA, IgG, IgM with Hg levels in the maternal sera, cord sera and breast milk plasma of pregnant women using skin lightening creams

Correlation parameter	Subjects (n=30)	
	r	p
Maternal IgA Vs Maternal Hg	0.584	0.002*
Maternal IgG Vs Maternal Hg	-0.348	0.088
Maternal IgM Vs Maternal Hg	0.567	0.003*
Cord IgA Vs Cord Hg	0.051	0.807
Cord IgG Vs Cord Hg	-0.518	0.008*
Cord IgM Vs Cord Hg	-0.126	0.549
Breast Milk IgA Vs Breast Milk Hg	0.040	0.851
Breast Milk IgG Vs Breast Milk Hg	-0.332	0.059
Breast Milk IgM Vs Breast Milk Hg	-0.211	0.311

*Statistically significant.

fungal infections, dermatitis, scabies, warts, acne, sun damage and body odour [10]. Long term use of products containing those agents can lead to fragile skin, poor wound healing, scarring and the need for corrective surgery [2]. Other more serious health risks include hypertension, diabetes, infertility, leukaemia (blood cancer), skin cancer, foetal toxicity (foetal poisoning), immunosuppression (suppression of a healthy immune response), renal and liver impairment and failure, Cushing's syndrome (hormone disorder), insomnia, memory loss, tremors, speech and hearing impairment [11]. Loss of innate functions of skin bleaching cream users was reported by [5], however, there was no report on the levels of Ig classes or Hg levels on maternal sera, cord sera Hg and breast milk plasma of users of hydroquinone containing skin lightening creams compared with users of non-hydroquinone containing creams.

Worthy of note is the fact that all the creams used by the subjects have Hg levels above a cosmetic reference value of $0.01 \mu\text{g}/\text{dl}$ recommended by W.H.O [12]. There was no statistically significant difference between the cord sera Hg and breast milk plasma Hg of users of

hydroquinone containing skin lightening creams when compared with users of non-hydroquinone containing creams. This might be related to equal exposure to environmental Hg from sources such as mercury vapor from broken thermometer, medical equipment, valves, improperly disposed batteries or eating fishes from Hg contaminated water [12,13,18].

However, significant increase observed in maternal Hg of users of hydroquinone containing skin lightening creams when compared with users of non-hydroquinone containing creams, could be that environmental Hg absorption through the skin is aggravated by hydroquinone in the skin lightening cream users.

Statistical significant differences were observed between maternal serum IgG, cord IgG, breast milk IgG, maternal IgM, cord IgM and breast milk IgM of the pregnant women using skin lightening creams when compared with the control. Higher levels of IgG in pregnant women using skin lightening creams could be as a result of chronic stimulation of immune system by long term use of skin lightening creams by the subjects because IgM is predominantly produced during acute immune responses as shown in table 1 while IgG is predominantly produced during chronic immune response [14]. No statistically significant differences were observed between the levels of maternal IgA, cord IgA, and breast milk IgA of the users of hydroquinone containing skin lightening creams when compared with users of non-hydroquinone containing skin lightening creams. This could be due to the fact that IgA is commonly increased in cases of liver cirrhosis, autoimmune disorder such as rheumatoid arthritis and immunologic deficiency state, and infections of respiratory, reproductive and digestive tracts [15]. There was no statistical significant difference observed between the levels of maternal IgG, cord IgG, and breast milk IgG of the users of hydroquinone containing skin lightening creams when compared with users of non-hydroquinone containing skin lightening creams. There was no report available on the link between hydroquinone containing skin lightening creams and the levels of IgG. No statistical significant difference was observed between the levels of maternal IgM, cord IgM, and breast milk IgM of the users of hydroquinone containing skin lightening creams when compared with users of non-hydroquinone containing creams. It is possible that hydroquinone has no degradative effect on the levels of IgM, accounting for IgM stability in both groups. No statistical significant differences were observed between the levels of maternal mercury, cord

mercury, and breast milk mercury of the users of skin lightening creams when compared with the controls.

Despite the fact that Hg levels in the skin lightening creams used by the test participants contained Hg levels above cosmetic reference value of $0.01\mu\text{g}/\text{dl}$ as recommended by WHO [11]. It might be hypothesized that there are intricate mechanisms in users of these creams that reduces their blood Hg levels. This may include N-acetyl cysteine which is the derivative of naturally occurring amino acid (Cysteine). Cysteine is an excellent source of sulfhydryl (-SH) groups which stimulates synthesis of reduced glutathione (GSH). GSH binds mercury for easy excretion. Eggs and garlic are sulfur-containing nutrients and also rich in sulfhydryl (-SH) group which complex with mercury. Also, eggs and whole grains are rich in Se which protects against mercury toxicity and alters the distribution of mercury in tissues by binding of Hg-Se complexes to proteins, hence promoting mercury excretion [16,19,20].

While positive correlation was observed between maternal IgA with maternal mercury, maternal IgM with maternal mercury and negative correlation was observed between cord IgG with cord Hg. The positive correlation between maternal IgA and maternal mercury of the pregnant women using skin lightening creams could be as a result of localized or systemic infection resulting from chronic exposure to mercury contained in the skin lightening creams used by the subjects as it has been reported that constant exposure to mercury particularly through the use of skin lightening creams, can lead to increased susceptibility of users to localized or systemic infections [5,17]. Negative correlation between cord IgG with cord Hg indicated that the higher the mercury level, the lower the cord IgG level in the fetus. The implication is that IgG levels will be reduced in the fetus if skin lightening practice is not discontinued by the users as it has been found that pregnant mothers using skin lightening creams had smaller placenta and their children born at low birth weights, low cortisol levels, and higher rates of birth defects as a result of mercury exposure [7]. Also, reduced innate immunity of the skin as a result of removal of top (epidermal layer) of the skin, reduced melanin and direct effect of sun rays might cause higher susceptibility to infections in skin lightening cream users.

In conclusion, raised IgG and IgM in mothers and babies of chronic skin lightening creams users could

be a result of polyclonal B lymphocyte activation which could lead to autoimmune disease later in life. Also, Hg but not hydroquinone had negative effect on babies' immunoglobulin levels. There is need for public awareness programs to enlighten the populace about the danger involved in the use of skin lightening creams particularly among pregnant women. Numerous potentially life-threatening consequences especially autoimmune disorder awaits any long term user of skin lightening cream particularly pregnant mothers.

There is need for public awareness programs to enlighten the populace about the danger involved in the long term use of skin lightening creams particularly to pregnant women.

Statement of Human and Animal Rights

All procedures followed were in accordance with the ethical standards of the responsible committee on human experimentation (institutional and national) and with the Helsinki Declaration of 1975, as revised in 2008.

Statement of Informed Consent

Informed consent was obtained from all patients for being included in the study.

REFERENCES

1. Olumide YM. Use of skin lightening creams. *Brit Med J*. 2010;341:6102.
2. Benn EK, Alexis A, Mohamed N, Wang YH, Khan IA, Liu B. Skin bleaching and Dermatologic Health of African and Afro-Caribbean populations in the US: New directions for methodologically rigorous, multidisciplinary, and culturally sensitive research. *Dermatol Ther (Heidelb)*. 2016;6:453-459.
3. Ladizinski B, Mistry N, Kundu R. Wide spread use of toxic skin lightening compounds: medical and psychosocial aspects. *Dermatol Clin J*. 2011;29:111-23.
4. Traore A, Kadaba JC, Niamba P, Barro F, Ouedraogo L. Use of cutaneous de-pigmenting products by women in two towns in Burkina Faso: epidemiologic data, motivations, products and side effects. *Int J Dermatol*. 2005;44 suppl 1:30-2.
5. Arinola OG, Afolabi KA. and Olopade CO. Immunological skin tests and hematological indices in Nigeria users of skin lightening creams. *Egyptian Dermatol Online J*. 2012;7:3.
6. Mohammed T, Mohammed E, Bascombe S. The evaluation of total mercury and arsenic in skin bleaching creams commonly used in Trinidad and Tobago and their potential risk to the people of the Caribbean. *J Public Health Res*. 2017;6:1097.
7. Bahari M, Alizadeh Oskoei P, Savadi Oskoei S, Pouralibaba F, Morsali Ahari A. Mercury release of amalgams with various silver contents after exposure to bleaching agent. *J Dent Res Dent Clin Dent Prospects*. 2016;10:118-23.
8. Sendrasoa FA, Ranaivo IM, Andrianarison M, Raharolahy O, Razanakoto NH, Ramarozatovo LS, et al. Misuse of topical corticosteroids for cosmetic purpose in Antananarivo, Madagascar. *Biomed Res Int*. 2017;2017:9637083.
9. Olayanju OA, Rahamon SK, Arinola OG. Salivary immunoglobulin classes in Nigerian cigarette smokers: Indication for increased risk of oral diseases. *Dent Res J*. 2012;9:531-4.
10. Alobaidi AH, Hamad ES, Kudair KA, Alsamarai AM. Formulation of hypopigmentation cream and evaluation of its effect on skin pigment. Part I: Formulation of the product. *Our Dermatol Online*. 2014;5:9-13.
11. Taylor SC. Skin of color: biology, structure, function, and implications for dermatologic disease. *J Amer Acad Dermatol*. 2002;46:S41-S62.
12. WHO. 2003. Elemental Mercury and Inorganic Mercury Compounds. World Health Organization and International Program on Chemical Safety, Geneva.
13. Michalek IM, Benn EKI, Dos Santos FLC, Gordon S, Wen C, Liu B. A systematic review of global legal regulations on the permissible level of heavy metals in cosmetics with particular emphasis on skin lightening products. *Environ Res*. 2018;170:187-93.
14. Azarsiz E, Karaca NE, Gunaydin NC, Gulez N, Ozturk C, Aksu G, et al. Do elevated serum IgM levels have to be included in probable diagnosis criteria of patients with ataxia-telangiectasia? *Int J Immunopathol Pharmacol*. 2014;27:421-7.
15. Fagarasan S, Honjo T. Intestinal IgA synthesis: regulation of front-line body defences. *Nature Reviews. Immunology*. 2003;3:63-72.
16. Khalaf AA, Ahmed W, Moselhy WA, Abdel-Halim BR, Ibrahim MA. Protective effects of selenium and nano-selenium on bisphenol-induced reproductive toxicity in male rats. *Hum Exp Toxicol*. 2018;960327118816134.
17. Dioussé P, Ndiaye M, Dione H, Bammo M, Sow O, Seck F, et al. Bacterial dermohypodermatitis at the Thies Regional Hospital, Senegal (West Africa): A retrospective study of 425 cases. *Our Dermatol Online*. 2017;8:233-6.
18. Kisiel K, Dębowska R, Dżilińska K, Radzikowska A, Pasikowska-Piwko M, Rogiewicz K, et al. New H₂O₂ dermocosmetic in acne skin care. *Our Dermatol Online*. 2018;9(e):e3.
19. Huang H, Wang Y, An Y, Tian Y, Li S, Teng X. Selenium for the mitigation of toxicity induced by lead in chicken testes through regulating mRNA expressions of HSPs and selenoproteins. *Environ Sci Pollut Res Int*. 2017;24:14312-21.
20. Abreu Velez AM, Yepes Naranjo MM, Avila IC, Londoño ML, Googe Jr. PB, Velásquez Velez JE, et al. Tissue inhibitor of metalloproteinase 1, matrix metalloproteinase 9, α 1-antitrypsin, metallothionein and urokinase type plasminogen activator receptor in skin biopsies from patients affected by autoimmune blistering diseases. *Our Dermatol Online*. 2013;4:275-80.

Copyright by Agatha Obiageli Nwosu, et al. This is an open-access article distributed under the terms of the Creative Commons Attribution License, which permits unrestricted use, distribution, and reproduction in any medium, provided the original author and source are credited.
Source of Support: Nil, **Conflict of Interest:** None declared.

Perception of Dermatology by Medical Students in the Faculty of Health Sciences, University of Lomé (Togo)

Julienne Noudé Teclessou¹, Bayaki Saka¹, Séfaco Abla Akakpo¹, Abas Mouhari-Toure², Kassang Panawè³, Koussake Kombate¹, Palokinam Pitche¹

¹Department of Dermatology, CHU Lomé, Faculty of Health Sciences University of Lomé, Lomé, Togo, ²Department of Dermatology, CHU Kara, Faculty of Health Sciences Kara University, Kara, Togo, ³Department of Dermatology, CHU Lomé, Lomé, Togo

Corresponding author: Dr. Julienne Noudé Teclessou, E-mail: tjulie06@yahoo.fr

ABSTRACT

Objective: The aim of our study was to study the perception of dermatology by medical students in the Faculty of Health Sciences of the University of Lomé and their influencing factors. **Method:** This is an opinion poll conducted from June 1 to June 30, 2018, within medical students (Grades 5, 6, and 7) of the university's Faculty of Health Sciences. **Results:** We surveyed 176 medical students, 76 (38.8%) in grade 7 and 61 (31.1%) in grade 6. Among them, only 29.2% had done internships in dermatology and 37.2% said they were interested in dermatology. Dermatology is a specialty of intermediate difficulty according to 79.6% of the students and 63.8% of the students considered their level of practical knowledge in dermatology weak. More than half (56.6%) of students felt they were able to deal with common dermatoses during the course of their general practice and there was a significant association between students doing their traineeship in dermatology and the possibility of taking care of common dermatoses ($p = 0.001$). **Conclusion:** Medical students at the University of Lomé have little interest in dermatology. But the completion of an internship in dermatology improves this level of perception. This study highlights the importance of internships in dermatology to arouse the students' passion for the specialty.

Key words: Perception; Dermatology; Students; Togo

How to cite this article: Teclessou JN, Saka B, Akakpo SA, Mouhari-Toure A, Panawè K, Kombate K, Pitche P. Perception of Dermatology by Medical Students in the Faculty of Health Sciences, University of Lomé (Togo). Our Dermatol Online. 2019;10(2):138-141.

Submission: 31.12.2018; **Acceptance:** 16.02.2019

DOI: 10.7241/ourd.20192.6

Perception de la dermatologie par les étudiants en médecine de la faculté des sciences de la santé de l'université de Lomé (Togo)

Julienne Noudé Teclessou¹, Bayaki Saka¹, Séfaco Abla Akakpo¹, Abas Mouhari-Toure², Kassang Panawè³, Koussake Kombate¹, Palokinam Pitche¹

¹Department of Dermatology, CHU Lomé, Faculty of Health Sciences University of Lomé, Lomé, Togo, ²Department of Dermatology, CHU Kara, Faculty of Health Sciences Kara University, Kara, Togo, ³Department of Dermatology, CHU Lomé, Lomé, Togo

Corresponding author: Dr. Julienne Noudé Teclessou, E-mail: tjulie06@yahoo.fr

RÉSUMÉ

Objectif: Le but de notre étude était d'étudier la perception de la dermatologie par les étudiants en médecine de la faculté des sciences de la santé de l'université de Lomé et les facteurs qui l'influencent. **Méthode:** Il s'agit d'une enquête d'opinion réalisée du 1er au 30 juin 2018 près des étudiants en médecine (5^{ème}, 6^{ème} et 7^{ème} année) de la faculté des sciences de la santé de l'université. **Résultats:** Nous avons enquêté 176 étudiants en médecine dont 76 (38,8%) de 7^{ème} année et 61 (31,1%) de 6^{ème} année. Parmi eux, seuls 29,2% avaient fait des stages en dermatologie et 37,2% se disaient intéressés par la dermatologie. La dermatologie est une spécialité de difficulté intermédiaire selon 79,6% des étudiants et 63,8% des étudiants estimaient leur niveau de connaissance pratique en dermatologie faible. Plus de la moitié (56,6%) des étudiants s'estimaient capable de prendre en charge les dermatoses courantes au cours de l'exercice de leur fonction de médecine générale et on notait une association significative entre les étudiants ayant fait leur stage en dermatologie et la possibilité de prendre en charge les dermatoses courantes ($p = 0,001$). **Conclusion:** Les étudiants en médecine à l'Université de Lomé s'intéressent peu à la dermatologie. Mais la réalisation d'un stage en dermatologie améliore ce niveau de perception. Cette étude relève donc l'importance des stages en dermatologie afin de susciter la passion des étudiants pour la spécialité.

Mots clés: Perception; Dermatologie; Étudiants; Togo

INTRODUCTION

La dermatologie est une spécialité médicale qui prend en charge les affections de la peau, des muqueuses qui lui sont rattachées et les phanères. C'est une spécialité parfois au premier plan de la sollicitation du patient à cause du caractère affichant ou de la chronicité de certaines affections cutanées. Elle fait souvent l'objet de nombreuses représentations tant par les populations [1,2], que par les étudiants en médecine.

Le but de notre étude était d'évaluer la perception de la dermatologie par les étudiants en médecine de la faculté des sciences de la santé de l'université de Lomé et les facteurs qui l'influencent.

MÉTHODE

Il s'agit d'une enquête d'opinion menée du 1er au 30 juin 2018 à la faculté des sciences de santé (FSS) de l'université de Lomé. Les étudiants de 5^{ème}, 6^{ème} et 7^{ème} année de médecine de la FSS ont été inclus dans l'étude. Nous avons choisi les étudiants en 5^{ème}, 6^{ème} et 7^{ème} année car au Togo, les cours théoriques de dermatologie sont enseignés en 5^{ème} année de médecine. Et les étudiants en médecine sont ensuite programmés pour les stages en dermatologie et dans les autres spécialités médicales de façon aléatoire. Toutefois, les étudiants peuvent cependant faire des stages de façon volontaire dans les différents services de leur choix pendant les congés. Un questionnaire anonyme comportant les

How to cite this article: Teclessou JN, Saka B, Akakpo SA, Mouhari-Toure A, Panawè K, Kombate K, Pitche P. Perception de la dermatologie par les étudiants en médecine de la faculté des sciences de la santé de l'université de Lomé (Togo). Our Dermatol Online. 2019;10(2):138-141.

Submission: 31.12.2018; **Acceptance:** 16.02.2019

DOI: 10.7241/ourd.20192.6

données sociodémographiques, le passage ou non dans les services de dermatologie dans le cadre des stages, l'intérêt pour la dermatologie, l'estimation du niveau de connaissances théorique et pratique a été adressé aux étudiants. L'accord des autorités de la FSS a été obtenu de même que le consentement éclairé des étudiants. L'analyse des données a été réalisée avec le logiciel épi-info7. Le seuil de significativité a été fixé à 5%.

RÉSULTATS

Au total 196 étudiants ont participé à l'enquête dont 76 (38,8%) de 7^{ème} année et 61 (31,1%) de 6^{ème} année. L'âge moyen des étudiants était de 25,1 ans \pm 1,6 (extrêmes: 22 et 29 ans) et la sex-ratio de 1,9.

Sur les 196 étudiants, seuls 57 (29,2%) avaient fait des stages dans un service de dermatologie. Il s'agit de stage réglementaire dans le cadre de leur cursus de formation. La durée moyenne des stages était de 6,9 \pm 2,3 semaines (extrêmes: 4 à 10 semaines). Parmi les 57 étudiants ayant fait leur stage dans le service de dermatologie, 7 (12,3%) qualifiaient la durée du stage de largement suffisante, 29 (50,9%) la qualifiaient de suffisante et 21 (36,8%) la qualifiaient d'insuffisante. La majorité 52 (91,2%) des 57 étudiants ayant fait des stages dans le service de dermatologie qualifiaient ce stage de satisfaisant.

Seuls 73 (37,2%) étudiants interrogés se disaient intéressés par la dermatologie. La majorité (70,2%) des étudiants intéressés par la dermatologie avaient déjà fait des stages dans le service ($p=0,0003$).

La principale raison évoquée par les 123 étudiants non intéressés par la dermatologie était des difficultés à diagnostiquer les pathologies dermatologiques dans 90,2% des cas (Tableau 1). Les autres raisons évoquées étaient la dermatologie est une spécialité non passionnante (54,6% des cas), la dermatologie est ennuyeuse (3,1% des cas), les lésions dermatologiques sont effrayantes (2,5% des cas).

La dermatologie est une spécialité de difficulté intermédiaire selon 79,6% des étudiants. La majorité 121 (61,7%) des étudiants estimaient leur niveau de connaissances théoriques en dermatologie moyen alors que le niveau de connaissances pratiques était estimé faible par 63,8% d'entre eux (Tableau 1). Parmi les 125 étudiants estimant leur niveau de connaissances pratiques faible en dermatologie, 101 n'y avaient jamais fait de stage ($p = 0,00001$).

Tableau 1: Facteurs influençant la perception de la dermatologie par les étudiants en médecine à l'université de Lomé

Questions	N	%
Intéressement à la dermatologie		
Oui	73	37,2
Non	123	62,8
Raisons du non intéressement (N=123)		
Difficultés diagnostics	111	90,2
Difficultés à reconnaître les lésions élémentaires	97	78,9
Niveau de connaissances théoriques		
Bon	10	5,1
Moyen	121	61,7
Faible	65	33,2
Niveau de connaissances pratiques		
Bon	2	1,0
Moyen	69	35,2
Faible	125	63,8
Perception du niveau de difficulté de la dermatologie		
Facile	19	9,7
De difficulté intermédiaire	156	79,6
Difficile	22	11,2
Capacité à prendre en charge des pathologies dermatologiques courantes à la fin des études		
Oui	111	56,6
Non	85	43,37

Les spécialités envisagées par les étudiants interrogés étaient principalement la gynécologie 28 (14,3%), la cardiologie 23 (11,7%), la chirurgie 21 (10,7%), la radiologie 16 (8,2%), l'ophtalmologie 15 (7,7%), et la pédiatrie 14 (7,1%). Seul 2 (1,0%) étudiants envisageaient la dermatologie comme spécialité à faire.

DISCUSSION

La principale limite de notre étude est la fiabilité et la crédibilité des informations fournies par les étudiants interrogés. La dermatologie constitue une spécialité médicale mal aimée par les étudiants en médecine puisque près des deux tiers (62,3%) des étudiants interrogés dans notre étude n'étaient pas intéressés par cette spécialité. Nos résultats sont comparables à ceux rapportés au Maroc où seul 25,8% des étudiants interrogés étaient intéressés par la dermatologie [3]. Les difficultés à reconnaître les lésions élémentaires 97 (78,9%), les difficultés diagnostics 111 (90,2%), et le fait que la dermatologie ne soit pas passionnante 83 (67,5%) étaient les principales raisons évoquées. L'organisation du stage des étudiants en médecine ne permettant pas à tous de faire des stages dans les services de dermatologie peut expliquer ce désamour pour la spécialité puisque 56,1% des étudiants ayant fait des stages en dermatologie se disaient intéressés par la spécialité.

Plus de la moitié (63,8%) estimaient leur niveau de connaissances pratiques faible et on notait une association significative entre le faible niveau de connaissances pratiques et la non réalisation de stage en dermatologie. En effet, la dermatologie étant une spécialité ou l'inspection demeure un temps capital dans l'examen clinique, la non réalisation de stage dans cette spécialité au cours du cursus de formation donne l'impression aux étudiants que la dermatologie est une spécialité abstraite, ce qui explique le mauvais niveau de connaissances pratiques. Les stages pratiques sont importants afin de rendre les connaissances théoriques moins abstraites et plus intéressantes [4,5].

Bien que la majorité (63,8%) des étudiants estimaient leur niveau de connaissances pratiques faible, plus de la moitié (56,6%) s'estimaient capable de prendre en charge les dermatoses courantes au cours de leur exercice de médecine générale. Notre étude confirme le fait que la sémiologie clinique, d'imagerie et de biologie, peut commencer à s'apprendre à la faculté, mais elle ne deviendra performante que lorsqu'elle sera utilisée au contact du patient [6,7].

La gynécologie et la cardiologie étaient les spécialités les plus envisagées par les étudiants interrogés; et seul 1% des étudiants envisageaient de faire la dermatologie. Plusieurs facteurs dont l'intérêt pour la spécialité, l'impact de la formation et de l'enseignement lors des stages hospitaliers pourraient influencer le choix de la spécialité [8,9].

Bien que 37,2% des étudiants soient intéressés par la dermatologie, seul 1% envisageaient la dermatologie plus tard. La dermatologie reste une spécialité qui suscite peu de vocation au Togo contrairement à l'Afrique du Nord où elle est une spécialité de choix chez plus de 5% des étudiants en médecine [10].

CONCLUSION

Cette étude nous permet de conclure à l'importance des stages dans le service de dermatologie afin de susciter la passion des étudiants pour la spécialité

et de leur permettre de bien prendre en charge des dermatoses courantes au cours de leur exercice.

Statement of Human and Animal Rights

All procedures followed were in accordance with the ethical standards of the responsible committee on human experimentation (institutional and national) and with the Helsinki Declaration of 1975, as revised in 2008.

Statement of Informed Consent

Informed consent was obtained from all patients for being included in the study.

REFERENCES

1. Pailler JJ. De quelques représentations culturelles de la peau. *Cairn*. 2006;29:159-69.
2. Kawshar T, Rajesh J. Sociodemographic factors and their association to prevalence of skin diseases among adolescents. *Our Dermatol Online*. 2013;4:281-6.
3. Ebongo Aboutou CN, Hassam B. Perception de la dermatologie par les étudiants en médecine. *Ann Dermato-Vénérol*. 2017;S243.
4. Laniauskaite I, Ožalinskaite A, Strupaite R, Bylaite M. Skin cancer knowledge, attitude and behavior towards sun exposure among young adults in Lithuania. *Our Dermatol Online*. 2011;2:189-95.
5. Smith N, Finn M, Segars L, Burns E, Peterson J, Sutton A, et al. Melanoma and medical education: knowledge and sun safety practices amongst medical students. *Our Dermatol Online*. 2018;9:11-4.
6. Guiraud Chaumeil B. La formation d'un médecin idéal. *Presse Méd*. 2009;38:863-8.
7. Finn M, Smith N, Segars L, Burns E, Peterson J, Sutton A, et al. Melanoma and medical education: student's perceptions of skin cancer screening in three medical schools. *Our Dermatol Online*. 2018;9:123-7.
8. Sonia Gaucher S, Thabut D. L'enseignement et l'enseignant influencent le choix de la spécialité médicale. *Enquête auprès de 207 étudiants*. *Presse Med*. 2013;42:e89-e95.
9. Hoskin ER, Johnsen DC, Saksena Y, Horvath Z, de Peralta T, Fleisher N, et al. Dental Educators' Perceptions of Educational Learning Domains. *J Dent Educ*. 2019;83:79-87.
10. Matrane A, Serhier Z, Bennani Othmani M. Les critères de choix de la spécialité des médecins résidents de la faculté de médecine et de pharmacie de Marrakech (Maroc) *Péd Méd*. 2012;13:171-81.

Copyright by Julienne Noudé Teclessou, et al. This is an open-access article distributed under the terms of the Creative Commons Attribution License, which permits unrestricted use, distribution, and reproduction in any medium, provided the original author and source are credited.
Source of Support: Nil, Conflict of Interest: None declared.

Topical corticosteroid abuse – a prospective clinico-epidemiological study

Mrinal Gupta

Department of Dermatology, Treatwell Skin Centre, Jammu and Kashmir, India

Corresponding author: Dr. Mrinal Gupta, E-mail: drmrinalgupta@yahoo.com

ABSTRACT

Background: Misuse of topical corticosteroids (TCs) is a rampant problem in India owing to the easy availability of topical corticosteroids as over the counter preparations. TCs are being widely misused for a wide variety of skin ailments ranging from their use as skin whitening creams to infections like dermatophytoses, acne and even as daily use moisturizing creams. This misuse of TCs can lead to a large number of cutaneous and systemic adverse effects.

Aims and objectives: This study was carried out to study the prevalence and patterns of self use of TCs by the general population. **Materials and methods:** This was a prospective questionnaire based study carried out over a period of one year in our centre in which the patients were questioned and assessed for misuse of TCs in terms of indication, frequency, duration and source of recommendation. **Results:** A total of 200 patients (M: F 56:144) were included in our study. The age range of patients varied from 18 to 69 years with a mean age of 31.35 years. The most common indication for TCs use in our study was fungal infections (33%), facial pigmentation (26%) and acne (21%), while the most commonly abused corticosteroids were clobetasol (31%), betamethasone (28%) and mometasone (26%). The most common cutaneous adverse effects to TCs seen in our study were tinea incognito (24%), steroid acne (16%), steroid rosacea (11%), hypertrichosis (6%) and striae (4%). **Conclusion:** TCs misuse in patients is quite common, which can lead to serious adverse effects. Generating awareness among the general population is necessary to curb the menace.

Key words: Topical corticosteroids; Steroid abuse; Steroid rosacea; Steroid acne; Tinea incognito

INTRODUCTION

Topical corticosteroids (TCs) are one of the most commonly used preparations in dermatology practice. Their rapid anti-inflammatory, immunosuppressive and anti-pruritic activity has made them the drug of choice for a large number of dermatoses [1]. Apart from the well documented uses of TCs, they can also cause a wide array of adverse effects if used indiscriminately or for long duration without supervision which include steroid rosacea, acneiform eruption, hypertrichosis [2]. TCs misuse is a common problem in our country owing to their easy availability as over the counter medication and preparations and lack of awareness among the general population. TCs are commonly being used as fairness and anti acne medications by the general population without any dermatological consultation which has led to a significant number of patients

presenting with cutaneous adverse effects of TCs to the dermatologists [2,3].

This study was carried out in a dermatology outpatient centre with the main aims of studying the clinic-epidemiological features of TCs misuse among the general population.

MATERIALS AND METHODS

This was a prospective, questionnaire based study carried out over a period of one year in our centre in which the patients were questioned and assessed for misuse of TCs in terms of indication, frequency, duration and source of recommendation. All the patients who had self-medicated with TCs or had used TCs beyond the prescribed time advised by the dermatologists were included in the study. The patients

How to cite this article: Gupta M. Topical corticosteroid abuse – a prospective clinico-epidemiological study. Our Dermatol Online. 2019;10(2):142-144.

Submission: 29.04.2018; **Acceptance:** 01.07.2018

DOI:10.7241/ourd.20192.7

were assessed regarding the formulation, frequency, duration or indications of TCs use for different skin conditions and the various cutaneous adverse effects, wherever present, were also noted.

RESULTS

A total of 200 patients (M: F 56:144) were included in our study. The age range of patients varied from 18 to 69 years with a mean age of 31.35 years. Their baseline demographic features are shown in Table 1. The majority, 112 (56%) patients were of 20–40 years age group and 61% (n=122) patients belonged to a rural background and 31% (n=62) were illiterate or high school dropouts. The most common indications of TCs use in our study population were fungal infections in 66 patients (33%), facial pigmentation in 52 (26%) and acne in 42 patients (21%) (Table 2), while the most commonly abused corticosteroids were clobetasol (31%), betamethasone (28%) and mometasone (26%) (Table 3). The duration of TCs use varied from three days to eight years in our study group whereas the frequency of use varied from thrice a week to thrice a day.

The majority, 84 (42%) patients were using topical corticosteroids on advice of pharmacists or paramedical personnel; 48 (24%) were advised by friends and relatives, 21 (10.5%) were advised by beauty parlors and beauticians. Thirty one patients (15.5%) were using the TCs advised by the dermatologists, but had been using them for a period beyond the advised time frame.

In our study group, 87 patients (43.5%) showed cutaneous adverse effects of TCs use, the most common ones being tinea incognito in 48 patients (24%), steroid acne in 32 (16%), steroid rosacea in 22 (11%), hypertrichosis in 12 (6%) and striae in 8 patients (4%).

The lack of awareness among the population can be gauged from the fact that only 16% patients (n=32) were aware of the adverse effects of TCs misuse.

DISCUSSION

The dermatological therapy underwent a sea change with the introduction of Hydrocortisone in 1952, which was followed by the development of a large variety of more potent topical corticosteroids. Owing to their potent anti-inflammatory, anti-proliferative,

Table 1: Baseline characteristics of the study population

Baseline characteristics of the patients studied	Total number of patients (n=200)
Gender (male:female)	56:144
Age (years)	
Range (mean)	18-69 (31.35)
<20 yrs	12 (6%)
20-39 yrs	112 (56%)
40-59 yrs	48 (24%)
>60 yrs	28 (14%)
Social Background	
Urban	78 (39%)
Rural	122 (61%)
Education Status	
Illiterate/school dropout/below high school	62 (31%)
High school or above	138 (69%)

Table 2 : Indications of corticosteroid use

Indications of corticosteroid use	Number of patients (%)
Fungal infections	66 (33)
Pigmentation	52 (26)
Acne	42 (21)
Bacterial/viral infections	11 (10.5)
Others	29 (14.5)

Table 3 : Various corticosteroids used by the patients

Corticosteroid used	Number of patients (%)
Clobetasol	62 (31)
Betamethasone	56 (28)
Mometasone	52 (26)
Beclomethasone	12 (6)
Fluticasone	8 (4)
Halobetasol	5 (2.5)
Fluocinolone	3 (1.5)
Hydrocortisone	2 (1)

immunosuppressive, anti-pruritic and atrophogenic effect on the skin, TCs have become the most commonly used drug for various hyperproliferative, inflammatory, and immunologic disorders of the skin [1]. But these properties of TCs have proven to be a double-edged sword as they provide rapid symptomatic relief in a large number of dermatoses, owing to which, they are commonly being sold over-the-counter and used by the patients irrespective of the underlying disease. Surprisingly, they are commonly being used as anti-acne and fairness creams by a large number of young patients. Their low cost and easy availability has added to growing menace [2,3].

The problem of TCs abuse has been widely reported from all over the developing world. A study from Iraq reported that 7.9% of our patient attendees in dermatology clinic had misused TCs [4]. In a similar study by Saraswat et al in India, 433 patients misusing TCs were studied. It was observed that the majority were females (n=321) and the most common age group was 21-30 years (36%), which was similar to our study group where the females outnumbered males (M: F 1:2.57) and the most common age group was 20-

40 years (56%) [5]. This demographic feature could be attributed to the increased cosmetic concern in females and exposure to media among this age group. Most of the patients in our study belonged to a rural background which highlights the less availability of dermatologists in the rural setup and the easy availability of TCs and dispensing by the local pharmacists. The most common indications of TCs use in our study population were fungal infections (33%), facial pigmentation (26%) and acne (21%). Surprisingly, TCs are not the first line drugs in any of these dermatoses. This was in concordance with the results of study by Saraswat et al where the most common indications of steroid abuse were face cream/fairness cream/after shave cream (29%), acne (24%), as a lightening agent in melasma (17%) [5]. In a study by Brar et al, acne was the most common indication of steroid use in 68% followed by melasma or skin lightening use in 22% [6]. This aspect can be attributed to the lack of awareness among the general population towards the use of TCs.

The most commonly abused corticosteroids in our study were clobetasol (31%), betamethasone (28%) and mometasone (26%), which are among the most potent of TCs. A significant number of patients (16%, n=32) were using the irrational over-the-counter three or four drug combinations which include a corticosteroid, an antibiotic and an antifungal, while 20% (n=40) were using the variants of Kligman's formula (corticosteroid, hydroquinone, tretinoin) for pigmentation. The inappropriate use of TCs can lead to multiple side effects including atrophy, striae, telangiectasis, purpura, hypopigmentation, acneiform eruptions, rosacea-like perioral and periorbital dermatitis and hypertrichosis and even iatrogenic Cushing's syndrome [5,7-9]. In our study, 43.5% (n=87) patients presented with cutaneous adverse effects of TCs, the most common ones being tinea incognita (24%), steroid acne (16%), steroid rosacea (11%), hypertrichosis (6%) and striae (4%). Similar observations were made by Hariharasubramony et al, who reported acneiform eruptions in 52% patients, followed by hypertrichosis, infections and telangiectasias [10].

Our study had several limitations. The small number of study population and the study being limited to the OPD of a single centre doesn't characterize the whole population in general.

The study reveals the rampant problem of TCs abuse in our setup. The general public and the health care providers at the peripheral levels need to be made aware of the serious adverse effects of inappropriate TCs use and a strict regulation should be brought to control the unauthorized sale of TCs as over the counter preparations without proper prescription by the doctor.

Statement of Human and Animal Rights

All procedures followed were in accordance with the ethical standards of the responsible committee on human experimentation (institutional and national) and with the Helsinki Declaration of 1975, as revised in 2008.

Statement of Informed Consent

Informed consent was obtained from all patients for being included in the study.

REFERENCES

1. Becker DE. Basic and clinical pharmacology of glucocorticosteroids. *Anesth Prog*. 2013;60:25–31.
2. Dey VK. Misuse of topical corticosteroids: A clinical study of adverse effects. *Indian Dermatol Online J*. 2014;5:436–40.
3. Jha AK, Sinha R, Prasad S. Misuse of topical corticosteroids on the face: A cross-sectional study among dermatology outpatients. *Indian Dermatol Online J*. 2016;7:259–63.
4. Al-Dhalimi MA, Aljawahiri N. Misuse of topical corticosteroids: A clinical study from an Iraqi hospital. *East Mediterr Health J*. 2006;12:847–52.
5. Saraswat A, Lahiri K, Chatterjee M, Barua S, Coondoo A, Mittal A, et al. Topical corticosteroid abuse on the face: A prospective, multicenter study of dermatology outpatients. *Indian J Dermatol Venereol Leprol*. 2011;77:160–6.
6. Brar BK, Nidhi K, Brar SK. Topical corticosteroid abuse on face: A clinical, prospective study. *Our Dermatol Online*. 2015;6:407–10.
7. Hengge UR, Ruzicka T, Schwartz RA, Cork MJ. Adverse effects of topical glucocorticosteroids. *J Am Acad Dermatol*. 2006;54:1–15.
8. Inakanti Y, Thimmasarthi VN, Anupama, Kumar S, Nagaraj A, Peddireddy S, et al. Topical corticosteroids: Abuse and Misuse. *Our Dermatol Online*. 2015;6:130–4.
9. Rustowska A, Wilkowska A, Nowicki R. Iatrogenic Cushing syndrome due to topical glucocorticosteroid therapy. *Our Dermatol Online*. 2013;4:503–5.
10. Hariharasubramony A, Sujatha VC, Harikishan Y, Raghunath N, Anagha RB. Topical corticosteroid abuse on the face: a prospective, study on outpatients of dermatology. *Our Dermatol Online*. 2014;5:5–8.

Copyright by Mrinal Gupta, et al. This is an open-access article distributed under the terms of the Creative Commons Attribution License, which permits unrestricted use, distribution, and reproduction in any medium, provided the original author and source are credited.

Source of Support: Nil, Conflict of Interest: None declared.

Case series: Three cases of dermatitis artefacta

Gangadhar Harsha, Jithin Bijina, Anjan Kumar Patra

Department of Dermatology, MVJ Medical College and Research Hospital, Bangalore, India

Corresponding author: Dr. Gangadhar Harsha, E-mail: harshagangadhar5@gmail.com

ABSTRACT

Three cases of dermatitis artefacta are reported for their varied presentation, diagnostic indicators and complex management. A 13 year old young child presented with multiple painful erosions with crusting over face, upper limb, lower limb trunk since 1 month. Histopathology was non specific. A 21 year old man presented with multiple asymptomatic raised lesions on the right forearm since one year. His brother claimed that the individual had initially produced these lesions using burning cigarette ends. A 25 year old medical student presented with multiple reddish lesions over all fingers of his hands and lips. He was depressed, withdrawn, and unwilling to discuss his problems and had interpersonal conflict with his parents. Psychiatric evaluation and follow-up was essential in all cases.

Key words: Dermatitis artefacta; Psychotherapy; Psychocutaneous disorders

INTRODUCTION

Dermatitis artefacta is a factitious disorder leading to deliberately and consciously self inflicted injuries aimed at satisfying unconscious emotional needs; classically, the patient perpetuates the lesions and denies having induced the same. Factitial dermatitis or dermatitis artefacta is a psychocutaneous disorder produced by or perpetuated by the patient's own actions.

CASE REPORT

Case 1

A 13 year old young child presented with multiple painful erosions with crusting over face, upper limb, lower limb trunk since 1 month. Patient and mother claimed that lesions were sudden in onset with burning sensation prior to onset of lesions and refused application of irritants, self infliction of injury.

On examination: there were multiple linear, monomorphic erosions with crusting clearly demarcated from surrounding skin over face, upper limb, lower limb, trunk, nape of neck, buttocks mainly over the accessible areas (Figs. 1a – 1d). Psychiatric evaluation was done and revealed teenage maladjustment disorder.

Individual patient counselling and parental counselling was done. Patient was treated with fluoxetine 10mg and Olanzapine 2.5mg and topical fusidic acid over erosions.

Case 2

A 21 year old man presented with multiple asymptomatic raised lesions on the right forearm of one year duration. He gave a history of progressive appearance of lesions on the affected limb. The mode of onset could not be explained.

On examination: there were multiple hyperpigmented atrophic scars in linear distribution on the dorsal aspect of right forearm (Fig. 2). A skin biopsy revealed findings suggestive of hypertrophic scars. He was treated with occlusive/intralesional steroids over a three-month period with fair response. His brother claimed that the individual had initially produced these lesions using burning cigarette ends. No motive could be identified for producing these lesions over this length of time. He was placed under regular therapy and observation under the care of a psychiatrist.

Case 3

A 25 year old medical student presented to us with multiple erosions over all fingers of his hands and also over

How to cite this article: Harsha G, Bijina J, Patra AK. Case series: Three cases of dermatitis artefacta. Our Dermatol Online. 2019;10(2):145-147.

Submission: 21.07.2018; **Acceptance:** 25.09.2018

DOI: 10.7241/our.20192.8

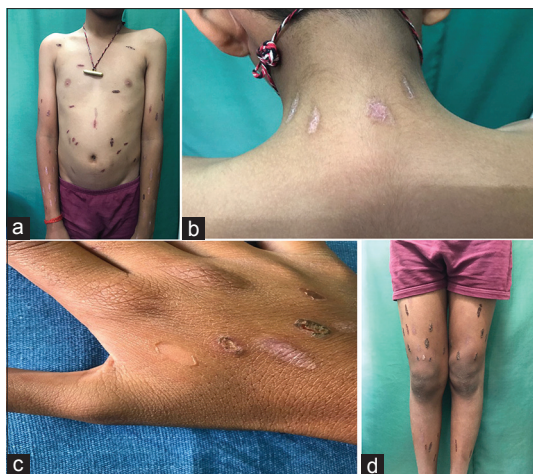

Figure 1: (a) Multiple linear, monomorphic erosions with crusting clearly demarcated from surrounding skin over upper limb, trunk. (b) Multiple healed erosions over nape of neck. (c) Multiple fresh and healed erosions with crust over dorsum of right hand. (d) Multiple linear, monomorphic erosions with crusting clearly demarcated from surrounding skin over lower limb.

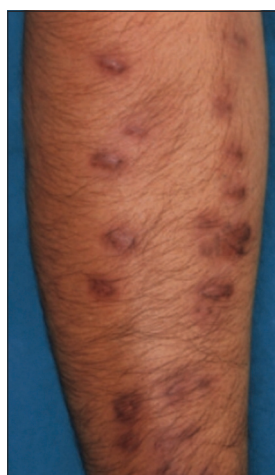


Figure 2: Multiple hyperpigmented atrophic scars in linear distribution on the dorsal aspect of right forearm.

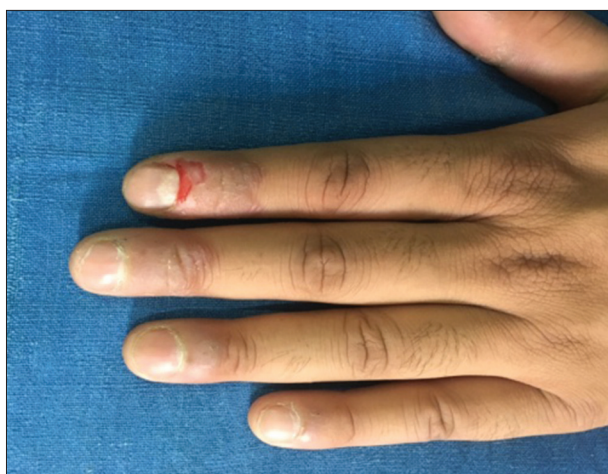

Figure 3: Multiple erosions with post-inflammatory hyperpigmentation over tip and proximal nail folds of all fingers.

lips. He claims that these lesions appear spontaneously associated with burning sensation. He was depressed, withdrawn, and unwilling to discuss his problems.

On examination: there were multiple erosions with post-inflammatory hyperpigmentation over tip and proximal nail folds of all fingers and lips (Fig. 3). On psychiatric evaluation, we came to the conclusion that interpersonal conflict with his parents was the most probable cause. His histopathology was nonspecific. He was treated with antidepressants and psychiatric counselling was done.

DISCUSSION

Dermatitis artefacta, a factitious dermatitis from self-inflicted injury, is a diagnosis of exclusion and when there is evidence of an artifactual cause. Lack of clinical and histopathologic correlation can raise suspicion, as in this case. Dermatitis artefacta frequently is associated with underlying psychosocial problems [1,2]. Therefore, confrontation to explore the underlying psychosocial conflicts should be strongly discouraged [3]; rather, a gentle, nonjudgmental, and empathetic approach often works. Several factors such as delayed developmental milestones, marital dispute, loss of close relatives in the recent past, self-guilt, disturbed parent-child relationship, bipolar personality disorders, and sexual and substance abuse are implicated as the precipitating factors [4].

The management of these patients has to be gentle, non-confrontational and flexible and involves building a mutual trust and rapport between patient and doctor. It is imperative that we follow an integral approach and treat these patients as a bio-psychosocial individual incorporating their thoughts and manipulations without being judgmental. Initial strong therapeutic alliance with the patient, in terms of mutual trust and rapport, is very crucial for a better outcome as prognosis of the disease is not good with frequent waxing and waning. Antidepressants in the form of selective serotonin reuptake inhibitor and behavioral therapy [5] are the mainstay of treatment. Dermatological care with bland emollient, topical antibiotics, and occlusive dressing should not be underestimated as the patients tend to be emotionally attached to their skin.

CONCLUSION

DA is often a challenge for the clinicians because of its rarity, vague history, bizarre and polymorphic

morphology, lack of decisive diagnostic tests, and poor therapeutic outcomes.

CONSENT

The examination of the patient was conducted according to the Declaration of Helsinki principles.

REFERENCES

1. Mohandas P, Bewley A, Taylor R. Dermatitis artefacta and artefactual skin disease: the need for a psychodermatology multidisciplinary team to treat a difficult condition. *Br J Dermatol.* 2013;169:600-6.
2. Gil-Bistes D, Kluger N, Guillot B, Bessis D. Dermatitis artefacta in a young girl. *Arch Pediatr.* 2010;17:1543-5.
3. Gattu S, Rashid RM, Khachemoune A. Self-induced skin lesions: A review of dermatitis artefacta. *Cutis.* 2009;84:247–51.
4. Zalewska A, Kondras K, Narbutt J, Sysa-Jedrzejowska A. Dermatitis artefacta in a patient with paranoid syndrome. *Acta Dermatovenerol Alp Pannonica Adriat.* 2007;16:37–9.
5. Heller MM, Koo JM. Neurotic excoriations, acne excoriee, and factitial dermatitis. In: Heller MM, Koo JY, editors. *Contemporary Diagnosis and Management in Psychodermatology.* 1st ed. Newton, PA, USA: Handbooks in Health Care Co; 2011. pp. 37–44.

Copyright by Gangadhar Harsha, et al. This is an open-access article distributed under the terms of the Creative Commons Attribution License, which permits unrestricted use, distribution, and reproduction in any medium, provided the original author and source are credited.
Source of Support: Nil, **Conflict of Interest:** None declared.

Persistent pemphigus vulgaris and pemphigus foliaceus showing features of tufted hair folliculitis just on the scalp

Maral Nouriyani¹, Fatemeh Montazer², Fatemeh Rouzbeh³, Ramina Mofarrah⁴, Ramin Mofarrah⁵

¹Student Research Committee, Sari Branch, Islamic Azad University of Medical Sciences, Sari, Iran, ²Department of Pathology, Gastrointestinal Cancer Research Center, Imam Hospital, Mazandaran university of Medical Sciences, Sari, Iran, ³Department of Infectious Diseases, Sari Branch, Islamic Azad University, Sari, Iran, ⁴Student Research Committee, Shiraz Branch, University of Medical Sciences, Shiraz, Iran, ⁵Department of Dermatology, Faculty of Medicine, Islamic Azad University, Sari, Iran

Corresponding author: Ramin Mofarrah MD, E-mail: ramin.mofarrah@gmail.com

ABSTRACT

Pemphigus vulgaris (PV) and pemphigus foliaceus (PF) are rare autoimmune blistering diseases. The combination of these diseases together is very rare on the scalp. We report a 52-year-old female patient with localized painful crusted and prurient erosions and hair loss just on the scalp and no mucosal involvement. Scalp lesions had persisted about 4 years and the patient was wrongly diagnosed with psoriasis in these years. Clinical findings, as well as the results of biopsy and direct immunofluorescence, detected pemphigus vulgaris and pemphigus foliaceus also we have seen features of tufted hair folliculitis. treatment with systemic and topical corticosteroids resulted in clinical remission, with regrowth of scalp hair.

Key words: Pemphigus vulgaris; Pemphigus foliaceus; Tufted hair folliculitis; Scalp

INTRODUCTION

Pemphigus vulgaris and pemphigus foliaceus are rare diseases and the incidence of pemphigus depending on the area is 2 to 10 cases per one million [1]. According to our research no one has reported any cases in which these two types have occurred together on the scalp.

Pemphigus is a potentially life threatening autoimmune disease [2]. Two major types of pemphigus are pemphigus vulgaris and pemphigus foliaceus [3]. All pemphigus vulgaris patients have mucus involvement and more than half of them have skin involvement, but hair loss is rarely seen [3-5]. Oral lesions mostly appear in the buccal, palatine and gingival mucosa [6]. They appear a few weeks or months before skin lesions [7].

In pemphigus foliaceus, lesions only appear on the skin and there is rarely any mucus involvement [3,6].

And these lesions often appear on the face and upper trunk. Compared to the pemphigus vulgaris, the blisters have a more superficial position in the epidermis [7]. In pemphigus disease, the immune system targets the desmoglein protein group and the intercellular transdermal desmosome disappear [6,7]. In pemphigus vulgaris it targets desmoglein 3 and in pemphigus foliaceae it targets desmoglein 1 [5].

We report a rare case of pemphigus vulgaris and pemphigus foliaceus involving just the scalp that shows features of tufted hair folliculitis.

CASE REPORT

We report on a diabetic 52-year-old female patient with about a 4-year history of localized painful crusted and prurient erosions and these lesions did not leave

How to cite this article: Nouriyani M, Montazer F, Rouzbeh F, Mofarrah R, Mofarrah R. Persistent pemphigus vulgaris and pemphigus foliaceus showing features of tufted hair folliculitis just on the scalp. *Our Dermatol Online*. 2019;10(2):148-150.

Submission: 12.09.2018; **Acceptance:** 28.11.2018

DOI: 10.7241/ourd.20192.9

the scar tissue after recovery and there was hair loss only in those areas and she doesn't have any mucousal involvement (Fig. 1).

Apparent features of tufted hair folliculitis resulted in her illness being wrongly diagnosed as psoriasis and she used Daivobet gel and Clotrimazole for a while but she had frequent periods of remission and recurrence.

Her illness recurred during stress and in bad mental conditions and her erosions were persistent.

The patient also had a history of diabetes and she takes Metformin.

Biopsy was taken from the lesion in two samples from two separate parts and the histopathology findings were compatible with the diagnosis of pemphigus vulgaris (Fig. 2) and pemphigus foliaceus (Fig. 3),

demonstrating acantholysis of the subcorneal and suprabasal area of entire epidermis.

Direct immunofluorescence demonstrated immunoglobulin G and Anti C3 deposition on the intercellular spaces within the epidermis (Fig. 4).

After rejecting the diagnosis of psoriasis and making the new diagnosis of pemphigus vulgaris and pemphigus foliaceus disease, the previous medications were discontinued.

The patient was treated with 7.5mg of Prednisolone for 3 weeks and after that the pill was tapered to a quarter per day for the rest of the 2-month treatment period. After that the patient finally discontinued oral treatment.

Also during this time, the patient used the topical combined treatment of Tacrolimus and Clobetasol 1%.

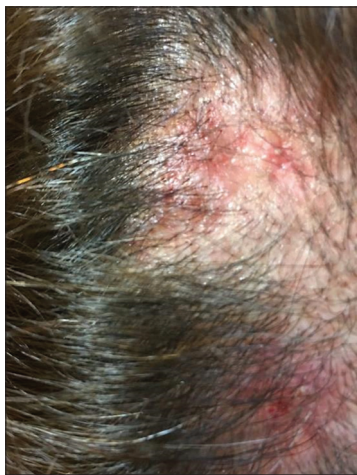

Figure 1: Scalp involvement in pemphigus vulgaris and pemphigus foliaceus.

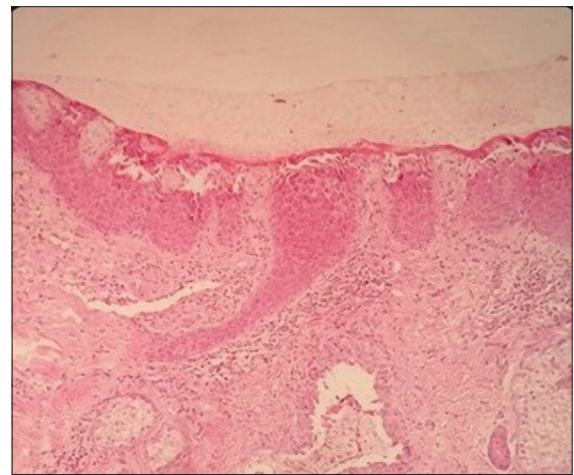


Figure 3: Pemphigus foliaceus: superficial acantholysis of epidermis within granular layer(x100).

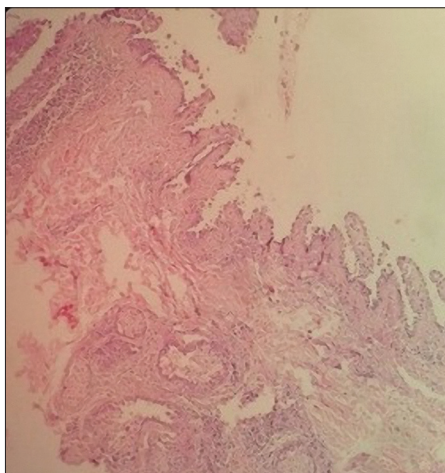


Figure 2: Pemphigus vulgaris: showing acantholysis and conspicuous villi (x400).

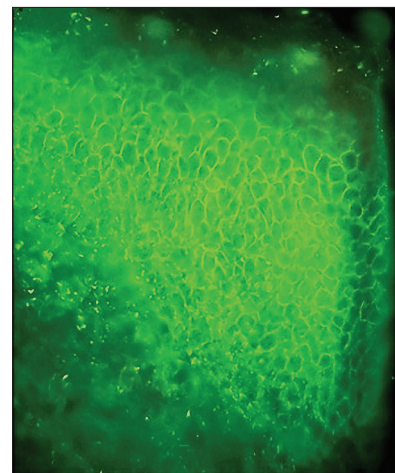


Figure 4: Direct immunofluorescence: typical intercellular staining (IgG) of the epidermis.

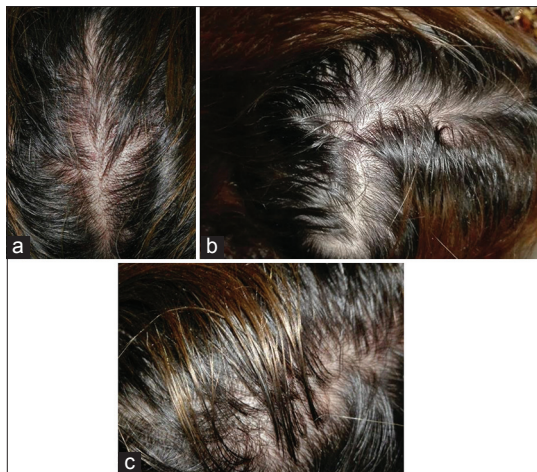

Figure 5: There is no lesions after treatment.

Eventually the patient discontinued the treatment after 3 months due to the rise of blood pressure and during the patient's follow up about 4 months later, her lesions had remissioned without relapse and regrowth of scalp hair could be seen (Figs. 5a – 5c).

Prior to the study, patient gave written consent to the examination and biopsy after having been informed about the procedure.

DISCUSSION

Pemphigus vulgaris and pemphigus foliaceus are two major types of the rare disease pemphigus which cause skin lesions. They are characterized by the production of autoantibodies against intercellular substances and they are classified as autoimmune diseases.

The lesions were clinically similar to psoriasis and did not have the clinical appearance of pemphigus so we didn't consider it.

After taking a biopsy, psoriasis was rejected and pemphigus vulgaris and pemphigus foliaceus were confirmed so our final diagnosis was different from the initial diagnosis. Differential diagnoses of scalp involvement include psoriasis, seborrheic dermatitis, sebopsoriasis and cicatricial pemphigoid.

The cause of pemphigus vulgaris and its trigger is unknown and it is present in the scalp, but hair loss in this disease is rarely seen and is often caused by secondary infection [4,5,9] most researchers report a secondary bacterial infection as the cause of hair folliculitis [5].

Apart from their rare scalp involvement, pemphigus vulgaris mostly involves the mucus and the skin while pemphigus foliaceus involves the skin. But none of them involve just the scalp.

In pemphigus foliaceus, cause of the disease is multifactorial and its pathogenesis is unknown and we cannot prevent the disease, but the impact of the environment and genetics has been proven [8] and preventing it is like pemphigus foliaceus.

Also pemphigus vulgaris in the early stages and pemphigus foliaceus in the final stages can have the same histopathology and DIF appearance.

The reason for the introduction of the case is due to the presence of both pemphigus simultaneously on the scalp, which has not yet been reported.

Consent

The examination of the patient was conducted according to the Declaration of Helsinki principles.

REFERENCES

1. DiMarco C. Pemphigus: Pathogenesis to Treatment. Rhode Island Med J. 2016;99:28-31.
2. Sar-Pomian M, Kurzeja M, Rudnicka L, Olszewska M. The value of trichoscopy in the differential diagnosis of scalp lesions in pemphigus vulgaris and pemphigus foliaceus. An Bras Dermatol. 2014;89:1007–12.
3. Amagai M. Pemphigus. In: Bologna JL, Jorizzo JL, Schaffer JV, editors. Dermatology, 3rd ed. London: Elsevier; 2012: 461-474.
4. Hadayer N, Ramot Y, Maly A, Zlotogorski A. Pemphigus vulgaris with loss of hair on the scalp. Int J Trichology. 2013;5:157–8.
5. Ko DK, Chae IS, Chung KH, Park JS, Chung H. Persistent pemphigus vulgaris showing features of tufted hair folliculitis. Ann Dermatol. 2011;23:523–5.
6. Payne AS, Stanley JR. Pemphigus. In: Goldsmith LA, Katz SI, Gilchrist BA, Paller AS, Leffell DJ, Wolff K, editors. Fitzpatrick's dermatology in general medicine, 8th ed. New York: McGraw-Hill; 2007: 586-599.
7. High WA. Blistering diseases. In: Elston DM, Ferringer T, Ko CJ, Peckham S, High WA, DiCaudo DJ. Dermatopathology, 2nd ed. London: Elsevier; 2014: 161-171.
8. Malheiros D, Panepucci RA, Roselino AM, Araújo AG, Zago pMA, Petzl-Erler ML. Genome-wide gene expression profiling reveals unsuspected molecular alterations in pemphigus foliaceus. Immunology. 2014;143:381–95.
9. Pirmez R. Acantholytic Hair Casts: A Dermoscopic Sign of Pemphigus Vulgaris of the Scalp. Int J Trichology. 2012;4:172–3.

Copyright by Maral Nouriyani, et al. This is an open-access article distributed under the terms of the Creative Commons Attribution License, which permits unrestricted use, distribution, and reproduction in any medium, provided the original author and source are credited.

Source of Support: Nil, Conflict of Interest: None declared.

Diffuse primary B-cell lymphoma of large B-cell, leg- type. A case report

Beatriz Di Martino Ortiz, Rosalba Riveros, Lourdes Rodríguez, Silvia Aguilar, Mirtha Rodríguez, Oilda Knopfmacher, Lourdes Bolla

Dermatology Department, Clinicas Hospital, Faculty of Medical Sciences, National University of Asunción-Paraguay

Corresponding author: Prof. Dra. Beatriz Di Martino Ortiz, E-mail: beatrizdimartino@gmail.com

SUMMARY

B-cell cutaneous lymphomas are a heterogeneous group of lymphomas that appear on skin with no evidence of extracutaneous involvement at the time of diagnosis and correspond between 20% and 25% of primary cutaneous lymphomas. We present a case of diffuse primary B-cell lymphoma of large B-cell, diagnosed with clinical and pathological anatomy, typified by immunohistochemistry in an 87-year-old patient with multiple baseline pathologies, polymedicated, with good cutaneous response to treatment.

Key words: Cutaneous B-cell; Leg-type; Diffuse

How to cite this article: Di Martino Ortiz B, Riveros R, Rodríguez L, Aguilar S, Rodríguez M, Knopfmacher O, Bolla L. Diffuse primary B-cell lymphoma of large B-cell, leg-type. A case report. *Our Dermatol Online*. 2019;10(2):151-155.

Submission: 13.07.2018; **Acceptance:** 27.09.2018

DOI:10.7241/ourd.20192.10

Linfoma B cutáneo primario difuso de células grandes, tipo pierna. Reporte de un caso

Beatriz Di Martino Ortiz, Rosalba Riveros, Lourdes Rodríguez, Silvia Aguilar, Mirtha Rodríguez, Oilda Knopfmacher, Lourdes Bolla

Dermatology Department, Clinicas Hospital, Faculty of Medical Sciences, National University of Asunción-Paraguay

Corresponding author: Prof. Dra. Beatriz Di Martino Ortiz, E-mail: beatrizdimartino@gmail.com

RESUMEN

Los linfomas cutáneos de células B son un grupo heterogéneo de linfomas que se presentan en piel sin evidencia de compromiso extracutáneo al momento del diagnóstico y corresponden entre 20% al 25% de los linfomas cutáneos primarios. Presentamos un caso de un linfoma primario cutáneo difuso de células B grandes, tipo pierna, diagnosticado con la clínica y anatomía patológica, tipificado por la inmunohistoquímica en un paciente de 87 años con múltiples patologías de base, polimedicado, con buena respuesta cutánea al tratamiento instaurado.

Palabras clave: Linfoma cutáneo de células B; Tipo pierna; Difuso

INTRODUCCIÓN

Los linfomas cutáneos primarios de células B son un grupo heterogéneo de neoplasias linfoides de curso clínico indolente que tienden a permanecer localizados en la piel y sólo en raras ocasiones presentan una diseminación extracutánea.

Como grupo, los linfomas cutáneos primarios de células B presentan un mejor pronóstico que los de células T.

Una evaluación correcta de los pacientes en los que se sospeche la presencia de un linfoma cutáneo de células B requiere la correlación adecuada de la información clínica, los hallazgos histopatológicos e inmunofenotípicos y los datos de biología molecular. El diagnóstico definitivo, además, debe tener en cuenta el subtipo específico según las clasificaciones actuales de los linfomas.

El tratamiento inicial suele ser conservador, bien mediante exéresis quirúrgica, si es factible, o mediante radioterapia convencional localizada para las lesiones primarias de mayor tamaño o en caso de recurrencias. Sólo se recomienda tratamiento poliquimioterápico para los pacientes con una enfermedad cutánea

extensa, en aquellas formas o subtipos que se consideran de curso agresivo o en casos con afectación extracutánea y, a menudo, en combinación con radioterapia local.

CASO CLÍNICO

Varón, 87 años, paraguayo, casado, jubilado, procedente de medio urbano, consulta por una lesión sobre elevada rojiza tipo picadura de insecto en pierna derecha de 9 meses de evolución, con aumento progresivo de tamaño, y sensación de hormigueo. Consultó con facultativo quién indica ATB VO y tópicos (betametasona tópica y cremas hidratantes), sin mejoría. Hace 2 meses aparecen más lesiones de gran tamaño, abarcando toda la pierna derecha, algunas drenan secreción serohemática. Se realiza curaciones con iodopovidona, con empeoramiento de las lesiones.

Hace 1 mes lesión sobre elevada roja en mentón con aumento progresivo de tamaño y número. Recibe cefalexina, AINES, ácido fusídico + betametasona, sin mejoría, por lo que acude a nuestro servicio.

Pérdida de 10 Kg desde el inicio del cuadro.

How to cite this article: Linfoma B cutáneo primario difuso de células grandes, tipo pierna. Reporte de un caso. *Our Dermatol Online*. 2019;10(2):151-155.

Submission: 13.07.2018; **Acceptance:** 27.09.2018

DOI:10.7241/ourd.20192.10

Antecedentes patológicos personales

HTA, Enfermedad de Parkinson, Cirugía de próstata hace 20 años por Carcinoma de próstata, Cardiopatía isquémica con marcapasos, Ex tabaquista, Antecedente de Neumotórax por rotura de bulla. En tratamiento actual con: Losartan 50 mg/50 mg, Amlodipina 10mg/d, Memantina 10mg/10mg, Alprazolam 0,5 mg/d, Quetiapina 100mg/d, Donepecilo 10mg/d, Tamsulosina 0,4 mg/d.

Antecedentes patológicos familiares

Madre fallecida por Cáncer de colon.

Examen físico

- Placa hiperpigmentada de bordes irregulares, límites netos, que abarca toda la circunferencia de la pierna derecha, con áreas hipopigmentadas y descamativas en extremo distal, sobre la que asientan múltiples tumores eritematovioláceos redondeados bien delimitados de consistencia sólida elástica de cuyos diámetros oscilan de 5 a 40 mm (Fig. 1).
- La mayor de aproximadamente 40 mm de diámetro en tercio inferior cara anterior de pierna derecha, friable y con costras hemáticas. Hiperqueratosis plantar y subungueal de primer dedo de pie derecho (Fig. 2).
- Tumoración eritematosa redondeada de bordes regulares límites netos de consistencia sólida dura de 1 cm de diámetro en mentón lado derecho y otra de iguales características de 1,5 cm en región infra

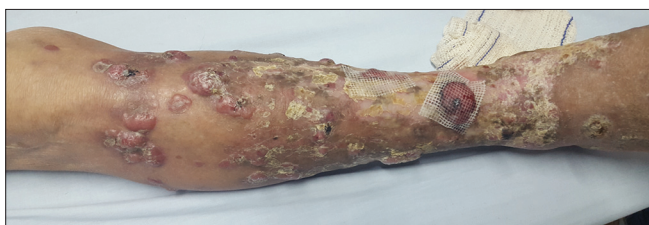

Figure 1: Clinic. Multiple erythematous violaceous tumors that settle in the lower third of the anterior face of the right leg.

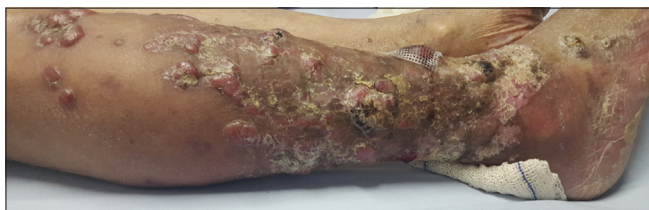

Figure 2: Clinic. Multiple well-demarcated rounded erythematous violaceous tumors of solid elastic consistency, between 5 and 40 mm in right leg. Plantar and subungueal hyperkeratosis of the right first toe.

labial izquierda (Fig. 3).

- Paciente caquéctico, sin adenomegalias ni otras lesiones en piel.

Se toma **biopsia** de una de las lesiones nodulares de la pierna, la cual muestra epidermis preservada y proceso neoplásico asentado en dermis superficial y media de crecimiento difuso. Ausencia de afectación epidérmica o epidermotropismo. La proliferación celular observada es de estirpe linfoide y crecimiento difuso (Fig. 4).

A mayor aumento observamos que se trata de una proliferación linfoide atípica constituida por células grandes con núcleos vesiculares, uno o más nucléolos evidentes y citoplasma escaso a moderado. Crecen en forma difusa desde la dermis papilar a la reticular profunda. En áreas adoptan un patrón nodular. Se ven escasos linfocitos pequeños mezclados. El índice mitótico es alto (Fig. 5).

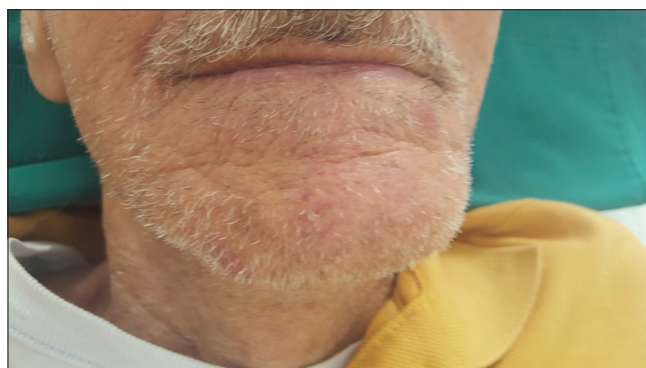

Figure 3: Clinic. Erythematous solid tumor of 1 cm in diameter on right side chin. Cachectic patient, without adenomegalias or other skin lesions.

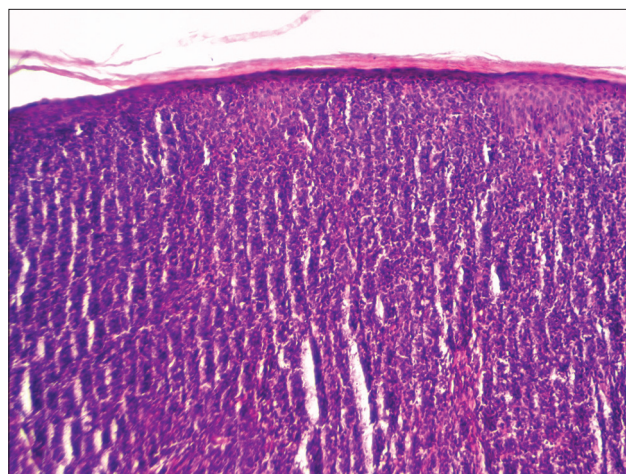


Figure 4: Histopathology. Neoplastic diffuse process settled in superficial and mid dermis. Absence of epidermal involvement or epidermotropism. The cell proliferation observed is of lymphoid strain and diffuse growth (HE 10X).

Inmunohistoquímica

Las células linfoides son CD 20+, CD10-, MUM 1+, BCL 2+, BCL 6+/-.

Laboratorio

HMG: Gb 5.800/mm³, N 67%, L 31%, Eo 9%, Hb 11,2 g/dl, Hto 35%, Plaquetas 190000/mm³. Urea: 64 mg/dl; Creat 1,78 mg/dl; Perfil hepático, lipídico: En rango. VDRL y HIV No Reactivas. PAS total: 0,04 ng/ml.

Ecocardiografía

FE: 65%, dilatación de AI, Insuficiencia mitral y tricuspídea, Hipertensión pulmonar leve.

Ecografía renal y vesico prostática

Quiste renal simple lado izquierdo. Logia prostática de características normales sin signos de recidiva.

TAC con contraste de cuello, tórax, abdomen, pelvis

sin tumoraciones.

Biopsia de Médula Ósea

Fragmento de tejido óseo esponjoso con espículas óseas adelgazadas, notándose abundante tejido adiposo con tejido medular que muestran células de las tres líneas hematológicas. No se observan infiltración extrínseca.

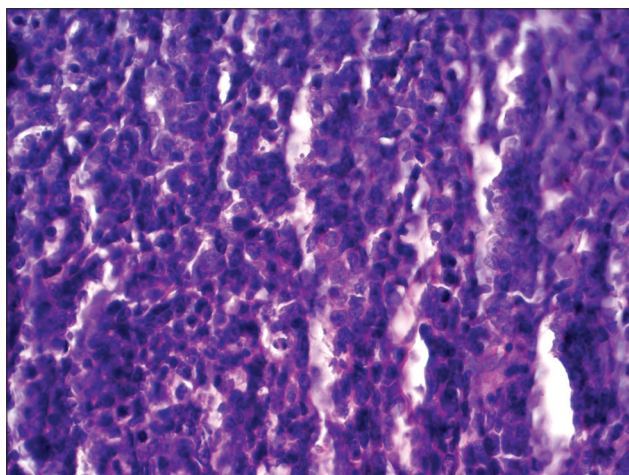


Figure 5: Histopathology. A higher magnification. Large cells with vesicular nuclei, one or more nucleoli and scarce cytoplasm. The mitotic index is high (HE 40X).

Diagnóstico final

Síndrome antifosfolipídico en paciente con artritis reumatoidea. *Linfoma B Cutáneo Primario Difuso de Células Grandes, Tipo Pierna (PCDLBCL, leg type)*.

Evolución y tratamiento

El paciente tenía 50 kg de peso por lo que inició Rituximab 375 mg/m², con etapa de inducción: Dosis de ataque 600 mg cada 28 días por 6 dosis. Recibió las 6 sesiones con mejoría casi total de las lesiones cutáneas, pero fallece tras última sesión por complicaciones infecciosas.

Prior to the study, patient gave written consent to the examination and biopsy after having been informed about the procedure.

COMENTARIOS

Los linfomas cutáneos primarios se definen como tal cuando se originan en la piel sin evidencia de compromiso extracutáneo en el momento del diagnóstico. Pertenecen a los linfomas no Hodgkin extranodales, entre los cuales la piel es el segundo órgano más frecuentemente afectado luego del tracto gastrointestinal [1-3].

Los linfomas cutáneos de células B (LCCB) corresponden al 20-25% de todos los linfomas cutáneos. En 2008, la WHO-EORTC define al linfoma cutáneo difuso de células grandes, tipo de la pierna como una entidad clínica aparte [1,2].

Su etiopatogenia es desconocida. Se postula que puede representar una respuesta linfoproliferativa a un estímulo antigénico crónico del tejido linfóide asociado a la piel. Se desconocen los mecanismos implicados en la presencia o persistencia de estas células neoplásicas malignas en dermis; sólo en algunos casos se demostró presencia de agentes infecciosos tales como herpes virus tipo 8, VIH, VHC, bacterias como *Borrelia Burgdorferi* o en el contexto de enfermedades autoinmune [1,2,4].

Afecta principalmente a pacientes mayores de 70 años, con predominio en mujeres 3-4:1 [1,3].

Clínicamente se presentan como nódulos o tumores eritematovioláceos, de consistencia firme, rápido crecimiento, localizado en una o ambas piernas, aunque también de manera infrecuente pueden asentar en

otras regiones tales como cabeza, cuello, tronco y extremidades superiores [1,4,5].

Los aspectos histopatológicos están dados por un infiltrado linfoide difuso, no epidermotropo, existiendo una zona de colágeno denominada zona de Grenz. El infiltrado corresponde a células grandes, con núcleo al menos 2 veces más grande que un linfocito pequeño, el cual puede extenderse hasta tejido celular subcutáneo [2,4,6,7].

El estudio inmunohistoquímico pone de manifiesto células neoplásicas que expresan antígenos linfoides de células B (CD19, CD20, CD22, CD79 a). Asimismo, también el bcl6 puede ser positivo en la mayoría de los casos; el bcl2 es fuertemente positivo en los LCCB de células grande tipo pierna, lo que lo diferencia de otras localizaciones, donde su expresión es menor, mientras que el CD10 es negativo en la mayoría de los casos [2,4,6,7].

La tasa de supervivencia a los 5 años es de aproximadamente del 57-67%; se reconoce como factor pronóstico, además del bcl2, a la localización anatómica, siendo menos agresivo cuando asienta en otro sitio fuera de la pierna, como nuestro caso [2,4,7-11].

El tratamiento recomendado incluye radioterapia, exéresis quirúrgica o la administración intralesional de quimioterápicos (cisplatino) para las lesiones únicas y poliquimioterapia con R-CHOP (rituximab, ciclofosfamida, doxorubicina, vincristina y prednisona) para las lesiones múltiples y cuando la progresión de la enfermedad es objetivada, podría plantearse el uso de monoterapia con rituximab (anticuerpo monoclonal anti-CD20), dependiendo cada caso en particular. El curso clínico es favorable, aunque ocasionalmente desarrollan recurrencias cutáneas [2,4,6,7-11].

En conclusión, presentamos este caso por tratarse de un linfoma cutáneo primario poco frecuente, constituyendo el primer caso en nuestro servicio, además de resaltar la buena evolución con quimioterapia única

con Rituximab, teniendo en cuenta la edad de nuestro paciente y sus comorbilidades.

Consent

The examination of the patient was conducted according to the Declaration of Helsinki principles.

BIBLIOGRAFÍA

1. Martínez M, Meneses M, Vannetti A, Samper A, Martínez Bernal M. Linfoma cutáneo primario de células B, tipo pierna: reporte de un caso. *Arch Argent Dermatol*. 2016;66:1-4.
2. Gallardo F, Pujol R. Diagnóstico y tratamiento de los linfomas cutáneos primarios de células B. *Actas Dermosifiliogr* 2004;95:537-47.
3. Azcune R, Barbarulo A, Gavazza S, Fontana MI, Spelta MG, Barrera M, et al. Linfomas B primitivos cutáneos: nuestra experiencia a propósito de 22 casos. *Dermatol Argent*. 2008;14:35-45.
4. Vilchez M, Villarreal M, Valente E, Ruiz Lascano A, Kurpis M. Linfoma primario cutáneo difuso de células B grandes, tipo pierna, localizado en tronco. *Arch Argent Dermatol*. 2010;60:1-4.
5. Campoy MV, Matamoros E, Michelena MA, Garritano MV, Maradeo R, Arena G, et al. Linfoma B primitivo cutáneo difuso de células grandes de la pierna localizado en antebrazo. *Arch Argent Dermatol*. 2015;65:86-9.
6. Halid A, Wolfram S. Cutaneous Lymphoma. En: Wolff K, Goldsmith LA, Katz SI, Gilchrist BA, Paller AS, Leffell DJ. *Fitzpatrick's Dermatology in General Medicine*. 7ª Ed.; New York: Mc Graw Hill; 2008;3:1386-402.
7. García Herrera A, Estrach Panella T. Una visión de los linfomas cutáneos primarios de células B. *Med Cut ILA*. 2004;32:187-200.
8. Rodríguez Blanco I, Sánchez Aguilar D, Peteiro C, Toribio J. Linfoma B difuso de células grandes cutáneo en una pierna tras un linfoma testicular primario. *Med Cut ILA*. 2007;35:247-9.
9. Martín Carrasco P, Morillo Andújar M, Pérez Ruiz C, De Zulueta Dorado T, Cabrera Pérez R, Conejo-Mir J. Primary cutaneous B-cell lymphomas: study of 22 cases. *Med Clin (Barc)*. 2016;147:207-10.
10. Kempf W, Kazakov D, Belousova I, Mitteldorf C, Kerl K. Paediatric cutaneous lymphomas: a review and comparison with adult counterparts. *J Eur Acad Dermatol Venereol*. 2015;29:1696-709.
11. Kempf W, Kazakov D, Mitteldorf C. Cutaneous Lymphomas: An Update. Part 2: B-Cell Lymphomas and Related Conditions. *Am J Dermatopathol*. 2014;36:197-210.

Copyright by Beatriz Di Martino Ortiz, et al. This is an open-access article distributed under the terms of the Creative Commons Attribution License, which permits unrestricted use, distribution, and reproduction in any medium, provided the original author and source are credited.
Source of Support: Nil, **Conflict of Interest:** None declared.

Acquired vulvar lymphangioma circumscriptum: A report of 3 cases

Siham Mansouri, Sara Mai, Nadia Ismaili, Laila Benzekri, Badr Hassam

Department of Dermatology, Department of Dermatology, University Hospital Ibn Sina Rabat, Morocco

Corresponding author: Dr. Siham Mansouri, E-mail: siham-mnsr@hotmail.fr

ABSTRACT

Vulvar lymphangioma circumscriptum (LC) is an unusual benign condition, congenital or acquired, related to interference in the lymph drainage. This entity can be confused with conditions such as genital warts. We sought to clarify the clinicopathologic features of the Acquired vulvar LC by studying 3 affected patients from our institution. We report 3 cases of vulvar LC: Two cases were presented after gynecologic cancer treatment (surgery, lymphadenectomy, and radiotherapy). 1 case was related to lower limb chronic lymphedema. In two of them, the initial clinical diagnosis was genital wart. Two patients were treated by Laser CO₂ and cryotherapy, with a good response and without any recurrence. The possibility of vulvar LC should be taken into account as a possible diagnosis in patients with previous oncological surgery or genital warts refractory to the conventional treatment. Knowledge on the features of this lesion can avoid unnecessary clinical and therapeutic procedures.

Key words: Acquired; Vulvar; Lymphangioma circumscriptum

INTRODUCTION

Lymphangioma circumscriptum (LC) is a rare vascular malformation that affects the lymph vessels of the papillary dermis. LC can be either congenital or acquired after damaging the previously normal lymph channels [1]. It frequently appears in the armpit, the neck, and the proximal portion of the extremities [2]. Acquired vulvar LC (AVLC), is a rare, benign condition [3]. Most of the descriptions refer to isolated cases or short series of patients. We report 3 cases and describe the clinical and pathologic characteristics, to add to the limited data present in the literature.

CASE REPORTS

We report 3 cases of AVLC. The summary of the clinical features of our serie is shown in table 1. Ages ranged from 46 to 72 yr (average 60 yr). Two cases were presented after gynecologic cancer treatment (surgery, lymphadenectomy, and radiotherapy) (Figs. 1A and B). One case was related to lower limb chronic lymphedema

(Fig. 1C). The average range of the lapse of time between the onset of the predisposing factor and the LC onset was 6 yr (ranging between 2 and 10 yr). In our patients, LC presented with the same lesions: they had several small verrucous papules with intervening normal skin (Figs. 1A - C). A careful dermoscopic examination of the lesions showed the following features: lacunae, vascular structures and white lines. All lesions had a light background colour (Fig. 2). The initial clinical diagnosis in 2 of the cases was condyloma and were treated by electrocoagulation and trichloacetic acid, without improvement. Histopathologic findings were similar in all biopsy specimens. All lesions showed the presence of variably dilated vessels located within the superficial papillary dermis. These were lined by a single layer of endothelial cells with flat nuclei. The dermis between them did not show the presence of inflammation (Fig. 3). Morphologic features suggesting infection by human papillomavirus or dysplasia were not found. two patients were treated by Laser CO₂ and cryotherapy, with a good response. The third patient refused a treatment and a conservative treatment was performed.

How to cite this article: Mansouri S, Mai S, Ismaili N, Benzekri L, Hassam B. Acquired vulvar lymphangioma circumscriptum: a report of 3 cases. *Our Dermatol Online*. 2019;10(2):156-158.

Submission: 22.06.2018; **Acceptance:** 27.09.2018

DOI:10.7241/ourd.20192.11

Table 1: Clinical features

Case	Age at presentation (year)	Predisposing conditions	Interval (year)	Clinical presentation/ diagnosis	Other data	Treatment	Recurrence/ interval (year)	Follow-up (year)
1	63	Stage Ib cervix squamous CA Treatment: radical TAH, LND, and RT	2	Multiple warty skin lesions/ condyloma	Obesity	Laser CO2	No	7
2	72	Stage Ic endometrial CA Treatment: radical TAH-BSO, LND, and RT	5	IF (gynecology checkup)	Obesity, lower right limb lymphedema	Cryotherapy	Yes/2	4
3	46	Bilateral lower limb lymphedema	6	Multiple warty skin lesions/ condyloma		Observation	No	2

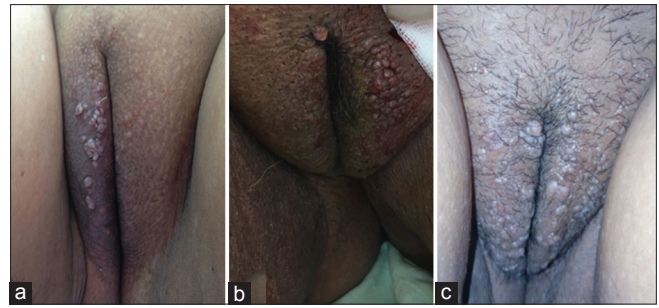


Figure 1: A and B: AVLC after gynecologic cancer treatment. C: AVLC related to lower limb chronic lymphedema

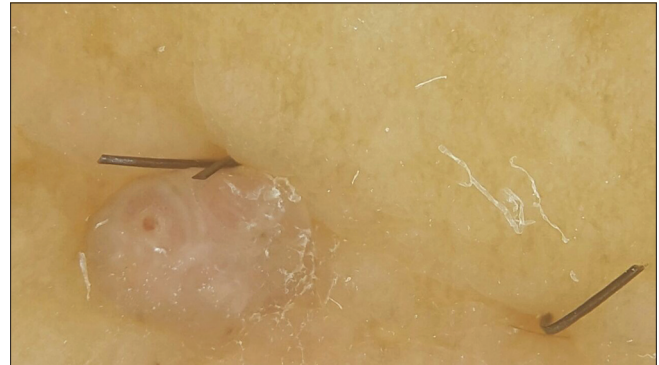

Figure 2: The dermoscopic view shows a yellow lacunae, white lines and vascular structures

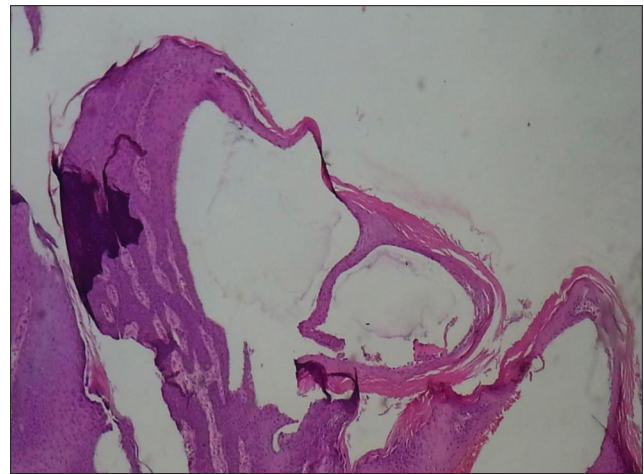


Figure 3: Histopathologic examination revealed the presence of dilated lymphatic vessels in the papillary dermis, bulging up the epidermis

Prior to the study, patient gave written consent to the examination and biopsy after having been informed about the procedure.

DISCUSSION

The AVLC, is a rare entity, as evidenced by less than 100 cases in the literature. Median age at diagnosis for acquired VLC is 52 years [4]. The lapse of time between

the onset of the predisposing factor and the presentation of the LC is usually prolonged, from 3 to 40 years.

The AVLVC is a long-term complication caused by different etiologies [5]. In most cases, the AVLVC are associated to malignancy. It usually arises after radical surgery or cervical cancer radiotherapy. However, there have also been cases after treatment for vulvar cancer, endometrial cancer, or melanoma [3]. A large obstructive pelvic malignancy could lead to VLC (4). It is less often found in non oncological etiologies such as: Crohn disease [5], genital tuberculosis [6], chronic lymphedema [7], or local infectious diseases (acute cellulitis or hidradenitis suppurativa) [8]. Obesity could also have played a role in the development of LC. Several cases in the literature are without known cause [9].

The clinical presentation of ALV is highly variable, ranging from being asymptomatic to a highly disabling condition. Discomfort, itching, rubbing and lymph oozing are the most frequent symptoms [10]. Clinically, ALV usually presents as multiple nodular lesions, verruciform or polypoid, with variable size and, usually, with intervening normal skin. VLC sometimes accompanies lower extremity edema, or genital lymphedema. VLC may pose diagnostic difficulties both clinically and histopathologically. ALV is frequently confounded with warts or condyloma acuminata [11]. The most common dermoscopic pattern associated with ALV is the presence of lacunae and vascular structures. The hypopyon sign and the white or yellowish coloration of lacunae are very characteristic of lymphangioma circumscriptum [12]. Histopathologically, LC is characterized by the presence of dilated lymphatic channels in the papillary dermis. They have a cystic appearance and are layered by a normal-appearing endothelium. The overlying epidermis can show variable degrees of acanthosis and hyperkeratosis [9].

The management of vulvar LC is not standardized and many different treatments with varying results have been proposed. Therapeutic options include surgical excision, yttrium–aluminium–garnet laser, cryotherapy, sclerotherapy, CO2 laser, or electrocoagulation. Conservative treatment is suitable in some cases and, probably, It's the best choice in asymptomatic cases, because of the high recurrence rate in all modalities of treatment [4].

CONCLUSION

VLC is a very rare disease, causing major discomfort, aesthetic prejudice and risk of infection. it is

important to make clinicians aware of this entity so that it can be recognized more rapidly, and to prevent misdiagnosis and unnecessary treatments. when vulvar condylomas or warts are refractory to medical treatment, performing a biopsy should be considered in order to confirm the histology of the condition.

CONSENT

The examination of the patient was conducted according to the Declaration of Helsinki principles.

REFERENCES

1. LeBoit PE, Burg G, Weedon D, et al, eds. World Health Organization Classification of Tumours. Pathology and Genetics of Skin Tumours. Lyon: IARC Press; 2006:247–9.
2. Sanguinetta OP, Requena L, eds. Pathology of Vascular Skin Lesions: Clinicopathologic Correlations. Totowa, NJ: Humana Press; 2003.
3. Stewart CJ, Chan T, Platten M. Acquired lymphangiectasia (lymphangioma circumscriptum) of the vulva: a report of eight cases. *Pathology*. 2009;41:448–53.
4. Chang MB, Newman CC, Davis MDP, Lehman JS. Acquired lymphangiectasia (lymphangioma circumscriptum) of the vulva: Clinicopathologic study of 11 patients from a single institution and 67 from the literature. *Int J Dermatol*. 2016;55:e482-7.
5. Papalas JA, Sanguenza OP, Puri PK, Robboy SJ, Selim MA. Vulvar vascular tumors: a clinicopathologic study of 85 patients. *Am J Dermatopathol*. 2013;35:1–7; quiz 8–10.
6. Vlastos A-T, Malpica A, Follen M. Lymphangioma circumscriptum of the vulva: a review of the literature. *Obstet Gynecol*. 2003;101:946–54.
7. Fadare O, Brannan SM, Arin-Silasi D, Parkash V. Localized lymphedema of the vulva: a clinicopathologic study of 2 cases and a review of the literature. *Int J Gynecol Pathol*. 2011;30:306–13.
8. Sims SM, McLean FW, Davis JD, Morgan LS, Wilkinson EJ. Vulvar lymphangioma circumscriptum: a report of 3 cases, 2 associated with vulvar carcinoma and 1 with hidradenitis suppurativa. *J Low Genit Tract Dis*. 2010;14:234–7.
9. Kokcu A, Sari S, Kefeli M. Primary vulvar lymphangioma circumscriptum: a case report and review of literature. *J Low Genit Tract Dis*. 2015;19:e1–5.
10. Simon L, Trevidic P, Denis P, Vignes S. Vulvar lymphangioma circumscriptum: comparison of primary and acquired forms in a cohort of 57 patients. *JEADV*. 2018;32:e41–e85.
11. Sah SP, Yadav R, Rani S. Lymphangioma circumscriptum of the vulva mimicking genital wart: a case report and review of literature. *J Obstet Gynaecol Res*. 2001;27:293–6.
12. Zaballos P del Pozo LJ, Argenziano G, Karaarslan IK, Landi C, Vera A, et al. Dermoscopy of lymphangioma circumscriptum: A morphological study of 45 cases. *Australas J Dermatol*. 2018;59:e189-93.

Copyright by Siham Mansouri, et al. This is an open-access article distributed under the terms of the Creative Commons Attribution License, which permits unrestricted use, distribution, and reproduction in any medium, provided the original author and source are credited.

Source of Support: Nil, Conflict of Interest: None declared.

Metastatic spindle cell melanoma on cytology – a diagnostic challenge

Archana Shivamurthy¹, Ranjini Kudva², Annappa Kudva³, Padmapriya Jaiprakash²

¹Department of Pathology, Melaka Manipal Medical College, Manipal University, Manipal, India, ²Department of Pathology, Kasturba Medical College, Manipal, Manipal University, Manipal, India, ³Department of Surgery, Kasturba Medical college, Manipal University, Manipal, India

Corresponding author: Dr. Archana Shivamurthy, E-mail: archana_018@yahoo.co.in

ABSTRACT

Spindle cell melanoma is a rare variant of malignant melanoma. The diagnosis on fine needle aspiration cytology can be challenging. An accurate cytological diagnosis is important owing to the prognostic and therapeutic implications. It also directs staging, treatment and prognosis. Spindle cell melanoma may mimic other spindle cell lesions because of the lack of characteristic features of conventional melanoma, spindle cell melanoma can be often mistaken for various other spindle cell lesions. Fine needle aspiration cytology is often used to document recurrent or metastatic disease and thus plays a very important role. We present a case of a 61-year-old male with spindle cell melanoma.

Key words: Melanoma; Spindle cell; Desmoplastic; Cytology

INTRODUCTION

Spindle cell melanoma is a rare variant of malignant melanoma and the diagnosis on fine needle aspiration cytology (FNAC) can be extremely difficult [1,2]. An accurate cytological diagnosis is important owing to the prognostic and therapeutic implications. It also directs staging, treatment and prognosis. The incidence of spindle cell melanoma varies from 3%-14%. Spindle cell melanoma can occur anywhere on the body. Typically, it often presents with widespread metastatic disease [2,3]. However, some melanomas may present as a metastasis of unknown primary origin while others may take several decades to develop metastasis [4].

CASE REPORT

A 61-year-old male came with a history of a mole over the right foot since 4 months. It was insidious in onset and rapidly progressive in size. He had also noticed a swelling in the right thigh. There was no history of fever or chills, loss of weight or appetite. On examination

there was a greyish plaque present over the right foot and right inguinal lymphadenopathy. Ultrasonography of the abdomen revealed few enlarged right external iliac lymph nodes and right inguinal lymph nodes. FNAC of the inguinal node was done, followed by wide local excision of the lesion over the right foot followed by right inguinal block dissection.

FNA smears showed clusters & fascicles of spindle cells with slender elongated nuclei and scant cytoplasm, in a background of macrophages, lymphocytes, few neutrophils and necrosis. The nuclei displayed a bland morphology. Occasional cells showed mild pleomorphism. Macronucleoli and melanin pigment were absent (Fig. 1 and 2). A diagnosis of spindle cell lesion was rendered and in view of the history, a possibility of metastatic spindle cell melanoma was suggested. Grossly, the wide local excision biopsy specimen showed a surface ulcer measuring 2.5 x 2 cm and the cut section showing grey brown areas. 18 lymph nodes were isolated from the right inguinal block dissection specimen. A diagnosis of spindle cell variant of malignant melanoma (Clark's level IV) with

How to cite this article: Shivamurthy A, Kudva R, Kudva A, Jaiprakash P. Metastatic spindle cell melanoma on cytology – a diagnostic challenge. Our Dermatology Online. 2019;10(2):159-162.

Submission: 06.07.2018; **Acceptance:** 08.11.2018

DOI:10.7241/ourd.20192.12

lymph node metastasis was finally rendered (Figs. 3 and 4). Radiation oncology consultation was sought and the patient was advised computerized tomography of thorax, abdomen and pelvis.

DISCUSSION

Cytological features of spindle cell melanoma include predominantly dyscohesive spindle cell cluster, interlacing fascicles and whorls of slender spindle cells with illdefined cell borders, variable amount of cytoplasm, often showing bipolar long cytoplasmic projections which may have curved or twisted ends [5-7]. The presence of epithelioid cells has also been noted, few of which display classical cytological features of conventional melanoma. Cytoplasmic melanin pigments are variably observed [2,7]. The nuclei of the spindle cells vary from oval to slender, with occasionally folded nuclear membrane. Intranuclear

pseudoinclusions are also variably noted. The chromatin is usually granular and delicate, nucleolus being inconspicuous and occasionally prominent [6,8].

The spindle cells can also show varying degrees of cytological atypia, ranging from pleomorphic cells seen in high grade sarcomas to deceptively bland cells which resemble reactive fibroblasts [9,10]. The classic cytologic features of conventional melanoma which include predominantly dyscohesive clusters of cells, melanin pigments, intranuclear pseudoinclusions, eosinophilic macronucleoli, and binucleation or multinucleation are not frequently noted in spindle cell melanomas making the diagnosis more challenging and difficult (Table 1).

There are two distinct subtypes of malignant melanoma that differ clinic-pathologically and with respect to prognostic features. These include the spindle cell variant and desmoplastic melanoma [2,3,11]. Both these tumors show atypical, spindle malignant

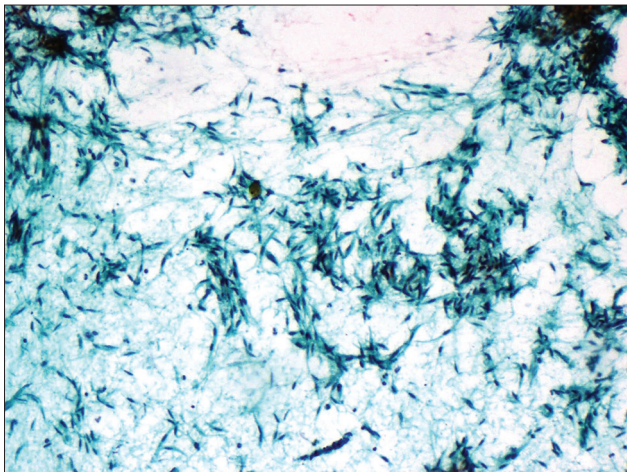


Figure 1: Clusters, fascicles and singly scattered spindle cells [Pap x40].

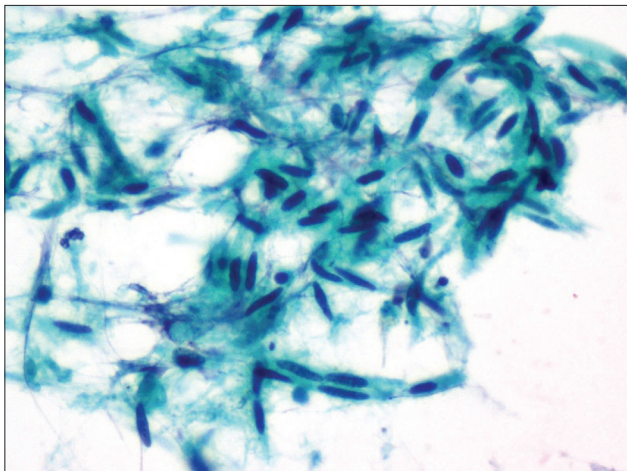


Figure 2: Spindle cells with elongated nuclei and scant cytoplasm [Pap x200].

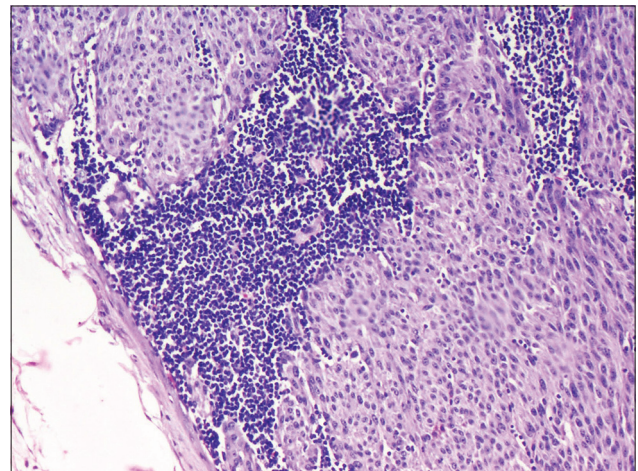


Figure 3: Lymphnode biopsy showing metastatic spindle cell melanoma [H & E x40].

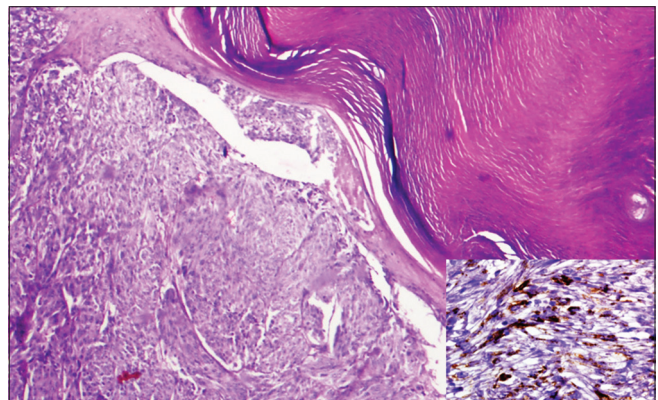


Figure 4: Skin lesion showing spindle cell melanoma. [H & E x40]. Inset shows HMB 45 positivity.

Table 1: Cytological findings of metastatic spindle cell melanoma compared with that of conventional melanoma

Cytological findings	Metastatic spindle cell melanoma	Metastatic conventional melanoma
Cellularity	Cellular	Cellular
Architectural pattern	Predominantly interlacing fascicles and whorls of spindle cells Dyscohesive clusters also may be present Few epithelioid cells clusters may be present	Predominantly dyscohesive clusters of polygonal cells
Cytoplasmic melanin pigment	Variable	Usually present
Nuclear pleomorphism	Bland to highly pleomorphic	Highly pleomorphic
Nuclear pseudoinclusions	Rare	Usually present
Prominent macronucleoli	Rare	Present
Binucleate & multinucleate cells	Absent	Present

Table 2: Differential diagnosis of spindle cell lesions

Lesion	Age	Site	Cytological features
Spindle cell squamous cell carcinoma	Elderly patients	Sun exposed surfaces- plaque/ tan to red nodule with ulcerated surface	Malignant spindled cells arranged in clusters or sheets with pleomorphic nuclei, eosinophilic cytoplasm & focal dyskeratotic cells.
Cutaneous, subcutaneous & deep Leiomyosarcoma	Adult patients	Extremities-thigh	Fascicular tissue fragments with moderate to scant cellularity, nuclei may be uniform or pleomorphic, cigar-shaped with abundant acidophilic or cyanophilic cytoplasm, characteristic perinuclear vacuoles, mitotic figures.
Dermatofibrosarcoma protruberans	Young adults	Trunk, proximal extremities, groin	Tight clusters of bland spindle cells embedded in a collagenous/ ibrillary and, often, metachromatic matrix along with dissociated, uniform, or slightly atypical spindle cells or bare nuclei.
Fibrosarcoma	Young adults	Head and neck, lower extremities, and the trunk	Spindle cells arranged in bundles, nuclei are round to oval, vesicular, moderate amount of tapering cytoplasm. Mitotic figures may be abundant and may also single cells with pleomorphic nuclei
Synovial sarcoma	Young patients	Around joints	Short, uniform spindle or epithelial cells with uniform vesicular nuclei and micronucleoli. Gland formation in biphasic lesions is a useful diagnostic feature.
Atypical fibroxanthoma	Elderly Young adults	Head or neck (elderly) trunk, extremities (young adults)	Plump spindle shaped cells with vesicular nucleus, arranged in fascicles, large polyhedral cells, few being vacuolated; bizarre giant cells (mononucleate or multinucleate) with hyperchromatic nuclei.

melanocytes. In desmoplastic melanoma, these malignant cells are intimately admixed with ropy and dense collagen fibrils which was absent in the present case.

Other spindle cell lesions that fall into the differential diagnosis include atypical fibroxanthoma, cutaneous leiomyosarcoma, dermatofibrosarcoma protruberans, synovial sarcoma and spindle cell squamous cell carcinoma. However the clinical features of each of these entities differ and must be correlated with cytology findings (Table 2).

The immunohistochemical markers used to confirm a melanocytic nature include S-100, HMB-45, Melan-A, and MART-1, the latter 3 being relatively specific but less sensitive markers for melanomas. Loss of expression of these makers has also been noted in spindle cell melanomas and few of them aberrantly express cytokeratin(10%) and smooth muscle actin [2,3,8]. In the present case HMB-45 was positive in the tumor cells.

CONCLUSION

Spindle cell melanoma may often be confused with other spindle cell lesions due to the lack of the characteristic features of conventional melanoma. A good clinical history is often helpful. FNAC is often used to document recurrent or metastatic disease and thus plays a very important role. Additional sources of diagnostic challenges, especially in the metastatic setting include varying degrees of cytologic atypia and possible cell type differences from the primary counterpart.

ACKNOWLEDGEMENT

We would kindly like to thank all the technical staff of the department of histopathology.

CONSENT

The examination of the patient was conducted according to the Declaration of Helsinki principles.

REFERENCES

1. Weissinger SE, Keil P, Silvers DN, Klaus BM, Möller P, Horst BA, et al. A diagnostic algorithm to distinguish desmoplastic from spindle cell melanoma. *Mod Pathol*. 2014;27:524-34.
2. Maurichi A, Miceli R, Camerini T, Contiero P, Patuzzo R, Tragni G, et al. Pure desmoplastic melanoma: a melanoma with distinctive clinical behavior. *Ann Surg*. 2010;252:1052-7.
3. Walia R1, Jain D, Mathur SR, Iyer VK. Spindle cell melanoma: a comparison of the cytomorphological features with the epithelioid variant. *Acta Cytol*. 2013;57:557-61.
4. Piao Y, Guo M, Gong Y. Diagnostic challenges of metastatic spindle cell melanoma on fine-needle aspiration specimens. *Cancer*. 2008;114:94-101.
5. Leong SP, Gershenwald JE, Soong SJ, Schadendorf D, Tarhini AA, Agarwala S, et al. Cutaneous melanoma: a model to study cancer metastasis. *J Surg Oncol*. 2011;103:538-49.
6. Murali R, Doubrovsky A, Watson GF, McKenzie PR, Lee CS, McLeod DJ, et al. Diagnosis of metastatic melanoma by fine-needle biopsy: analysis of 2,204 cases. *Am J Clin Pathol*. 2007;127:385-97.
7. Miller DD, Emley A, Yang S, Richards JE, Lee JE, Deng A, et al. Mixed versus pure variants of desmoplastic melanoma: a genetic and immunohistochemical appraisal. *Mod Pathol*. 2011;25:505-5.
8. Murali R, Shaw HM, Lai K, McCarthy SW, Quinn MJ, Stretch JR, et al. Prognostic factors in cutaneous desmoplastic melanoma: a study of 252 patients. *Cancer*. 2010;116:4130-8.
9. Dey P, Mallik MK, Gupta SK, Vasisht RK. Role of fine needle aspiration cytology in the diagnosis of tumors and tumor-like lesions. *Cytopathology*. 2004;15:32-7.
10. Loya A, Prayaga AK, Arora A, Sundaram C, Rao SI, Uppin SG, et al. Lymph node metastasis of soft tissue tumors: A cytomorphologic study. *Acta Cytol*. 2000;51:153-60.
11. Mathur S, Kapila K, Verma K. Accuracy of cytologic grading of spindle cell sarcomas. *Diagn Cytopathol*. 2003;29:79-83.

Copyright by Archana Shivamurthy, et al. This is an open-access article distributed under the terms of the Creative Commons Attribution License, which permits unrestricted use, distribution, and reproduction in any medium, provided the original author and source are credited.
Source of Support: Nil, **Conflict of Interest:** None declared.

Vulvar bowen disease treated successfully by Photodynamic therapy: about two cases

Hanane Bay Bay, Selma Benkirane, Loubna Benchat, Sara Elloudi, Mariame Meziane, Fatima Zahra Mernissi

Department of Dermatology, University Hospital Center Hassan II, Faculty of Medicine, Fez, Morocco

Corresponding author: Prof. Hanane Bay Bay, E-mail: hananebaybay@gmail.com

ABSTRACT

The Bowen's disease (BD) is a carcinoma in situ, its vulvar location is a therapeutic challenge. The ideal treatment should be not only effective, well tolerated, but also with optimal aesthetic result, in this context, photodynamic therapy (PDT) is an attractive therapeutic strategy thanks to unique properties of tumor selectivity. Imiquimod can be a potential treatment modality for lesions that are difficult to treat with surgical excision. We report two cases of patients effectively treated with PDT and Imiquimod 5% as additional therapy for vulvar MB.

Key words: Bowen's disease; Vulva; Photodynamic therapy; Imiquimod; Carcinoma in situ

INTRODUCTION

Bowen Disease (BD) is a carcinoma in situ; its vulvar location is a therapeutic challenge [1,2]. Dynamic phototherapy (PDT) is an interesting therapeutic strategy thanks in particular to the original properties of tumor selectivity [3,4]. Also, Imiquimod can be a potential treatment modality for lesions that are difficult to treat with surgical excision [5,6].

We report the cases of two patients effectively treated with PDT and Imiquimod 5% as a therapeutic adjunct for vulvar MB.

CASE REPORT

Case 1

47 year old woman, with no notable pathological history, who had vulvar pruritus that had been evolving for 1 year. The dermatological examination showed a plate at the level of the large lip, 6 cm, erythematous well limited, regular edges surmounted by a whitish coating, non-peelable, taking almost the entire plate (Fig. 1).

Case 2

57 years old woman, diabetic and hypertensive, who had a pruritus vulva evolving since 1 year. The dermatological examination had objectified a whitish coating, not decolable, sitting at the level of the small lip (Fig. 2).

The dermoscopy showed in both patients a homogeneous glomerular vascularization in favor of a bowen disease, confirmed by the histological examination. The histopathological findings revealed papillomatosis, koilocytosis and clumping cells with atypical nuclei (Fig. 3).

The patients had benefited from a conservative treatment with 2 sessions of PDT with as photosensitizing agent the methyl aminolevulinate at a rate of 100 J/cm² at one week intervals. The suites were simple. An addition by Imiquimod 5% for 3 months was introduced. A histological control, performed in the 2 patients, after 3 months of treatment, had not objectified tumor cells. The follow up is 2 years for the first case and 1 year and half for the second (Figs. 4 - 6).

How to cite this article: Bay Bay H, Benkirane S, Benchat L, Elloudi S, Meziane M, Mernissi FZ. Vulvar bowen disease treated successfully by Photodynamic therapy: about two cases. Our Dermatol Online. 2019;10(2):163-165.

Submission: 11.09.2018; **Acceptance:** 22.11.2018

DOI:10.7241/ourd.20192.13

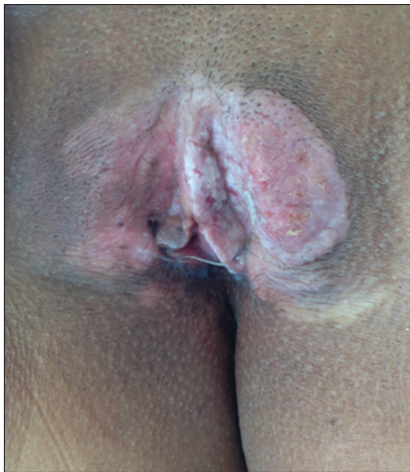

Figure 1: Erythroleukoplastic large plaque of the vulva.

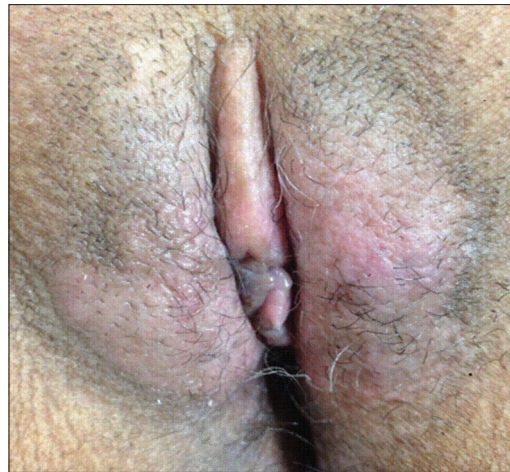

Figure 4: Clinical control after PDT with good improvement.

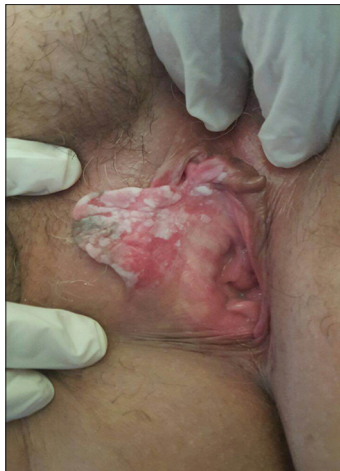

Figure 2: Erythroleukoplastic of the small lip and vulva.

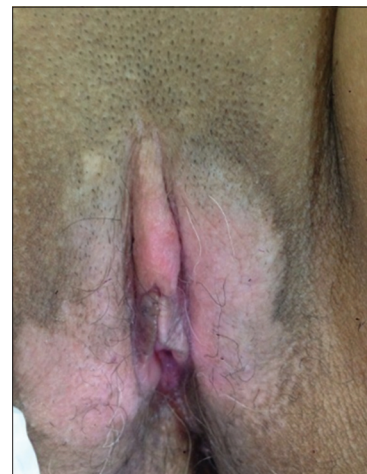


Figure 5: Clinical control after supplement treatment with imiquimod.

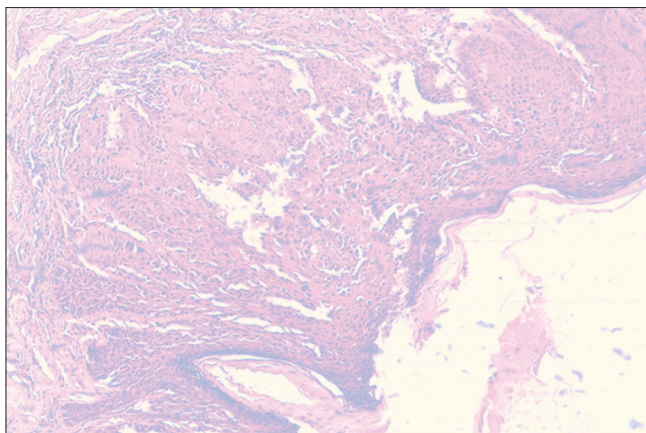


Figure 3: Histology: Papillomatosis, koilocytosis and clumping cells with atypical nuclei. H&E x10.

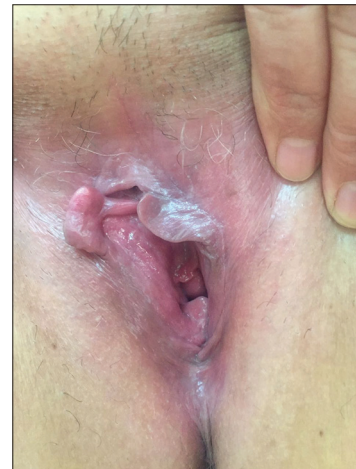

Figure 6: Clinical control after PDT and Imiquimod with good improvement.

Prior to the study, patient gave written consent to the examination and biopsy after having been informed about the procedure.

DISCUSSION

BD or vulvar carcinoma in situ usually manifests as a single, proliferating, leucoplactic or erythroplastic

plaque that extends centrifugally very progressively without central healing [1,2].

There are several therapeutic modalities, surgical, local, and non-surgical ablative [3-6].

The therapeutic decision takes into account the size and number of lesions, and the age of the patient, but also the experience of the practitioner and the choice of the patient as well as his immune status. Although it has the advantage of histological control, surgery at the vulvar level can be debilitating and mutilating with severe consequences [4-6]. Dynamic phototherapy (PDT) is increasingly used to treat superficial cancers of the skin. It acts through a photosensitizer that triggers a phototoxic reaction that produces singlet oxygen and other free radicals with cytotoxic and vasculotoxic effects leading to necrosis and cell apoptosis [7-9].

Several cases of bowen disease favorably treated with PDT have been reported but few of them related to the genital location [10].

PDT allowed a non-invasive treatment, a satisfactory aesthetic and functional result even if it's extensive form [7]. We specify that treatment with Imiquimod alone requires a more aggressive treatment, of prolonged duration and offers only partial results in the literature. However, in some report cases, Imiquimod allowed an interesting result in pagetoid form and small area [5,6]. For our extensive cases, we opted for a PDT with a supplement therapy by Imiquimod due to its immunomodulatory action to potentiate the effect of PDT and minimize the risk of recurrence. Finally, further studies are needed to develop its use in the treatment of Bowen's Disease in the area vulvar with and without therapeutic adjuncts.

CONCLUSION

PDT is an effective and non-invasive therapeutic method for large bowen vulvar disease, providing a good aesthetic and functional outcome. Combined therapy with Imiquimod as immunomodulatory, potentiate the effect of PDT and minimize the risk of recurrence.

Consent

The examination of the patient was conducted according to the Declaration of Helsinki principles.

REFERENCES

1. Strayer DS, Santa Cruz DJ. Carcinoma in situ of the skin: a review of histopathology. *J Cutan Pathol.* 1980;7:244-59.
2. Krüger-Corcoran D, Vandersee S, Stockfleth E. Precancerous tumors and carcinomas in situ of the skin. *Internist (Berl).* 2013;54:671-82.
3. HK Kang, J-H Yun, Y-M Son, JY Roh, Jk Lee, Photodynamic Therapy for Bowen's Disease of the Vulva Area. *Ann Dermatol.* 2014; 26: 241-5.
4. Bath-Hextall FJ, Matin RN, Wilkinson D, Leonardi-Bee J. Interventions for cutaneous Bowen's disease. *Cochrane Database Syst Rev.* 2013;6:CD007281.
5. Yadav P, Mendiratta V, Rana S, Makhija M. Pagetoid Bowen's disease of vulva: Excellent response to imiquimod. *Indian J Dermatol Venereol Leprol.* 2016; 82: 734-7.
6. Kishi C, Shimizu A, Kato M, Amano H, Ishikawa O. Successful treatment of genital Bowen's disease with imiquimod 5% cream. *Int J STD AIDS.* 2015;26:752-4.
7. López N, Meyer-Gonzalez T, Herrera-Acosta E, Bosch R, Castillo R, Herrera E. Photodynamic therapy in the treatment of extensive Bowen's disease. *J Dermatolog Treat.* 2012;23:428-430.
8. Basset-Seguín N. Revue Panoramique de la PDT Principe, photosensibilisateurs, sources de lumières et indications validées en dermatologie, *Ann Dermatol Vénérolog.* 2013;140(Supp 2):223-8.
9. Alisson RR, Morissy K. Photodynamic therapy (PDT), PDT mechanisms. *Clin Endosc.* 2013;46:24-5.
10. Kim YJ, Kang HY, Lee ES, Kim YC. Photodynamic therapy for treatment of Bowen's disease. *Korean J Dermatol.* 2007;45:237-41.

Copyright by Hanane Bay Bay, et al. This is an open-access article distributed under the terms of the Creative Commons Attribution License, which permits unrestricted use, distribution, and reproduction in any medium, provided the original author and source are credited.
Source of Support: Nil, **Conflict of Interest:** None declared.

Squamous cell carcinoma developing in an epidermal inclusion cyst

Hubert Daisley Jr¹, Arlene Rampersad¹, Oneka Acco¹, Edmond Ramirez², Dinelle Sirjuesingh³

¹Department of Pathology, General Hospital, San Fernando, Trinidad. W.I, ²Department of Orthopaedy, University of The West Indies, St Augustine Trinidad. W.I, ³Department of Urology, University Of The West Indies St Augustine, Trinidad W.I

Corresponding author: Prof. Hubert Daisley jr, E-mail: profhdjr@yahoo.com

ABSTRACT

Epidermal inclusion cysts and squamous cell carcinoma of the skin are very common pathological lesions. However a squamous carcinoma arising in an epidermal inclusion cyst is a rare finding. We present a case of the malignant transformation of an epidermal inclusion cyst into a squamous cell carcinoma over a 25 year period in a 67 year old male. A brief review of the literature and theories postulated as to its histogenesis are undertaken.

Key words: Epidermal inclusion cyst; Malignant Transformation; Squamous cell Carcinoma.

INTRODUCTION

Epidermal inclusion cysts are the most common keratin containing cyst found in the skin leading sebaceous cysts and dermoid cysts. They are often referred to as implantion cysts since their major histogenesis depends on the implantation of epidermis into the dermis following trauma. Carcinoma is ubiquitous, but rarely seen developing from the epithelium of epidermal inclusion cysts. Herein we report a case of a squamous cell carcinoma developing from an abdominal wall epidermal inclusion cyst.

CASE REPORT

Case History

A 67-year-old male was referred to the General Surgery outpatient clinic at the General Hospital in January for a left inguinal hernia. Five months later he developed a large painful abdominal wall exophytic ulcerated lesion with necrotic borders, which was located in the left upper quadrant of his abdominal wall.

One year prior to this event he was treated for benign prostatic hyperplasia by the Urological team and

mention was made of a small palpable subcutaneous lump in the abdominal wall region which was the present location of this fungating mass. There were no raised skin lesions or plaques at this region seen by the Urological team, one year ago. The patient divulged that the subcutaneous lump being neither worrisome nor bothersome, was present for more than 20 years. A computed tomography of the patient's abdomen then revealed a 6.0 cm x 2.2 cm cystic focus within the subcutaneous tissue of the left upper quadrant consistent with an epidermal inclusion cyst. A trans-abdominal ultrasound performed six months prior his death similarly described the lesion as a structure of mixed echogenicity 2.3 cm x 1.0 cm (Fig. 1).

A wedge biopsy of the exophytic abdominal mass was performed under local anesthesia which was reported as a well differentiated squamous cell carcinoma occupying the dermis with sparing of the overlying epidermis. A metastatic squamous cell carcinoma to the region was entertained. The patient passed away suddenly a month after surgical biopsy of the exophytic mass and a post mortem examination was performed.

How to cite this article: Daisley Jr H, Rampersad A, Acco O, Ramirez E, Sirjuesingh D. Squamous cell carcinoma developing in an epidermal inclusion cyst. Our Dermatol Online. 2019;10(2):166-169.

Submission: 06.08.2018; **Acceptance:** 06.10.2018

DOI:10.7241/ourd.20192.14

Investigations

At Post Mortem examination there was a 15 cm x 11 cm raised nodular lesion with an ulcerated center in his left flank (Fig. 2). There was no communication seen between this abdominal wall mass and any of the abdominal or pelvic organs. A suitable section was taken for histological analysis. Gross examination of all internal organs found no evidence of distant or lymph node metastasis, or a primary site lesion.

Multiple sections of the autopsy specimen were examined which showed a well differentiated invasive squamous cell carcinoma not communicating from the overlying skin, with copious amounts of lamellar keratin, arising from the epidermal inclusion cyst wall. The neoplasm had invaded deep into the subcutaneous tissue. There was no evidence of the tumor arising from a skin appendage, but its origin from the epidermal cyst wall was clearly visible (Figs. 3 - 5).

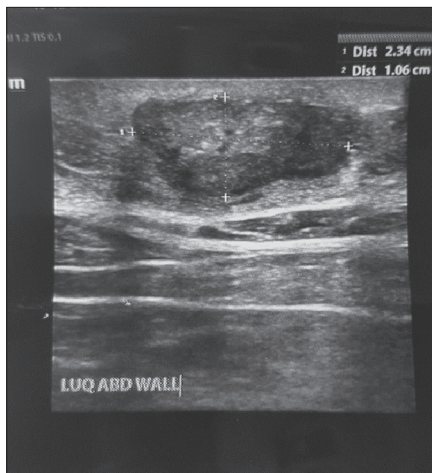


Figure 1: The ultrasonographic images of abdominal wall mass.

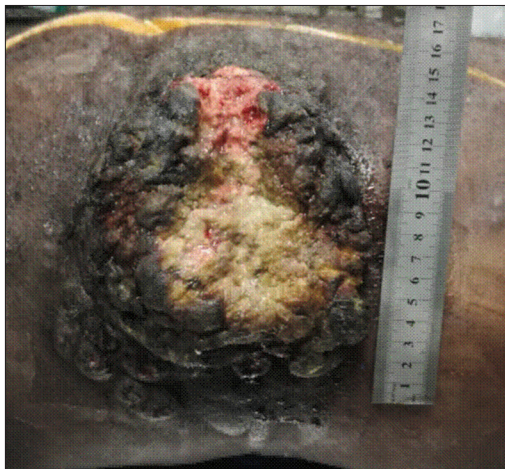


Figure 2: The post mortem images of abdominal wall mass.

Prior to the study, patient gave written consent to the examination and biopsy after having been informed about the procedure.

DISCUSSION

The figures above clearly demonstrate an invasive squamous cell carcinoma arising from an epidermal inclusion cyst. At autopsy a search for primary tumor sites were negative. Multiple sections of the tumor were examined but there was no indication that the squamous cell carcinoma had arisen from a skin appendage tumor [1]. This was not the case since at no time during the 20 plus years of the evolution of the neoplasm, was there any raised lesion on the skin at the site of development of the invasive squamous cell carcinoma.

Squamous cell carcinoma often arises in regions of the body exposed to ultra violet radiation [2] or

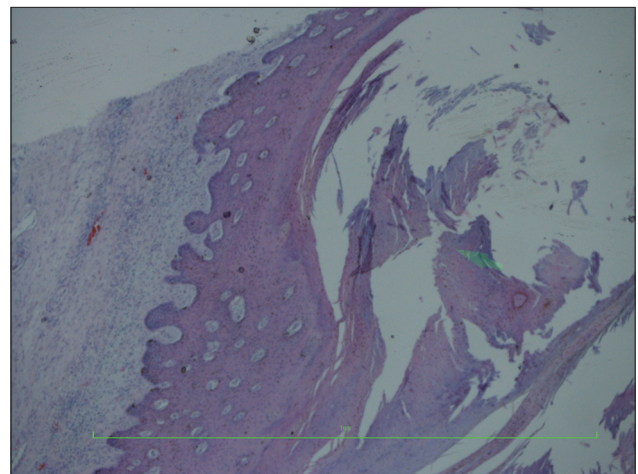


Figure 3: Epidermal inclusion cyst wall with lamellar keratin. H&E

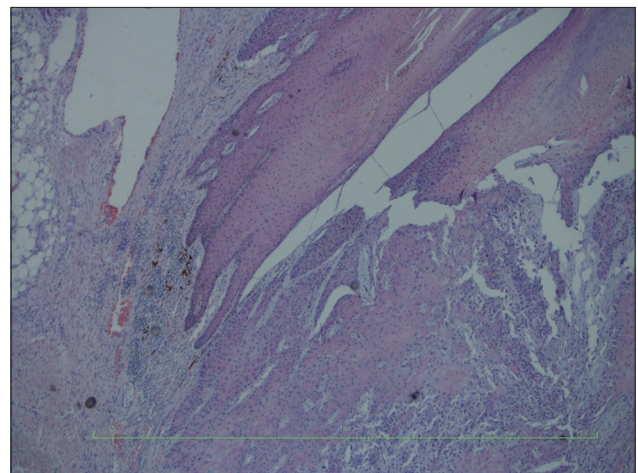


Figure 4: Malignant degeneration of the epidermal inclusion cyst wall. H&E

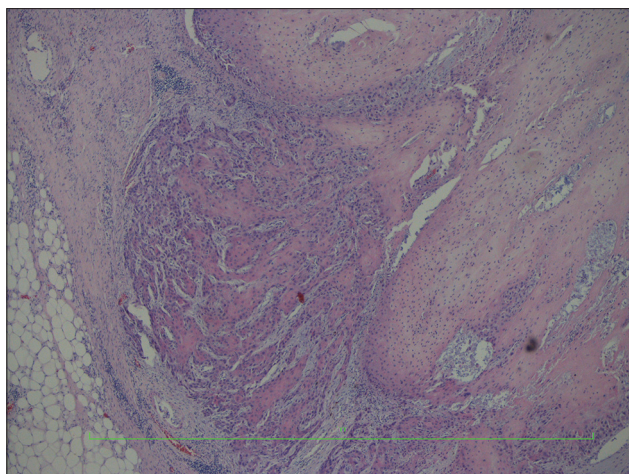


Figure 5: Well differentiated invasive squamous cell carcinoma developing in epidermal inclusion cyst wall. H&E

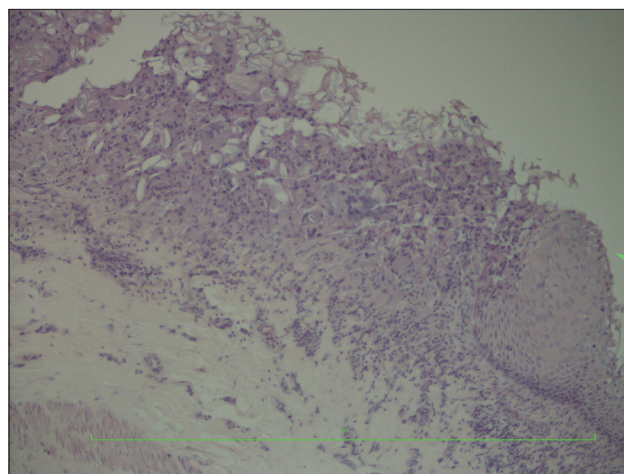


Figure 6: An epidermal inclusion that has ruptured producing a granulomatous reaction to keratin. H&E

regions of chronic irritation with repeated regeneration of squamous epithelium such as what occurs in a Marjolin's ulcer [3].

The Human Papilloma Virus (HPV) also has a promoting role in squamous cell carcinogenesis [4]. It is most unlikely that ultraviolet radiation plays a role in inclusion cysts malignant transformation since these cysts are found distal to the dermis and are therefore not exposed to sunlight.

Chronic irritation most likely has a role in epidermal inclusion cysts malignant degeneration. Chronic irritation by squeezing produces an intense granulomatous reaction to keratin (Fig. 6). Probably this chronic irritation over a protracted number of years together with some unknown promoting factors, possibly HPV or genetic factors, are responsible for their malignant transformation.

Carcinogenesis is ubiquitous and it is therefore not surprising that other skin cancers have been reported to develop in epidermal inclusion cysts, but to a far lesser extent. Neoplasms such as Basal cell carcinoma, Mycosis Fungoides, Merkel Cell carcinoma and Melanomas have been reported to originate from epidermal inclusion cysts, but to a far lesser incidence than squamous cell carcinoma [1,5-7]. This may be so since the main promoting agent of these skin carcinomas, namely ultraviolet radiation, [2,8] is not accessible to epidermal inclusion cysts in their deep dermal locations.

Squamous cell carcinoma developing in epidermal inclusion cysts are low in incidence with occurrence ranging from 0.011 to 0.045%. [9]. It seems that

prolong chronic irritation, in this case 20 plus years, seems to be a major promoting factor. A rapid increase in size of an existing lesion is an ominous sign that malignant transformation of an epidermal inclusion cyst is occurring, and should also be considered when the cyst exhibits contrast enhancement on imaging [10]. It would be wise therefore to excise epidermal inclusion cysts wherever they are located and subject them to histological examination since malignant transformation can occur.

CONCLUSION

Epidermal inclusion cysts are common benign skin lesions. They should be excised and subjected to histological examination for malignant transformation, although rare, does occur. A rapidly increasing size of an existing inclusion cyst is an ominous sign that malignant transformation might be occurring.

CONSENT

The examination of the patient was conducted according to the Declaration of Helsinki principles

REFERENCES

1. Cotton D. Troublesome tumors 1: Adnexal tumors of the skin. *J Clin Pathol.* 1991; 44:543-48.
2. Martens MC, Seebode C, Lehmann J, Emmert S. Photocarcinogenesis and skin cancer prevention strategies: an update. *Anticancer Res.* 2018;38:1153-8.
3. Pekarek B, Buck S, Osher L. A comprehensive review on marjolin's ulcers: diagnosis and treatment. *J Am Col Certif Wound Spec.* 2011;3:60-4.
4. Westra WH. The changing face of head and neck cancer in the

- 21st century: the impact of HPV on the epidemiology and pathology of oral cancer. *Head Neck Pathol.* 2009;3:78-81.
5. Swygert KE1, Parrish CA, Cashman RE, Lin R, Cockerell CJ. Melanoma in situ involving an epidermal inclusion (infundibular) cyst. *Am J Dermatopathol.* 2007;29:564-5.
 6. Aljufairi E, Alhilli F. Merkel Cell Carcinoma Arising in an Epidermal inclusion cyst. *Am J Dermatopathol.* 2017;39:842-4.
 7. Li Liau J, Altamura D, Ratynska M, and Verdolinia R. Basal cell carcinoma arising from an epidermal cyst: when a cyst is not a cyst. *Case Rep Dermatol.* 2015;7:75-8.
 8. Daya-Grosjean L1, Sarasin A. The role of UV induced lesions in skin carcinogenesis: an overview of oncogene and tumor suppressor gene modifications in xeroderma pigmentosum skin tumors. *Mutat Res.* 2005;571:43-56.
 9. Anastasios K, Alexandra G, Anthony K, Efthimios S. Malignant transformation in a typical epidermal cutaneous cyst. *J Med Case Rep.* 2012;3:254-6.
 10. Hoon Roh T, Sook Park Y, Yong Park Y, Hoon Kim S, Jong Chang H. Intracranial squamous cell carcinoma arising in a cerebellopontine angle epidermoid cyst: A case report and literature review. *Medicine (Baltimore).* 2017;96: e9423.

Copyright by Hubert Daisley Jr, et al. This is an open-access article distributed under the terms of the Creative Commons Attribution License, which permits unrestricted use, distribution, and reproduction in any medium, provided the original author and source are credited.
Source of Support: Nil, **Conflict of Interest:** None declared.

Unusually localised cutaneous multifocal squamous cell carcinoma

Radhika Varma, N. Asokan, A. Sarin, Nadiya Rahman

Department of Dermatology Venereology and Leprosy, Government Medical College, Thrissur, India

Corresponding author: Dr. Radhika Varma, E-mail: drradhikavarma@gmail.com

ABSTRACT

Skin cancer is predominantly a disease of the elderly and accounts for about 53% of all deaths in those more than 65 years old in Whites. Although it classically presents as a solitary painless nonhealing ulcer, varied presentations as plaques, nodules and warty lesions are not rare. Herein we report a case of an otherwise healthy elderly female with cutaneous squamous cell carcinoma (SCC) which presented as multiple, slowly enlarging painless non-ulcerated skin nodules localized to the anteromedial aspect of right leg. We wish to highlight that uncharacteristic presentations of cutaneous SCC may occur even in immunocompetent individuals.

Key words: Skin nodules; Carcinoma; Multifocal carcinoma

INTRODUCTION

Squamous cell carcinoma [SCC] is the second most common cutaneous neoplasm and accounts for about 20% of all skin malignancies [1]. Cutaneous SCC is a malignant tumor of keratinizing epidermal cells. Clinical behavior of SCC can vary from indolent to aggressive metastatic types [2]. Multiple cutaneous type is a rare presentation of SCC and arises either as a de novo multicentric tumour or following spread from primary SCC elsewhere via shelving, conduit spread, local lymphatic metastasis or disseminated metastasis [3]. Herein, we report a patient with long standing multiple skin nodules localized to the right leg which were later diagnosed as SCC.

CASE REPORT

A 75 year old woman was seen in dermatology OPD for multiple, firm, asymptomatic swellings on right shin, slowly enlarging over the past 20 years. She had no previous scars or skin diseases at that site. Examination revealed fourteen erythematous and skin coloured nodules of sizes ranging from 2x1cm to 4x3 cm on upper half of anterior and medial aspects of right leg.

Some nodules had central keratin filled craters and the surrounding skin was mildly erythematous (Fig. 1). She had mild ichthyosis of both legs. We considered dermatofibroma, nodular basal cell carcinoma and indolent cutaneous lymphomas as differential diagnoses. Haemogram was normal except for an erythrocyte sedimentation rate of 130 mm in first hour. Chest x-ray was normal. Intradermal tuberculin test using 0.1ml of purified protein derivative was negative. Ultrasonogram of abdomen showed mild enlargement of right inguinal lymph nodes and fine needle aspiration cytology (FNAC) from these nodes did not show any abnormal cells. Serum was negative for HBsAg, HIV and Hepatitis A and C viruses. FNAC from the skin nodules showed cells of SCC (Fig. 2).

She underwent wide excision of tumour nodules followed by skin grafting (Fig. 3). Histopathology of the tissue showed atypical squamous epithelium in nests, invading adjacent stroma (Fig. 4). The squamous cells had large, vesicular and hyperchromatic nuclei, prominent nucleoli and anisonucleosis with occasional individual cell keratinisation. The stroma showed dense infiltration by lympho-plasma cells. Keratin pearls and mitoses were seen suggestive of a moderately

How to cite this article: Varma R, Asokan N, Sarin A, Rahman N. Unusually localised cutaneous multifocal squamous cell carcinoma. Our Dermatol Online. 2019;10(2):170-172.

Submission: 03.09.2018; **Acceptance:** 18.11.2018

DOI:10.7241/ourd.20192.15

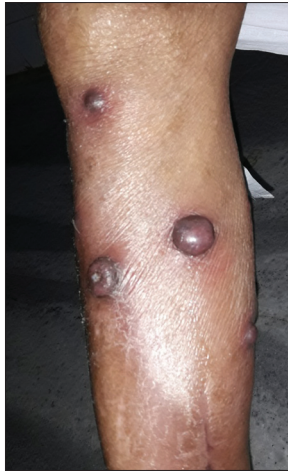

Figure 1: Erythematous nodules on leg showing central crater with adherent scaling. Surrounding skin shows erythema and ichthyosis.

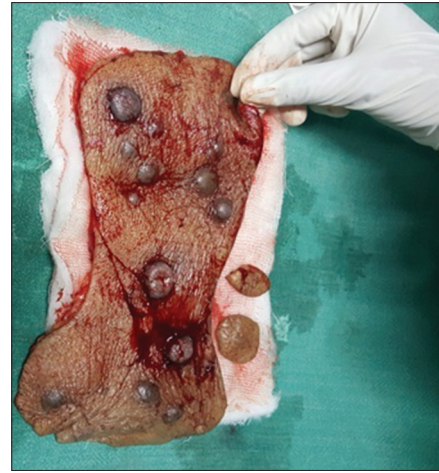

Figure 3: Wide excision specimen of skin of right leg showing fourteen discrete nodules.

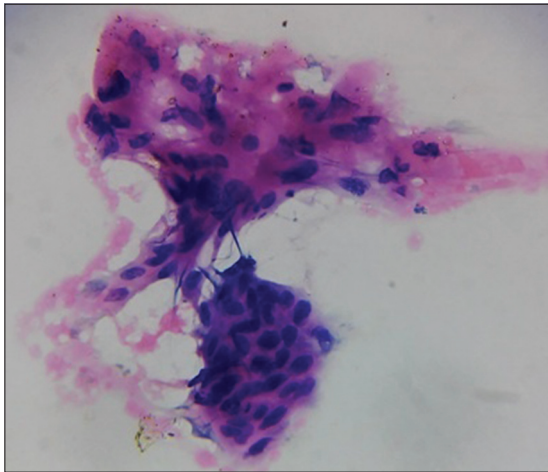


Figure 2: FNAC smear showing atypical squamous cells in cluster. Individual cells have moderate eosinophilic cytoplasm and central pleomorphic and hyperchromatic nucleus. H&E Stain. X 400 magnification.

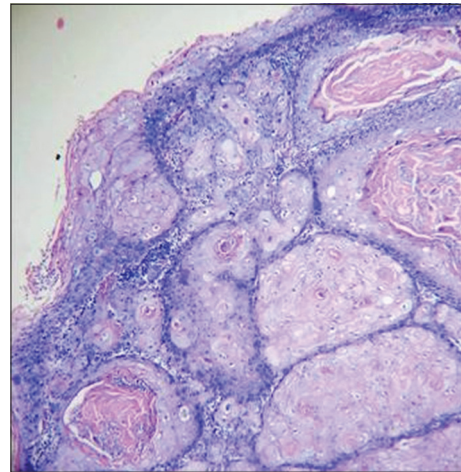


Figure 4: Nests of atypical squamous cells from epidermis invading stroma in masses. Dermis contain dense infiltrate of lymphocytes and plasma cells. H&E stain, x 100 magnification.

differentiated squamous cell carcinoma. The resected skin margins were free of neoplastic infiltration. Post operative period was uneventful and follow up of one and half years showed no recurrence.

DISCUSSION

SCC arises more commonly on sun exposed areas of skin like head, neck and arms [3]. Chronic ultraviolet radiation, human papiloma virus (HPV) infection and immunosuppression play a major role in its pathogenesis. Other risk factors for SCC include exposure to oral psoralens, arsenic, hydrocarbons, coal tar products, solid organ transplantation and diseases like chronic lymphocytic leukemia [1,3]. Patients with genetic diseases like xeroderma pigmentosum, epidermodysplasia verruciformis and

oculocutaneous albinism have a higher incidence of this neoplasm [3,4]. SCC also arise on long standing cases of lupus vulgaris, discoid lupus erythematosus, herpes zoster and chronic stasis dermatitis [1,3,4]. Fair skin, older age, blue eyes and red-blond hair are other factors which correlate with occurrence of SCC [1]. Individuals with human immunodeficiency virus infection have a substantially increased risk for developing aggressive tumor with high recurrence rates and increased metastasis.

Multiple cutaneous SCC has been reported in patients with psoriasis and vitiligo treated with oral psoralens and UV radiation, with HPV infections, interferon γ receptor 2 deficiency and following cutaneous metastasis from vulvar SCC [3-5]. It has also been reported in patients receiving treatment with ustekinumab, voriconazole and sorafenib [6-8].

Cutaneous metastases, occur only in 0.7% to 9% of all malignancies and usually develop following the diagnosis of a primary tumour [3]. In women, the most common sources of cutaneous metastases are carcinomas of breast, colon and ovary. Presence of a metastatic cancer without a known primary site of origin despite a standardized diagnostic workup is termed as carcinoma of unknown primary site (CUPS) [9]. CUPS usually presents with rapidly developing widespread nodules or tumors which are usually asymptomatic, rarely painful and tender [3]. Diagnosis of such metastasised cutaneous SCC relies on histopathologic evaluation of involved skin wherein tumors may show features of the underlying tumor or may have an anaplastic appearance. An indolent course of almost two decades and localization to one limb rendered a diagnosis of CUPS unlikely in our case. Hence, we consider our patient to have had a primary cutaneous multifocal SCC. We could not identify any reason for the multifocal presentation of the tumour in leg.

Our case is unusual in many ways. Leg is an uncommon site for primary SCC. Localization to one site, a multifocal presentation with absence of ulceration and infiltration of the nodules, absence of regional lymph node metastasis in spite of a long course of are other unusual features in our patient.

Cutaneous SCC varies both in its manifestations and course. Hence, SCC should be considered in the differential diagnosis of all skin tumours particularly among elderly individuals.

REFERENCES

1. Syrigos KN, Tzannou I, Katirtzoglou N, Georgiou E. Skin cancer in the elderly. *In Vivo*. 2005;19:643-52.
2. Cassarino DS, Derienzo DP, Barr RJ. Cutaneous squamous cell carcinoma: A comprehensive clinicopathologic classification: Part One. *J Cutan Pathol*. 2006;33:191-206.
3. Kaur J, Sharma N, Sharma S. Multiple cutaneous squamous cell carcinomas: Primary carcinomas versus cutaneous metastasis. *J Cancer Res Ther*. 2012;8:300-2.
4. Üstüner P, Dilek N, Güçer H. Genital squamous cell carcinoma presenting with multicentric ulcers: an unusual manifestation of skin malignancy. *Indian Dermatol Venereol Leprol* 2012;78:195-7.
5. Toyoda H, Ido M, Nakanishi K, Nakano T, Kamiya H, Matsumine A, et al. Multiple cutaneous squamous cell carcinomas in a patient with interferon gamma receptor 2 (IFN gamma R2) deficiency. *J Med Genet*. 2010;47:631-4.
6. Young L, Czarnecki D. The rapid onset of multiple squamous cell carcinomas in two patients commenced on ustekinumab as treatment of psoriasis. *Australas J Dermatol*. 2012;53:57-60.
7. Morice C, Acher A, Soufir N, Michel M, Comoz F, Leroy D, et al. Multifocal aggressive squamous cell carcinomas induced by prolonged voriconazole therapy: a case report. *Case Rep Med*. 2010;2010:351084.
8. Dubauskas Z, Kunishige J, Prieto VG, Jonasch E, Hwu P, Tannir NM. Cutaneous squamous cell carcinoma and inflammation of actinic keratoses associated with sorafenib. *Clin Genitourin Cancer*. 2009;7:20-3.
9. Natoli C, Ramazzotti V, Nappi O, Giacomini P, Palmeri S, Salvatore M, et al. Unknown primary tumors. *Biochim Biophys Acta - Rev Cancer*. 2011;1816:13-24.

Copyright by Radhika Varma, et al. This is an open-access article distributed under the terms of the Creative Commons Attribution License, which permits unrestricted use, distribution, and reproduction in any medium, provided the original author and source are credited.

Source of Support: Nil, Conflict of Interest: None declared.

A case report of Baboon Syndrome due to azithromycin

Munise Daye¹, Koray Durmaz¹, Pembe Oltulu²

¹Department of Dermatology, Necmettin Erbakan University Meram Faculty of Medicine, Konya, Turkey, ²Department of Pathology, Necmettin Erbakan University Meram Faculty of Medicine, Konya, Turkey

Corresponding author: Dr. Munise Daye, E-mail: dr_munise@yahoo.com

ABSTRACT

Baboon syndrome is a type IV delayed hypersensitivity reaction and characterized by asymptomatic erythematous maculopapular rash due to drugs. The rash typically involves flexural areas, gluteal and perineal regions. This eruption, may occur within hours to days of exposure to suspecting drug and resolves rapidly by discontinuation of the triggering drug. We present a 76-years-old male patient who admitted to our clinic with symmetrical, erythematous eruption and was diagnosed Baboon syndrome by clinical and histopathological findings. The eruption disappeared in 1 week after appropriate treatment via intravenous methyl prednisolone, oral antihistamines and topical steroids.

Key words: Dermatitis; Drug eruption; Azithromycin

INTRODUCTION

Symmetrical drug related intertriginous and flexural exanthema (SDRIFE) or Baboon syndrome (BS) is a form of systemic contact dermatitis represents a delayed hypersensitivity reaction and described with exanthematous involvement of gluteal and intertriginous areas after ingestion or systemic absorption of a contact allergen in a sensitized individual [1-3]. We report a case of a 76-year-old male patient with BS after systemic use of azithromycin.

CASE REPORT

A-76-year-old male patient was submitted to our clinic with a 10 days history because of erythematous eruption on his neck, dorsum of hands, forearms and penis and scrotal area. His past medical history was significant for a recently diagnosed upper respiratory tract infection, pharyngitis for which he was prescribed azithromycin 500 mg tablets once a day for 3 days about 10 days prior. On the third day of initiating treatment with azithromycin the lesions started on his neck and dorsum of hands

and spread to his inner thighs, antecubital regions of forearms, penis and scrotal areas in 3 days (Fig. 1). According to his previous medical record, he had not been prescribed topical and/or oral azithromycin before. There was no personal and/or family history of atopic diatheses or any other drug hypersensitivity. At first examination there was mild dyspnea due to asthma, but no fever or another systemic symptoms. Complete blood count, sedimentation, CRP, routine biochemistry including thyroid, hepatic and renal function tests, urinalyses were normal. Histopathologic examination of the biopsy from the affected site of the left forearm showed pustule formation at the subcorneum and variable superficial perivascular infiltrate of eosinophils in the dermis (Fig. 2). After clinicopathologic correlation, the patient was diagnosed BS (SDRIFE). He was treated with 40 mg methyl prednisolone for 3 days and then 20 mg methyl prednisolone for 5 days intravenous infusion. Mild topical steroids and systemic antihistamines was also added to treatment. The eruption appeared to have cleared with desquamation in 1 week and patient's subjective symptoms like burning and pruritus was resolved (Fig. 3).

How to cite this article: Daye M, Durmaz K, Oltulu P. A case report of Baboon Syndrome due to azithromycin. Our Dermatol Online. 2019;10(2):173-175.

Submission: 10.08.2018; **Acceptance:** 31.12.2018

DOI:10.7241/ourd.20192.16

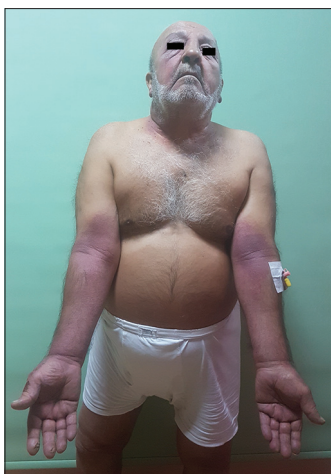

Figure 1: Symmetrical erythematous rash of the bilateral flexural regions and neck involvement.

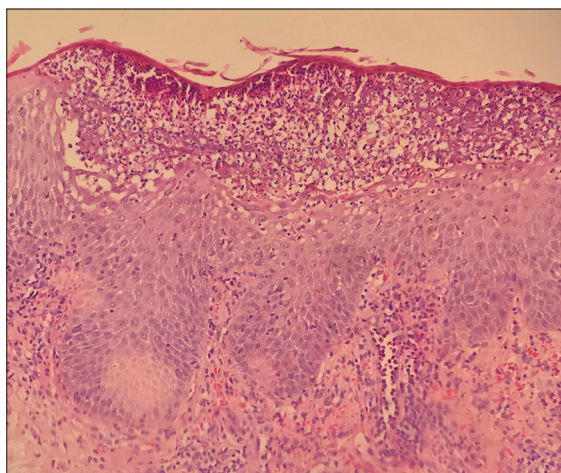


Figure 2: Pustule formation at the subcorneum and superficial perivascular infiltrate of eosinophils in the dermis.

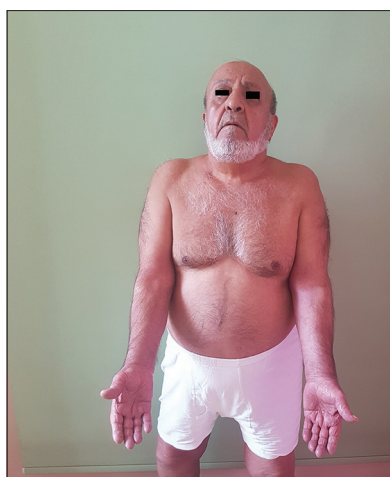

Figure 3: The eruption dramatically resolved after the treatment.

Prior to the study, patient gave written consent to the examination and biopsy after having been informed about the procedure.

DISCUSSION

BS term was introduced in 1984 by Andersen et al. as a peculiar form of systemic contact dermatitis characterized by symmetric and diffuse erythematous maculopapular eruption on the buttocks and flexural areas after re-exposure of a contact allergen. Andersen and his coauthors presented three patients who had developed generalized erythematous maculopapular rash located in glutea and intertriginous areas, provoked by mercury, nickel and ampicillin. They named the eruption as BS cause of lesional presentation of the patient's buttocks like to the red appearance of a baboon [4]. As we can see from reported cases in the literature BS mostly presented 18 months of age to 84 years old patients, it can be seen at any age and both sexes. SDRIFE (symmetrical drug-related intertriginous and flexural exanthema) term has also been used as acronym BS in many literatures, proposed to describe such cases of BS occurring after systemic exposure of drugs and contact allergens. Although the precise pathogenetic mechanisms are still unknown for this reaction, it has been suspected to develop as a result of a T-cell mediated type IV hypersensitivity reaction. Diagnostic criteria for SDRIFE and clinical presentations are (I) Exposure to a systemically administered drug for the first time or repeated doses (contact allergens are excluded); (II) sharply bordered erythema of the gluteal/perineal areas and/or, V-shaped erythema located on the inguinal/perigenital areas; (III) in addition, involvement of at least one different intertriginous/flexural region; (IV) symmetry and (V) Absence of any systemic symptoms and signs such as pyrexia or eosinophili. SDRIFE, mostly observed after beta-lactam antibiotics such as penicillines or cephalosporine. The diagnosis of this eruption is generally based on the clinical presentation and medical history of patients. Suspected sensitizing agents cannot be found in most of cases, patch tests or prick tests are negative in 1/3-1/2 of patients and predictive values of the tests depends on the clinical features of the adverse reaction and on the particular drug tested. The histopathology of SDRIFE typically shows an superficial perivascular infiltrate including neutrophils and eosinophils, on the other hand subcorneal pustules, vacuolar changes and hydropic degeneration in the basal cell layer were also described [3,5,6]. The latency period generally varies from hours to a few days after exposure to the suspected agent. In our case, this duration was three days and the patient's lesions started on his neck and dorsum of hands and spread to inner

face of thighs, antecubital regions, scrotal and pubic areas in a few days. He has not any systemic symptoms and eosinophilia too. In differential diagnosis, fixed drug eruption (FDE) excluded absence of acral, genital or mucosal round oval plaques and bullous lesions. We did not consider other systemic drug eruptions like acute generalized exanthematous pustulosis (AGEP) or drug rash with eosinophilia (DRESS) absence of a widespread rash with accompanying systemic changes in this case. We diagnosed BS (SDRIFE), the patient's clinical presentation and histopathological findings such as pustule formation at the subcorneum and variable superficial perivascular infiltrate of eosinophils in the dermis.

CONCLUSION

The inciting agent causing BS (SDRIFE) in our case was azithromycin which is considered one of the safest antibiotic and widely prescribed for acute respiratory tract infection. Even if the major side effects of Azithromycin are mild to moderate in severity and related to the gastrointestinal symptoms and reversible hearing loss, it is usually well-tolerated by patients. Drug related rash in Azithromycin usage is observed about 6% of cases. Severe cutaneous reactions have been rarely reported in the literature [7].

This condition is a benign drug eruption that cleared within days after stopping of the offending agent [8]. To our knowledge, this is the first reported case of BS (SDRIFE) associated with azithromycin.

Consent

The examination of the patient was conducted according to the Declaration of Helsinki principles.

REFERENCES

1. Culav I, Ljubojevic S, Buzina DS. Baboon syndrome/SDRIFE due to sulfamethoxazole-trimethoprim. *Int J Dermatol.* 2013;52:1159-60.
2. Winnicki M, Shear NH. A systematic approach to systemic contact dermatitis and symmetric drug-related intertriginous and flexural exanthema (SDRIFE): a closer look at these conditions and an approach to intertriginous eruptions. *Am J Clin Dermatol.* 2011;12:171-80.
3. Häusermann P, Harr T, Bircher AJ. Baboon syndrome resulting from systemic drugs: is there strife between SDRIFE and allergic contact dermatitis syndrome?. *Contact Derm.* 2004;51:297-310.
4. Wolf R, Tüzün Y. Baboon syndrome and toxic erythema of chemotherapy: Fold (intertriginous) dermatoses. *Clin Dermatol.* 2015;33:462-5.
5. Häusermann P, Bircher AJ. SDRIFE – another acronym for a distinct cutaneous drug exanthema: do we really need it? *Dermatology.* 2007;214:1–2.
6. Lachapelle J-M. The spectrum of diseases for which patch testing is recommended. In: Lachapelle J-M, Maibach HI, eds. *Patch Testing and Prick Testing: A Practical Guide.* Official Publication of the ICDRG, 2nd edn. Berlin: Springer-Verlag, 2009: 7–31.
7. Sriratanaviriyakul N, Nguyen LP, Henderson MC, Albertson TE. Drug reaction with eosinophilia and systemic symptoms syndrome (DRESS) syndrome associated with azithromycin presenting like septic shock: a case report. *J Med Case Rep.* 2014;8:332.
8. Dhingra B, Grover C. Baboon syndrome. *Indian Pediatr.* 2007;44:937.

Copyright by Munise Daye, et al. This is an open-access article distributed under the terms of the Creative Commons Attribution License, which permits unrestricted use, distribution, and reproduction in any medium, provided the original author and source are credited.

Source of Support: Nil, Conflict of Interest: None declared.

Generalized hyperpigmentation after pyrimethamine use

Ann Sterkens^{1,2}, Vasiliki Siozopoulou^{1,2}, Evelyne Mangodt^{1,2}, Julien Lambert^{1,2}, An Bervoets^{1,2}

¹Faculty of Medicine, University of Antwerp, Wilrijk, Belgium, ²Dermatology Department, University Hospital Antwerp, Edegem, Belgium

Corresponding author: Dr. Ann Sterkens, E-mail: ann.sterkens@uza.be

ABSTRACT

A 44-year old trans woman of Asian origin presented with generalized hyperpigmentation all over her body for four weeks. Six months before, she presented at the emergency department with motor ataxia and further investigation revealed a new diagnosis of HIV, cerebral toxoplasmosis with cerebral edema and latent syphilis. Two months later she presented with encephalitis: CMV and TBC were diagnosed. At that moment, a lot of new medication was started. Skin biopsy was compatible with a medical eruption. Hyperpigmentation was most probably caused by pyrimethamine, which was given for the treatment of toxoplasmosis. Pyrimethamine was stopped and changed into trimethoprim and sulfamethoxazole. Reevaluation after two months showed fading of the hyperpigmentation, especially in the face, which points towards the right diagnosis.

Key words: Generalized hyperpigmentation; Toxoplasmosis; Pyrimethamine; HIV; Trimethoprim; Sulfamethoxazole

INTRODUCTION

Hyperpigmentation is the darkening of the skin. Most of the time it is caused by an increased melanin deposition, and in rare cases it is due to deposition of pigments like iron or hemosiderin. Hyperpigmentation can be well circumscribed (lentiginos, ephelides, maturational hyperpigmentation, melasma, fixed drug eruption,...) or diffuse. The diffuse pattern can be linear (phytophotodermatitis, drug-induced), reticulated (drug-induced, erythema ab igne, confluent papillomatosis), nonpatterned (drug-induced, idiopathic) or it can be associated with an endocrine/metabolic or auto-immune disease.

Normally melanin can only be found in the epidermis. Melanin in the dermis can occur in inflammatory skin diseases, ectopic melanocytes and binding of melanin to exogenous pigments in the dermis. Wood's light examination can be useful to determinate where most of the pigment is located, but it is not useful in dark skinned

patients. Skin biopsy is not a routine examination but can be done when the clinical diagnosis is not clear.

CASE REPORT

A 44-year old transwoman of Asian origin, who recently came to Belgium, presented with generalized hyperpigmentation all over the body, also in sun-protected areas (Figs 1a and 1b). It started four weeks before with xerosis and flaking of the skin and it evolved to hyperpigmentation. Less hyperpigmentation was visible at the nose bridge and in the infra-orbital region.

She had recently been suffering from numerous medical problems.

Six months ago, she went to the emergency room because of motor ataxia of the right hand and leg, due to cerebral edema. A blood test revealed a new diagnosis of HIV (CD4 20 cells/ μ l) and latent syphilis.

How to cite this article: Sterkens A, Siozopoulou V, Mangodt V, Lambert J, Bervoets A. Generalized hyperpigmentation after pyrimethamine use. Our Dermatology Online. 2019;10(2):176-178.

Submission: 03.12.2018; **Acceptance:** 06.02.2019

DOI:10.7241/ourd.20192.17

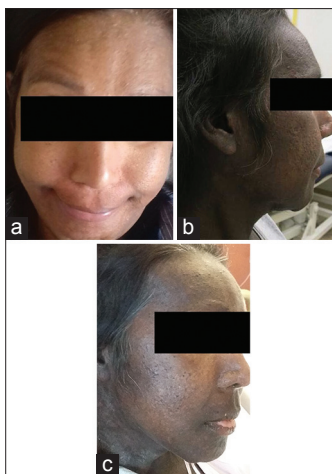

Figure 1: (a) Face before hyperpigmentation (b) Hyperpigmented face at the moment of diagnosis (c) Two months after stopping pyrimethamine: hyperpigmentation of the face starts to fade away.

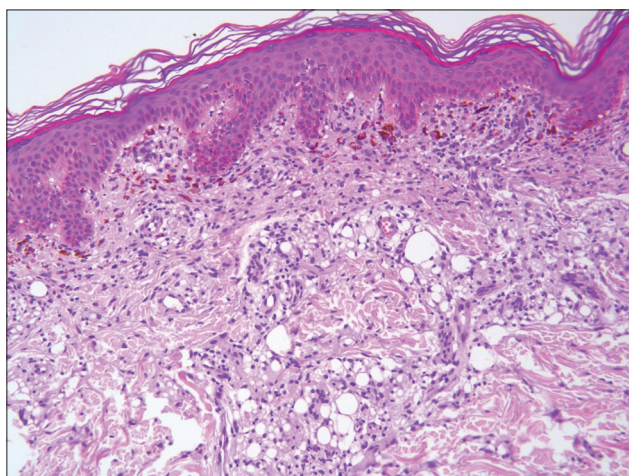


Figure 2: Skin biopsy: melanin incontinence.

A sample of cerebrospinal fluid (CSF) confirmed the diagnosis of cerebral toxoplasmosis. Highly Active Anti-Retroviral Therapy (HAART) was started (dolutegravir 200/245 mg 1x/day and emtricitabine/tenofovir disoproxil 50 mg 1x/day) and toxoplasmosis was treated with pyrimethamine 25 mg 3x/day, sulfadiazine 4x/day, levo-folic acid 15 mg 1x/day and folic acid. Dexamethasone 4 mg/dl 6x/day, was given to treat cerebral edema and penicillin 1200000 IE for syphilis.

Four months ago, she presented with an evolutive sepsis and encephalopathy. Bilateral retinitis and pneumonitis, caused by cytomegalovirus (CMV), were diagnosed and treated with valganciclovir 450 mg 2x1/day. X-ray and CT of the thorax were suggestive for TBC pneumonitis but PCR and Ziehl stain were negative. However, anamnesis and imaging were very suspicious for TBC, tuberculostatic medication was started. Pyrazinamide 500 mg 1x4/day, isoniazid 300 mg 1x1/

day, ethambutol 400 mg 1x1/day and rifampicin 1x2/day were started.

For a male to female transition she was treated with a feminizing hormone therapy (estradiol 2 mg 1x/day and cyproterone 50 mg 1x/day), but this medication had already been stopped a few months before she presented with hyperpigmentation. She also used isotretinoin (20 mg 1x/d) for the treatment of acne.

A skin biopsy was taken and showed interphase pathology with melanin incontinence, compatible with a drug eruption (Fig. 2).

Prior to the study, patient gave consent to the examination and biopsy after having been informed about the procedure.

DISCUSSION

HIV positive patients suffer from a lot of dermatological manifestations. Most frequent problems are dry skin, seborrheic dermatitis, Kaposi sarcoma, pruritus and oral candidiasis. Sometimes these problems are the first symptoms of HIV, whereby further research leads to the diagnosis of HIV. The rate of skin manifestations is linked to disease progression. Oral candidiasis and Kaposi's sarcoma are significantly correlated with low CD4+ counts [1,2].

This patient had a non-patterned generalized hyperpigmentation of the skin. Most likely, the hyperpigmentation is drug-induced. Normally melanin can only be found in the epidermis. In this case, discoloration of skin and mucosa is caused by an increased melanin production or a deposition of drug complexes in the dermis. Wood's light examination can be useful to determine whether most of the pigment is located at the epidermis or dermis, but it is not useful in dark skinned patients [3].

Chemotherapeutic agents, antimalarials, hormones, heavy metals, prostaglandin agonist, smoking and some others (Zivoduvine, Minocycline, Psoralens, Amiodaron, Clofazimine..) can be responsible [4,5].

This patient took a lot of medication. Pyrazinamide, co-trimoxazole and esomeprazole are known to cause photosensitivity. In this case, photosensitivity or phototoxicity as an etiology of the hyperpigmentation is unlikely because sun-protected areas are also discolored.

Emcitrabine is known to cause hyperpigmentation in children, but it is not yet described in literature for adults [6].

A rare side-effect of pyrimethamine is abnormal skin pigmentation.

In 2011, a case report has been published which described a generalized hyperpigmentation in a 7-year old girl. The girl was diagnosed with toxoplasmosis and treated with a loading dose of 40 mg pyrimethamine, followed by 20 mg pyrimethamine a day. Medication was changed and two months later the hyperpigmentation started to fade away [7].

Pyrimethamine is the most likely cause of hyperpigmentation in this woman. Medication was stopped and changed into trimethoprim and sulfamethoxazole. Two months later, discoloration started to fade away, especially in the face (Fig. 1c).

CONCLUSION

There is not yet much published about pyrimethamine and discoloration. In our case pyrimethamine is most likely the responsible drug because after stopping the medication, hyperpigmentation started to fade away which points toward the right diagnosis.

Consent

The examination of the patient was conducted according to the Declaration of Helsinki principles.

REFERENCES

1. Chawhan SM, Bhat DM, Solanke SM. Dermatological manifestations in human immunodeficiency virus infected patients: Morphological spectrum with CD4 correlation. *Indian J Sex Trans Dis AIDS*. 2013;34:89-94.
2. Singh H, Singh P, Tiwari P, Dey V, Dulhani N, Singh A. Dermatological manifestations in HIV-infected patients at a tertiary care hospital in a tribal (bistar) region of Chhattisgarh, India. *Indian J Dermatol*. 2009;54:338-41.
3. Manjunath K, Kiran C, Sonakshi S, Ashwini N, Agrawal R. Comparative study of Woods lamp and dermoscopic features of melasma. *J Eviden Bas Med Healthcare*. 2015;2:9012-15.
4. Ghosh A, Das A, Sarkar R. Diffuse hyperpigmentation: A comprehensive approach. *Pigment Int*. 2018;5:4-13
5. Dessirier F, Arnault J-P, Farre I, Poulet C, Chaby G, Dairi M, et al. Atypical cutaneous hyperpigmentation after multiple chemotherapy agents. *Our Dermatol Online*. 2017;8:276-9.
6. Sennayake MP, Mettananda DSG, Vidyatilake S. Profound thrombocytopenia and generalized hyperpigmentation following pyrimethamine use. *Sri Lanka J Child Health*. 2011;40:134-5.
7. Engin A, Ozaras R, Mert A, Tabak F, Aktuğlu Y. Hyperpigmentation due to pyrimethamine use. *J Dermatol*. 2002;29:443-5.

Copyright by Ann Sterkens, et al. This is an open-access article distributed under the terms of the Creative Commons Attribution License, which permits unrestricted use, distribution, and reproduction in any medium, provided the original author and source are credited.

Source of Support: Nil, Conflict of Interest: None declared.

Dyschromatosis universalis hereditaria: A rare case report from Northeast India

Romita Bachaspatimayum, Priyanka Das, Nandita Bhattacharjee

Department of Dermatology, Venereology and Leprology, Regional Institute of Medical Sciences, Imphal, Manipur, India

Corresponding author: Dr. Priyanka Das, E-mail: iampriyanka1243@gmail.com

ABSTRACT

Dyschromatosis Universalis Hereditaria is a rare genodermatoses characterised by hyperpigmented and hypopigmented macules which are variable in size and shape. We report a case of Dyschromatosis Universalis Hereditaria from North east India who presented with multiple asymptomatic hyperpigmented and hypopigmented lesions over trunk and extremities since birth with positive family history which was later confirmed by histopathology.

Key words: Dyschromatosis universalis hereditaria; Genodermatoses; Pigmentary disorder

INTRODUCTION

DUH is a rare genodermatoses characterised by hyperpigmented and hypopigmented macules which are variable in size and shape [1]. It is a spectrum of diseases which includes dyschromatosis universalis hereditaria (generalized form), dyschromatosis symmetrica hereditaria (localized form) and unilateral dermatomal pigmentary dermatosis (segmental form) [2]. Dyschromatosis universalis hereditaria was first described by Ichikawa and Hiraga in 1933 [3].

CASE REPORT

An 18 years old muslim unmarried male, manual labourer by profession, presented with chief complaints of multiple asymptomatic hyperpigmented and hypopigmented lesions over trunk and extremities since birth. The lesions were present over chest and lower legs by birth while it spread to thighs, abdomen, back of trunk, arms and forearms by 3 years of age. There were no history of photosensitivity, handling chemicals and intake of any significant drugs. No history suggestive of seizure disorder was reported. Similar lesions were present in his paternal aunt since the age of 2years. He was borne of a non - consanguineous marriage.

Dermatological examination revealed numerous hyperpigmented macules interspersed with hypopigmented macules of irregular shape and 0.5 to 2 cm in size distributed over neck, trunk and extremities (Fig. 1). Face, palms and soles were spared. Mucosal surfaces, hair and nail were normal. There was no associated telangiectasia and atrophy.

Systemic examination did not reveal any abnormality. There was no associated short stature, cataract or deafness. Routine laboratory investigations including VDRL and HIV test were negative.

Skin biopsy from hyperpigmented lesion showed orthokeratotic epidermis and increase in melanin content. Biopsy from hypopigmented lesions showed decrease in melanin content and yeast in stratum corneum (Fig. 2).

DISCUSSION

Dyschromatosis universalis hereditaria is a rare pigmentary disorder which encompasses both hypo and hyperpigmented macules coalescing to form a reticular pattern [4]. The majority of cases of dyschromatosis universalis hereditaria show autosomal dominant pattern but some cases with autosomal recessive pattern have also been reported and the locus has been mapped

How to cite this article: Bachaspatimayum R, Das P, Bhattacharjee N. Dyschromatosis universalis hereditaria: A rare case report from Northeast India. Our Dermatol Online. 2019;10(2):179-180.

Submission: 20.06.2018; **Acceptance:** 20.08.2018

DOI:10.7241/ourd.20192.18

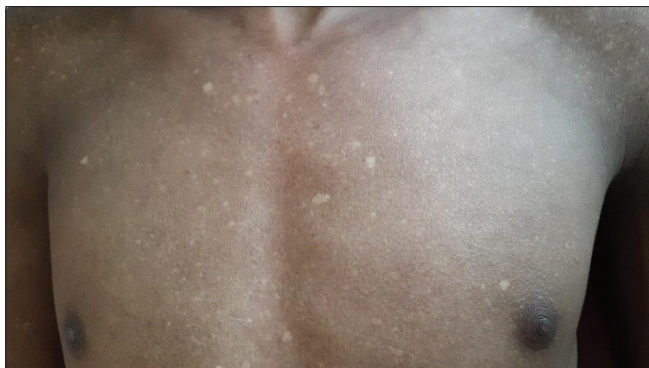

Figure 1: Numerous hyperpigmented macules interspersed with hypopigmented macules of irregular shape and 0.5 to 2 cm in size distributed over neck & trunk.

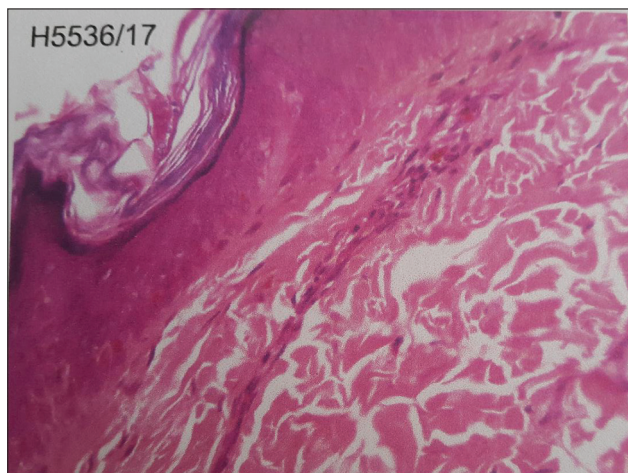


Figure 2: Skin biopsy from hyperpigmented lesions showed orthokeratotic epidermis and increase in melanin content with many scattered melanophages in upper dermis.

to chromosome 6q24.2eq25.2 and 12q21eq23 [5]. In our case, patient's paternal aunt was also having similar complaints in milder form. In a recent ultrastructural study, it has been suggested that DUH is a disorder of melanosome production rate or melanosome activity, rather than a disorder of melanocyte number [6]. Most cases present early in life [7]. But in our case the lesions were present since birth. The trunk and the extremities are commonly involved. Face is rarely involved and palms, soles and mucous membranes are spared [8]. Various systemic abnormalities have been described with DUH. These include Dowling-Degos disease, X-linked ocular albinism, tuberous sclerosis, abnormalities in erythrocyte, platelet and tryptophan metabolism, epilepsy, insulin-dependent diabetes mellitus, ocular abnormalities, photosensitivity, learning difficulties, mental retardation [9,10].

Lesions of dyschromatosis universalis hereditaria (DUH) have to be differentiated from xeroderma

pigmentosum since in both cases photoexposed areas are involved. However, in our patient lesions were present in unexposed areas as well and there were no atrophy or telangiectasia. The other differential diagnoses of DUH are dermatopathia pigmentoreticularis, Naegeli-Franceschetti-Jadassohn syndrome and dyskeratosis congenita (DKC). There is no effective treatment modality till date [8].

CONCLUSION

Previously it was thought that DUH occurs only in Japanese population. But recently it has been frequently reported in other races as well. Few cases have been reported from India. But there is no documented case report from north east India till now to the best of our knowledge. We are reporting this case because of its rarity.

CONSENT

The examination of the patient was conducted according to the Declaration of Helsinki principles.

REFERENCES

1. Naik CL, Singh G, Rajashekar TS, Okade R. Dyschromatosis universalis hereditaria. *Indian J Dermatol.* 2009;54:74-5.
2. Yadalla HK, Pinninti S, Babu AR. Dyschromatosis universalis hereditaria: Infrequent genodermatoses in India. *Indian J Hum Genet.* 2013;19:487-90.
3. Ichikawa T, Higara Y. About a pigmentary anomaly unprecedented. *Jpn J Dermatol.* 1933;34:360-4.
4. Stuhrmann M, Hennies H, Bukhari I, Brakensiek K, Nürnberg G, Becker C, et al. Dyschromatosis universalis hereditaria: evidence for autosomal recessive inheritance and identification of a new locus on chromosome 12q21-q23. *Clin Genet.* 2008;73:566-72.
5. Doss RW. Dyschromatosis in a Child- A Case Report and differential Diagnosis. *Clin Pediatr Dermatol.* 2016;2:1.
6. Nuber UA, Tinschert S, Mundlos S, Hauber I. Dyschromatosis universalis hereditaria: Familial case and ultrastructural skin investigation. *Am J Med Genet A.* 2004;125:261-6.
7. Udayashankar C, Nath AK. Dyschromatosis universalis hereditaria: A case report. *Dermatol Online J.* 2011;17:2.
8. Namitha P, Sacchidanand S. Dyschromias: A series of five interesting cases from India. *Indian J Dermatol.* 2015;60:636-8.
9. Binitha MP, Thomas D, Asha LK. Tuberous sclerosis complex associated with dyschromatosis universalis hereditaria. *Indian J Dermatol Venereol Leprol.* 2006;72:300-2.
10. Al Hawsawi K, Al Aboud K, Ramesh V, Al Aboud D. Dyschromatosis universalis hereditaria: Report of a case and review of the literature. *Pediatr Dermatol.* 2002;19:523-6.

Copyright by Romita Bachaspatimayum, et al. This is an open-access article distributed under the terms of the Creative Commons Attribution License, which permits unrestricted use, distribution, and reproduction in any medium, provided the original author and source are credited.

Source of Support: Nil, Conflict of Interest: None declared.

Facial granulomatous periorificial dermatitis in a Tunisian child

Anissa Zaouak¹, Leila Bouhajja¹, Selima Ben Jannet¹, Olfa Khayat², Houda Hammami¹, Samy Fenniche¹

¹Department of Dermatology, Habib Thameur Hospital, Tunis, Tunisia, ²Department of Pathology, Habib Thameur Hospital, Tunis, Tunisia

Corresponding author: Dr. Leila Bouhajja, E-mail: bouhajja.leila@gmail.com

ABSTRACT

Childhood granulomatous periorificial dermatitis (CGPD) is a facial rash, affecting the periorificial area in children. We present the case of 7-year-old child, presented with an asymptomatic papular eruption on the face since one year. On physical examination he had numerous monomorphic erythematous papules ranging from 1 to 3 mm in diameter clustered around his perioral region predominantly with sparse papules on his periocular and perinasal regions. A skin biopsy of a perioral papule was performed showing a dense granulomatous infiltrate located around the hair follicles in the deep and superficial dermis composed of epithelioid cells, histiocytes and lymphocytes without caseation necrosis. The patient was treated with erythromycin 500 mg with emollients and his papular eruption resolved. After one year of follow-up, there was no relapse.

Key words: Dermatitis; Child; Granuloma

INTRODUCTION

Childhood granulomatous periorificial dermatitis (CGPD) is a granulomatous skin disease characterized by yellowish brown papules affecting perioral, perinasal and periocular areas. It was first described by Ginotti et al in 1970 in five children [1]. It affects mainly black children, but there are cases involving Caucasian patients [2]. The etiology is controversial but the use of topical medication can be responsible.

CASE REPORT

A 7-year-old child presented with an asymptomatic papular eruption on the face since one year. He had no personal or family history of acne, asthma, contact dermatitis or food allergies. Initially he was treated with betamethasone dipropionate 0.05% cream, twice daily on his facial eruption for 3 months by his pediatrician with a worsening of his skin condition. On physical examination, he had numerous monomorphic

erythematous papules ranging from 1 to 3 mm in diameter clustered around his perioral region predominantly with sparse papules on his periocular and perinasal regions (Fig.1). The rest of his cutaneous examination was normal. A skin biopsy of a perioral papule was performed showing a dense granulomatous infiltrate located around the hair follicles in the deep and superficial dermis composed of epithelioid cells, histiocytes and lymphocytes. There was no caseation necrosis (Fig.2). The special staining for fungi and mycobacteria were negative. Immediate discontinuation of topical corticosteroids was performed. The patient was treated with erythromycin 500 mg four times a day for 2 months along with emollients. His papular eruption resolved without sequelae and after one year of follow-up, there was no relapse.

DISCUSSION

Childhood granulomatous periorificial dermatitis (CGPD) is a granulomatous disease characterized

How to cite this article: Zaouak A, Bouhajja L, Jannet SB, Khayat O, Hammami H, Fenniche S. Facial granulomatous periorificial dermatitis in a Tunisian child. Our Dermatol Online. 2018;10(2):181-183.

Submission: 25.07.2018; **Acceptance:** 29.11.2018

DOI:10.7241/ourd.20192.19

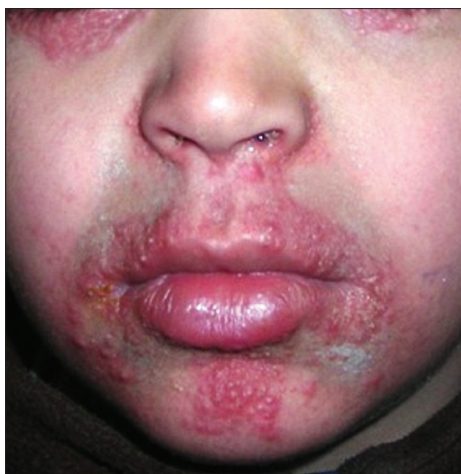

Figure 1: Numerous monomorphic erythematous papules in a periorificial distribution.

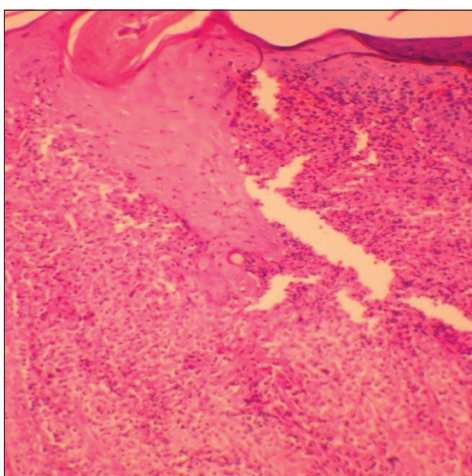


Figure 2: Lymphohistiocytic inflammatory infiltrate affecting the periphery of the follicle with multinucleated giant cells (HEx100).

by monomorphic small papular eruption with a periorificial distribution predominantly in the perioral region. It was first described by Ginotti et al in 1970 in five children [1]. It usually presents as asymptomatic flesh-colored, yellow-brown monomorphic with a periorificial distribution as in our patient with small papules affecting the perioral, periorbital and perinasal folds. Histopathologic examination is important to distinguish this entity from the other cutaneous granulomatosis and shows usually perifollicular epithelioid granulomas without a central caseation necrosis associated to a moderate inflammatory infiltrate located in the dermis and around the vessels. The age range is between 3 and 12 years. It occurs more commonly in dark skinned patients originating from Africa but Caucasian children could also be affected [2]. CGPD is a controversial disease. Its etiology remains unclear. Some authors consider that

it could belong to the large spectrum of granulomatous rosacea in children; others consider that it is a distinct entity with a particular clinical behavior. Differential diagnosis may include granulomatous rosacea, cutaneous sarcoidosis, perioral dermatitis, lupus miliaris disseminates faciei, perioral contact dermatitis and tinea incognito. Granulomatous rosacea could also be mistaken with CGPD featuring almost the same clinical and histological findings but it is uncommon in children [2-5]. Cutaneous sarcoidosis is uncommon in children, it could mimic CGPD but in sarcoidosis multinucleated giant cells are uncommon. CGPD is a self-limited disease but may be exacerbated by the application of topical steroids. For the treatment, the first step is to convince the parents to an immediate discontinuation of the topical corticosteroids. The second step is to reassure the patient and the parents that it is a benign and self-limited condition that resolves without leaving cutaneous scars. Treatment with oral tetracycline, metronidazole and erythromycin seem to be the most effective. Other treatment alternatives are represented by topical erythromycin, topical metronidazole, topical tacrolimus or azelaic acid cream which could also be useful. Combining oral antibiotics and topical tacrolimus could also be an effective treatment in some patients [6].

CONCLUSION

CGPD is a distinct entity with a self-limited evolution which should be treated with a safe treatment with low side effects. Dermatologists should be aware of this dermatitis since it could affect Caucasian children and could be easily mistaken with the other acneiform eruptions.

Consent

The examination of the patient was conducted according to the Declaration of Helsinki principles.

REFERENCES

1. Gianotti F, Ermacora E, Benelli MG, Caputo R. Perioral dermatitis in children and adults. *G Ital Dermatol Minerva Dermatol.* 1971;46:132.
2. Hatanaka M, Kanekura T. Case of childhood granulomatous periorificial dermatitis. *J Dermatol.* 2018;45:e256-7.
3. Tiengo A, Barros HR, Carvalho DB, Oliveira GM, Romiti N. Case for diagnosis: childhood granulomatous periorificial dermatitis. *An Bras Dermatol.* 2013;88:660-2.
4. Dessinioti C, Antoniou C, Katsambas A. Acneiform eruptions. *Clin Dermatol.* 2014;32:24-34.
5. Lucas CR, Korman NJ, Gilliam AC. Granulomatous periorificial

dermatitis: a variant of granulomatous rosacea in children? J Cutan Med Surg 2009; 13:115-18.

6. Hussain W, Daly BM. Granulomatous periorificial dermatitis in an 11-year-old boy: dramatic response to tacrolimus. J Eur Acad Dermatol Venereol.2007;21:137-39.

Copyright by Anissa Zaouak, et al. This is an open-access article distributed under the terms of the Creative Commons Attribution License, which permits unrestricted use, distribution, and reproduction in any medium, provided the original author and source are credited.
Source of Support: Nil, **Conflict of Interest:** None declared.

Simultaneous occurrence of papulonecrotic tuberculid and extra pulmonary tuberculosis (cervical lymphadenopathy) in an adult man. A Case report

Th Bijayanti Devi, Angila Dorjee

Department of Dermatology, Venereology and Leprology, Regional Institute of Medical Sciences, Imphal, Manipur, India

Corresponding author: Dr. Angila Dorjee, E-mail: ngla@rediffmail.com

ABSTRACT

A 35-year-old male presented with recurrent crops of papules and plaques over extensor surface of forearm, elbow, back, face, neck and lower back side of trunk since two months, along with multiple cervical lymphadenopathy over the right side of neck. On the basis of clinic pathological findings and its response to the treatment the diagnosis of papulonecrotic tuberculid (PNT) was made.

Key words: Papulonecrotic tuberculid, Extrapulmonary tuberculosis, Erythrocyte Sedimentation rate, Ziehl -Neelsen stain

INTRODUCTION

Tuberculids was first described by Darrier in 1886, it were originally felt to be related to an allergic response to tubercle bacilli in a patient with tuberculosis at a remote site. It represents an Arthus reaction (type III hypersensitivity reaction) accompanied by delayed-type hypersensitivity reaction (type IV). It is an asymptomatic, chronic disorder, occurring in crops associated with an underlying or silent focus of tuberculosis. The lesions are symmetrically distributed over the extensors of extremities, dorsum of hands and feet, face, and ear [1]. Our patient presented with crops of crusted papulo necrotic lesions on extensor surface of upper limbs, neck, V area of anterior chest and lower lateral side of back. Along with which he had right sided cervical lymphadenopathy for same duration of time. Based on the clinopathological findings, and its response to antitubercular therapy a diagnosis of PNT with was made. We are reporting a case of PNT because it is a rare manifestation even in areas endemic for tuberculosis.

CASE REPORT

35 years old male shepard by occupation presented to us with crops of mildly itchy papular skin lesion over the extensor surface of forearm and arm, neck, face and lower back since last two months. He gave history of multiple swelling over the right side of neck since last two months. History of fever and generalised weakness was present but no history of cough, weight loss, loose motions, joint pain.No significant past history of any chronic diseases. On cutaneous examination there were multiple excoriated erythematous papules few covered with crust and central necrosis and few skin coloured papules involving the extensor surface of arm, forearm, elbows, face, left lateral side of neck,V area of neck (Fig. 1). On the lateral side of left lower back the papular lesions were coalesced to form plaque with central necrosis (Fig. 2). Multiple matted firm to hard lymph nodes over the right cervical area (Fig. 1). Oral mucosal was normal, scalp normal, nails were normal.

Investigations revealed raised ESR 75 mm/h (Westergren), Mantoux test was strongly positive with induration of 30 mm X 30 mm. Biopsy from the lesion on the face

How to cite this article: Devi TB, Dorjee A. Simultaneous occurrence of papulonecrotic tuberculid and extra pulmonary tuberculosis (cervical lymphadenopathy) in an adult man. A Case report. Our Dermatol Online. 2019;10(2):184-186

Submission: 03.03.2018; **Acceptance:** 04.12.2018

DOI:10.7241/ourd.20192.20

revealed irregular acanthosis and moderate hyperkeratosis with follicular plugging, the upper dermis shows per-follicular areas displaying geographic necrosis surrounded by palisading histocytes, numerous neutrophils with occasional giant cells. ZN stain shows no acid fast bacilli (Fig. 3) features were consistent with PNT. Chest X-ray was normal, sputum for AFB was negative.

The FNAC of the cervical lymph node was suggestive of granulomatous lymphadenitis with positive AFB. Rest of the investigations were normal.

Patient was started on Anti tubercular therapy consisting of rifampicin 600mg, isoniazid 300mg, pyrazinamide 1500mg, and ethambutol 800mg and sunscreens for face and sunexposed area and to follow strict photoprotection. On starting therapy, many

lesions on back disappeared within 2 weeks. His general condition has improved and at 4weeks of therapy. He is still on ATT and his skin lesions are healing with scarring at back and trunk.

Prior to the study, patient gave written consent to the examination and biopsy after having been informed about the procedure.

DISCUSSION

Cutaneous tuberculosis can be a “true” cutaneous tuberculosis like lupus vulgaris, TB verrucosa cutis, scrofuloderma, orifacial TB, miliary TB or tuberculids like papulonecrotic tuberculid, nodular vasculitis, lichen scrofulosorum, erythema nodosum [1-6].

PNT is considered a sign of a good immunological status, because it usually appears in patients with moderate or high degree of immunity [3]. Extracutaneous focus is found in only 30-40% of cases of cutaneous TB, with cervical lymph nodes being the most common site, as in our patient. Apart from its typical locations on the extensor aspect of the extremities papulo necrotic tuberculid can involve buttocks, face, eyelids and even glans penis [2].

However, strongly positive tuberculin test, suggestive histopathological findings with endarteritis and thrombosis of the dermal vessels; and above all complete remission of the disease after the institution of antitubercular therapy confirmed the condition to be a case of papulo necrotic tuberculid [7]. PNT is a rare manifestation even in areas endemic for tuberculosis [8].

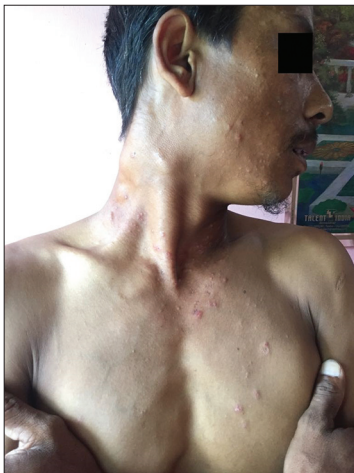

Figure 1: Clinical photograph showing papules, papulopustules lesions with necrotic centre over the face and neck with right sided matted cervical lymphadenopathy

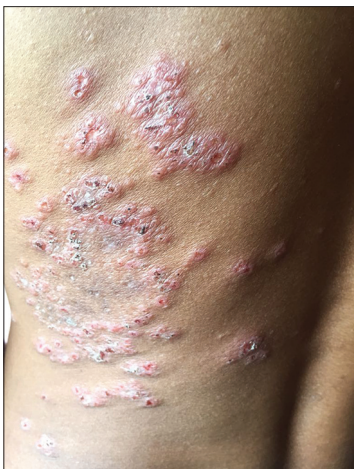

Figure 2: Clinical photograph papular lesions coalescing to form plaque with scales and with few necrotic centre at the back side of lower trunk.

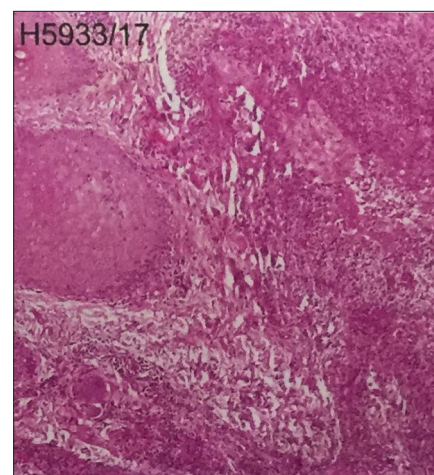


Figure 3: Irregular acanthosis, moderate hyperkeratosis with follicular plugging, dermis shows geographic necrosis in per-follicular areas surrounded by palisading histocytes, numerous neutrophils occasional giant cells. ZN stain no AFB.(Face). (H&E X 100).

CONSENT

The examination of the patient was conducted according to the Declaration of Helsinki principles.

REFERENCES

1. Bae SH, Yun SJ, Lee JB, Kim SJ, Lee SC, Won YH. Papulonecrotic tuberculid: A rare skin manifestation in a child with mesenteric tuberculous lymphadenopathy. *Acta Derm Venereol.* 2017;96:137-8.
2. Oon HH, Chong WS, Oh CC. Simultaneous occurrence of papulonecrotic tuberculid and erythema induratum in an Asian woman. *Skinmed.* 2016;14:457-59.
3. Paller A, Mancini AJ. Bacterial, mycobacterial, and protozoal infections of the skin. *Hurwitz Clinical Pediatric Dermatology: Textbook of skin disorders of childhood and adolescence.* 5th ed. New York, USA: Elsevier; 2016: 334-359.
4. Gupta V. Papulonecrotic tuberculid with scrofuloderma: An uncommon association. *J Clin Diagn Res.* 2015;9:WD03-4.
5. Singh SK, Rai T. Papulonecrotic tuberculid in a patient with pulmonary tuberculosis. *Indian Dermatol Online J.* 2014;5:72-3.
6. Dar NR, Raza N, Zafar O, Awan S. Papulonecrotic tuberculids associated with uveitis. *J Coll Physicians Surg Pak.* 2008;18:236-8.
7. Muto J, Kuroda K, Tajima S. Papular tuberculides post-BCG vaccination: Case report and review of literature in Japan. *Clin Exp Dermatol.* 2006;31:611-2.
8. Chen SC, Tao HY, Tseng HH. Papulonecrotic tuberculid—a rare skin manifestation in a patients with pulmonary tuberculosis. *J Formos Med Assoc.* 2000;99:857-9.

Copyright by Th Bijayanti Devi, et al. This is an open-access article distributed under the terms of the Creative Commons Attribution License, which permits unrestricted use, distribution, and reproduction in any medium, provided the original author and source are credited.

Source of Support: Nil, Conflict of Interest: None declared.

Striking papular dermatosis in a patient with Down syndrome

Lucía González-Ruiz, Monserrat Franco-Muñoz, María Rogel-Vence, Violeta Herrera-Montoro

Department of Dermatology, General University Hospital of Ciudad Real, Cdad, Real, Spain 1. Department of Pathological Anatomy, University General Hospital of Ciudad Real, Cdad, Real, Spain

Corresponding author: Dr. Lucía González-Ruiz, E-mail: gruizlucia@gmail.com

ABSTRACT

Syringomas are benign adnexal tumors deriving from eccrine sweat ducts, that affect 1% of general population. They present with a female predominance and associated with Down's syndrome. Syringomas are classified into four clinical variants, the localized form is the most frequent. Clinically, they appear as multiple, small, firm, skin-colored and asymptomatic papules, usually distributed in the periorbital area. Skin biopsy shows benign proliferation of multiple eccrine ducts embedded in fibrotic stroma of the upper dermis. We present a case of a 20-year-old man with Down's syndrome with multiple papules resembling eruptive syringomas. We review reported clinical and histopathological findings of eruptive syringomas and discuss differential diagnosis as well as treatment options.

Key words: Syringoma; Down syndrome; Eruptive; Papular dermatosis

How to cite this article: González-Ruiz L, Franco-Muñoz M, Rogel-Vence M, Herrera-Montoro V. Striking papular dermatosis in a patient with Down syndrome. Our Dermatol Online. 2019;10(2):187-190.

Submission: 22.11.2018; **Acceptance:** 27.01.2019

DOI:10.7241/ourd.20192.21

Dermatosis papular extensa en un paciente con síndrome de Down

Lucía González-Ruiz, Monserrat Franco-Muñoz, María Rogel-Vence, Violeta Herrera-Montoro

Department of Dermatology, General University Hospital of Ciudad Real, Ciudad Real, Spain 1. Department of Pathological Anatomy, University General Hospital of Ciudad Real, Ciudad Real, Spain

Corresponding author: Dr. Lucía González-Ruiz, E-mail: gruizlucia@gmail.com

RESUMEN

Los siringomas son tumores anexiales benignos que derivan de la glándula sudorípara ecrina. Afectan al 1% de la población general, afectando con más frecuencia a mujeres y a pacientes con síndrome de Down. Hay cuatro variantes, siendo la localizada la forma más común, en la que las lesiones son pápulas firmes color piel de distribución principalmente periocular. La histología muestra una proliferación celular dérmica en nidos rodeada por un estroma fibroso. Presentamos el caso de un paciente varón de 20 años con síndrome de Down que presentó un cuadro compatible con siringomas múltiples eruptivos, así como una revisión de esta variante poco frecuente de la entidad.

Palabras claves: Siringoma; Síndrome de down; Eruptivos; Dermatitis papular

INTRODUCTION

Los siringomas son tumores anexiales benignos que derivan del acrosiringio, la porción intraepidérmica del conducto excretor de la glándula sudorípara ecrina [1,2]. Friedman y Butler propusieron clasificar los siringomas en cuatro variantes clínicas [2,3]: localizada, generalizada, asociada a síndrome de Down y familiar. La variante generalizada consiste en la presencia de numerosas lesiones de aparición rápida (siringomas eruptivos). Se ha visto que hasta un 18%-39% de los pacientes con síndrome de Down[†] presentan lesiones compatibles con siringomas, lo que supone una prevalencia mucho mayor que en población general. En este grupo de pacientes, son más frecuentes las lesiones generalizadas que localizadas. Presentamos el caso de un paciente varón con síndrome de Down y presencia de numerosas lesiones compatibles con siringomas eruptivos múltiples, así como la revisión de la literatura que hemos realizado a propósito de éste.

CASE REPORT

Paciente varón de 20 años con antecedentes personales de síndrome de Down, síndrome de Dandy Walker e hipotiroidismo en tratamiento con levotiroxina. Acudió para valoración de lesiones cutáneas en las extremidades de 4 meses de evolución con rápido empeoramiento rápido en las últimas semanas. Se observaban múltiples pápulas eritematosas monomorfas en extremidades, más numerosas y palpables en miembros inferiores (Fig. 1a). A mayor detalle, se trataba de lesiones firmes y con superficie ligeramente brillante que daba a la piel un aspecto de “empedrado” (Fig. 1b). No había afectación de mucosas ni de anejos. Las lesiones eran asintomáticas y no asociaba clínica sistémica. No refería cambios en los fármacos habituales ni antecedentes familiares de lesiones similares. Se realizó biopsia de una de las pápulas en la que se observó una proliferación celular que formaba ductos, pequeños nidos y cordones localizada en dermis superficial (Fig. 2a). Estos ductos y pequeños nidos estaban formados por células con

How to cite this article: González-Ruiz L, Franco-Muñoz M, Rogel-Vence M, Herrera-Montoro V. Dermatitis papular extensa en un paciente con síndrome de Down. Our Dermatol Online. 2019;10(2):187-190.

Submission: 22.11.2018; **Acceptance:** 27.01.2019

DOI:10.7241/ourd.20192.21

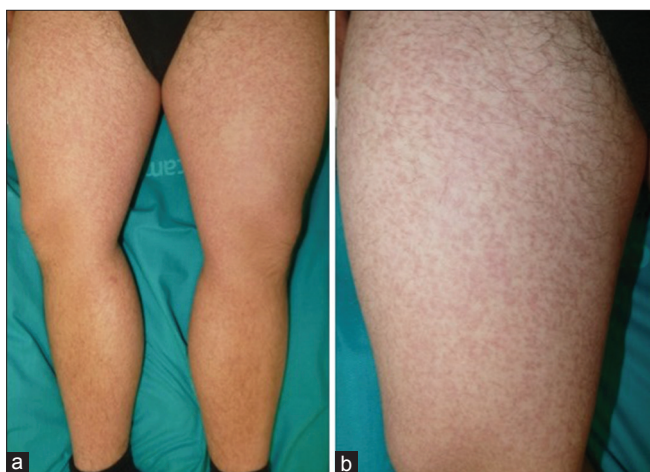


Figura 1: (a) múltiples pápulas eritematosas monomorfas en extremidades, más numerosas y palpables en miembros inferiores. (b) lesiones firmes y con superficie ligeramente brillante que daba a la piel un aspecto de “empedrado”.

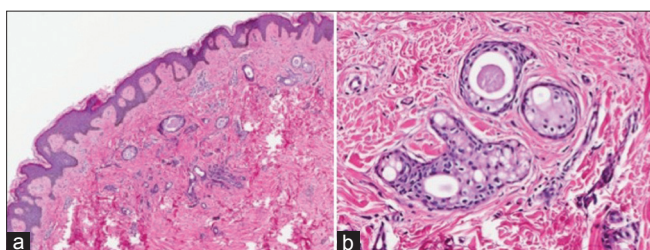


Figura 2: (a) proliferación celular que forma ductos, pequeños nidos y cordones localizada en dermis superficial y compuesta de células de citoplasma claro sin atipia y rodeadas por estroma fibroso. (b) nidos con secreción eosinófila luminal, adoptando una forma de “coma” característica.

citoplasma eosinófilo claro, sin atipia, rodeados por un estroma fibroso. No se observaban depósitos de calcio. Algunos de estos nidos mostraban secreción eosinófila luminal y tenían una forma de “coma” característica (Fig. 2b). Se realizó una analítica con hemograma, bioquímica y serología que fue normal.

Prior to the study, patient gave written consent to the examination and biopsy after having been informed about the procedure.

DISCUSSION

Los siringomas son tumores benignos que se presentan como pápulas firmes color piel que afectan aproximadamente al 1% de la población general. Aparecen con más frecuencia en mujeres jóvenes [1,3].

Friedman y Butler propusieron clasificar los siringomas en cuatro variantes clínicas [2,4]: localizada, generalizada, asociada a síndrome de Down y familiar.

La forma localizada es la más frecuente y se presenta característicamente como pápulas asintomáticas, que afectan típicamente a la región periocular de forma bilateral y simétrica [1-3]. La variante generalizada consiste en la presencia de numerosas lesiones de aparición rápida (siringomas eruptivos), sin precisarse en la literatura el tiempo de evolución que deben tener estas lesiones para catalogar el cuadro de eruptivo. Los siringomas eruptivos (SE) pueden estar asociados a diabetes, neoplasias, sarcoidosis o trastornos psiquiátricos entre otras comorbilidades [1,3,4]. La variante generalizada es muy rara y afecta sobre todo a extremidades, abdomen y tronco [2-4]. La forma familiar⁵ tiene un patrón de herencia autosómico dominante y es altamente infrecuente. Como se ha mencionado previamente, se ha visto que hasta un 18%-39% de los pacientes con síndrome de Down [4] presentan lesiones compatibles con siringomas, lo que supone una prevalencia mucho mayor que en población general. En este grupo de pacientes, son más frecuentes las lesiones generalizadas que localizadas. Además, se ha visto que los siringomas en pacientes con síndrome de Down tienen más riesgo de desarrollar calcinosis cutis como complicación del cuadro debido a la mayor frecuencia de depósito de calcio en las lesiones [2]. En el diagnóstico diferencial de los siringomas se incluyen xantomas, quistes de millium, angiofibromas, verrugas planas, hiperplasias sebáceas, otros tumores anexiales, urticaria pigmentosa o liquen plano entre otros cuadros [1,2,4]. El estudio histopatológico muestra una proliferación dérmica de células epiteliales de citoplasma pálido eosinófilo, dispuestas en nidos o túbulos, rodeadas de un estroma fibroso y con una forma típica de “renacuajo” o “coma” [5,6]. Debido a la benignidad del cuadro y a la ausencia de síntomas asociados, el principal objetivo del tratamiento es estético, ya que en el caso de los SE pueden llegar a ser muy llamativos y afectar de forma importante la esfera psicosocial de los pacientes. Se han descrito como posibles opciones terapéuticas tanto tratamientos destructivos (láser CO₂, crioterapia, electrocoagulación, escisión quirúrgica entre otros...) como médicos basadas sobretodo en retinoides tópicos u orales [1-4]. Desafortunadamente, estos tratamientos son poco efectivos, y aunque algunas lesiones regresan, en su mayoría permanecen estables.

CONCLUSION

Los SE son una variante poco frecuente de este tipo de tumores benignos, que se asocian con más frecuencia a pacientes con Síndrome de Down. Se trata de cuadros

que pueden llegar a ser muy llamativos y frustrantes por la extensión de las lesiones y su refractariedad a diversos tratamientos.

Consent

The examination of the patient was conducted according to the Declaration of Helsinki principles.

REFERENCES

1. Soler-Carrillo J, Estrach T, Mascaró JM. Eruptive syringoma: 27 new cases and review of the literature. *J Eur Acad Dermatol Venerol.* 2001;15:242-6.
2. Ghanadan A, Khosravi M. Cutaneous syringoma: a clinicopathologic study of 34 new cases and review of the literature. *Indian J Dermatol.* 2013;58:326.
3. Huang A, Taylor G, Liebman TN. Generalized eruptive syringomas. *Dermatol Online J.* 2017;23: pii: 13030/qt0hb8q22g.
4. Williams K, Shinkai K. Evaluation and management of the patient with multiple syringomas: a systematic review of the literature. *J Am Acad Dermatol.* 2016;74:1234-40.
5. Ibekwe P. Familial eruptive syringoma in a Nigerian girl. *Clin Exp Dermatol.* 2016;41:383-5.
6. Müller CS, Tilgen W, Pföhler C. Clinicopathological diversity of syringomas: A study on current clinical and histopathologic concepts. *Dermatoendocrinol.* 2009;1:282-8.

Copyright by Lucía González-Ruiz, et al. This is an open access article distributed under the terms of the Creative Commons Attribution License, which permits unrestricted use, distribution, and reproduction in any medium, provided the original author and source are credited.
Source of Support: Nil, **Conflict of Interest:** None declared.

Pruritic papular eruption of HIV: a review article

Obioma Ekpe¹, Gerald Dafe Forae², Chibuzor Ifeanyi Okpala³

¹Department of Internal Medicine, Federal Medical Centre Umuahia, Umuahia, Nigeria, ²Department of Pathology, University of Benin Teaching Hospital, Benin, Nigeria, ³Department of Internal Medicine, Nnamdi Azikiwe University Teaching Hospital, Nnewi, Nigeria

Corresponding author: Dr. Obioma Ekpe, PhD, E-mail: uncleprinceo@gmail.com

ABSTRACT

Pruritic papular eruptions (PPE) are characterized by chronic pruritus and symmetric papular eruptions on the trunk and extremities, with absence of other definable causes of itching in an HIV-infected patient. The face may be involved in some patients and the condition tends to wax and wane. Systemic review of existing literature on PPE-HIV was carried out using original articles, review articles, case reports and Cochrane library data. Articles selected for inclusion in this review were evaluated critically with regards to their impact factor, source and evidenced based contribution on this topic as measured by their citation and the journals they were published in. Pruritic papular eruption is a frequent cause of substantial morbidity in HIV patients with varying geographical prevalence that ranged between 11% and 46%. Cases of PPE reported in men and women were approximately of equal frequency. Most patients with PPE-HIV have been observed resistant to treatment. In some regions, particularly in sub-Saharan Africa, PPE-HIV is often the presenting symptom of HIV infected patient and therefore may play a role in the diagnosis of HIV, especially in poor resource setting.

Key words: Pruritic papular eruption; HIV; Sub-Saharan Africa; Pruritic rash

INTRODUCTION

Itching is a common complaint among HIV patients and may cause significant morbidity and embarrassment. In most patients, careful history and physical examination will show that dermatosis accounts for their pruritus [1,2]. Pruritic papular eruption associated with Human Immunodeficiency Virus infection (PPE-HIV), was described by James et al in 1985 as a chronic pruritic papular dermatitis seen in patient suffering from Acquired Immunodeficiency Syndrome (AIDS) [3]. And this skin condition remains the most common cutaneous manifestation in the HIV-infected patient and it is more prevalent in developing countries [4-10].

Pruritic papular eruption of HIV manifests as chronic waxing and waning intensely pruritic papules located predominantly on the extremities and trunk as shown in Figs. 2, 3, 4 and 5. Although facial involvement can also occur (Fig. 1). The resulting excoriations and

hyperpigmentary changes can be distressing, disfiguring and stigmatizing for patients [11].

PPE-HIV is regarded as WHO clinical stage II for infants and children [12] however in adults, PPE manifest in advanced immunosuppressive stage with low CD4 count in majority of cases, but they may appear as an initial cutaneous disease with high CD4 count [13].

Epidemiology of PPE

Pruritic papular eruption of HIV (PPE-HIV), has been well described in some sub-Saharan Africa countries and elsewhere, with varying geographical prevalence. Report of PPE emerged early in the course of the HIV epidemic. Beginning in 1983, studies in Democratic Republic of Congo (formerly called Zaire) [14], Mali [4], Zambia [9], Tanzania [5], Nigeria [6], Togo [7] and other Africa countries described an extremely pruritic diffuse skin eruption occurring in HIV infected patient.

How to cite this article: Ekpe O, Forae GD, Okpala CI. Pruritic papular eruption of HIV: a review article. Our Dermatol Online. 2019;10(2):191-196.

Submission: 26.11.2018; **Acceptance:** 27.01.2019

DOI: 10.7241/ourd.20192.22

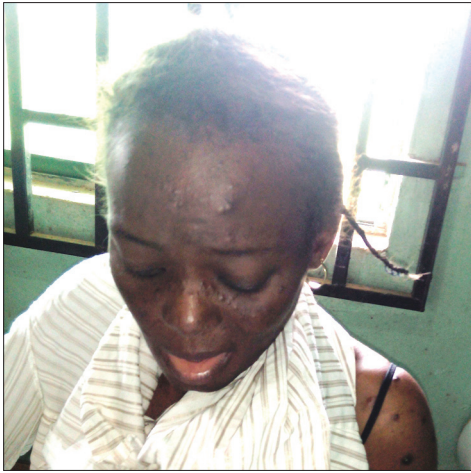

Figure 1: Patient with Pruritic papular eruptions-HIV affecting the face.

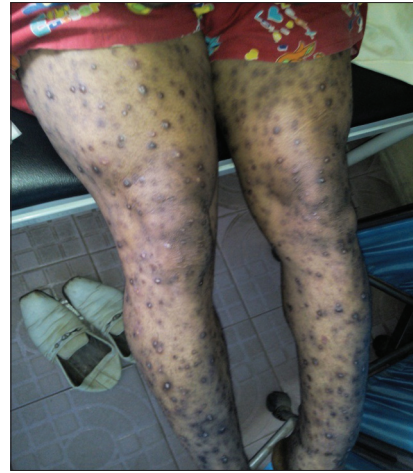

Figure 3: Patient with PPE-HIV affecting the lower limb.

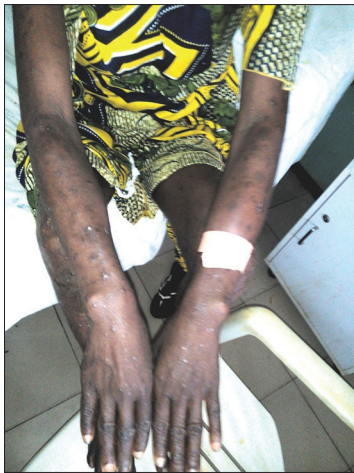

Figure 2: Pruritic papular eruptions-HIV affecting the upper limb.

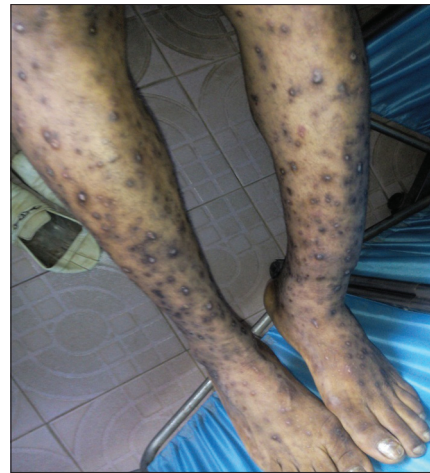

Figure 4: Patient with PPE-HIV affecting the leg and dorsum of the foot.

Reported PPE prevalence among HIV-positive patients ranged between 11% and 46%; with Southern Florida USA having a prevalence of 11% [15], Haiti 46% [8], Thailand 33-37% [16,17], hospitalized patients in Zaire 18% [10], Kenya 5% [18] and 16.7% in Nigeria [19].

There are few reported cases of pruritic papular eruption of HIV in United States of America (USA), except in areas with high mosquito prevalence such as Southern Florida [20], where a PPE prevalence of 11% was reported by Goldstein et al [15]. In a study done in Haiti on HIV patients who had pruritic skin lesions, Lautaud et al [8] found generalized PPE in 62 (46%) of 134 of Haitians examined. Sivayathorn et al [16] conducted a detailed study of the skin lesions of 248 patients infected with the human immunodeficiency virus (HIV) in Bangkok, Thailand and found a prevalence of PPE of 33%. Lowe et al [21] studied 139 HIV positive adolescents in Zimbabwe with cutaneous manifestations of HIV and found PPE to be

the most common HIV skin condition seen in 42% of patients. Colebunder et al [10] studied the generalized papular pruritic eruption in African patients with HIV infection in Zaire (Democratic Republic of Congo), it was reported that out of 284 patients hospitalized with HIV infection, 18% presented with a generalized pruritic papular eruption. No significant association between this eruption and other HIV manifestation or any opportunistic infection was found. In a study done in Kenya by Ramadhan L Mawenzi et al [18] on the epidemiology and clinical spectrum of cutaneous disease manifesting among newly diagnosed HIV seropositive adult in Nakuru County-Kenya; it was reported that out of 394 newly diagnosed HIV patients seeking care at the Rift Valley Provincial Hospital in Kenya, 20 patients (5%) had PPE. Akinboro and Onayemi et al [22] in Osogbo southwest Nigeria, conducted a research on the pattern and extent of skin disease in relation to CD4 cell count among adult with HIV infection or AIDS in 2012 and they

found the prevalence of PPE to be 19%. Ukonu and Eze [19], studied the pattern of skin disease at the University of Benin Teaching Hospital, Benin city, Nigeria and revealed that out of 4,786 patients seen in the dermatology and venerology clinic of the hospital over a 12 month period, 16.7% had PPE-HIV.

In addition to its presence in large number of patient, PPE is often one of the early cutaneous manifestation of HIV. Liataud et al [8], in a study of PPE-HIV in Haitian patients, observed pruritic papular skin lesion as the initial symptom in 70% of patients and similar findings were described in Democratic Republic of Congo, by Colebunder et al [10], where 51% reported that the skin eruption was their initial manifestation of HIV. The cases of PPE reported in men and women were approximately of equal frequency [10], however Ramadhan et al [18] in Kenya reported that 70% of patients with PPE were female.

Pathogenesis of PPE

The pathogenesis of PPE-HIV remains unclear, although several etiologies have been proposed [23,24]. An altered and exaggerated hypersensitivity response to arthropod bite has been implicated as suggested by an increase in local and peripheral eosinophilia as well as an increase in immunoglobulin E (IgE) levels, with involvement of uncovered skin and histologic finding consistent with arthropod bites in these patients [11,25]. Aires et al [26], studied the role of cytokines in PPE-HIV in Brazil and revealed lower levels of interleukin 2 (IL-2) and gamma interferon (γ -IFN) in HIV infected patients with the PPE compared with other HIV infected patients without the eruption. Moreover, they also reported a higher level of interleukin 2 (IL2), interleukin 12 (IL12), gamma interferon (γ -IFN) and interleukin 5 (IL5) in patients with PPE-HIV when compared to HIV-negative group. These led to the suggestion that immune dysregulation in the setting of chronic HIV infection could be responsible for the eruption [23].

A drug reaction has been proposed by some authors as a possible etiology of PPE, but it is unlikely given that inciting medications that predate the onset of PPE-HIV have not been consistently identified in patient with PPE [20]. Direct HIV infection of the skin has been suggested. This is because PPE have been shown to have good response to HAART by some researchers [27]. An observational study conducted in 2008 reported that 27 out of 29 patients with PPE had resolution of their

skin lesions and two patients reported a reduction in its severity within 24 months of antiretroviral therapy (ART) [27]. As a consequence of PPE response to ART, new-onset, recurrent or worsening PPE has been proposed as part of an algorithmic approach to the clinical evaluation of treatment failure after at least 6-months of ART [28,29].

Clinical Features of PPE

Patients with PPE-HIV typically present with multiple, discrete and skin colored papules that are often eroded from scratching. Lesions are commonly distributed on the extensor surfaces of the arms and legs, the dorsum of the hands (Figs. 2-4), the trunk and face as shown in figures 5, 6, 7 and 1 [13]; but sparing the mucous membranes including the palms and soles [23]. The papules may be erythematous, and do not form confluent plaques. Pustules are infrequently present. Many patients will scratch to the point of extensive excoriation with subsequent scarring. In patient with darker skin tones, post-inflammatory hyperpigmentation is often the most visible manifestation.

An inverse relationship between the absolute CD4 cell count and the prevalence and symptom severity of PPE has been reported [30]. Symptoms have been found more often in patient with advanced HIV disease. Nnoruka et al [31], in Southeast Nigeria found PPE to occur in those with lower immune status with CD4 count that was less than 200 cell/ul. A study of 120 HIV-positive patients in Thailand found zero cases of PPE in those with CD4 Count of >500 cell/ul. In contrast, PPE was found in 34% of patient with CD4 Counts between 200 and 499 cell/ul and 81% of patient with CD4 Count of <200 cell/ul, showed evidence of PPE [17]. Boonchia et al [30] in 1999 studied the relationship between PPE and immune status of HIV patients and he discovered that 81.25% of PPE patients had advanced immunosuppression with CD4 count less than 100 cells/ul and 75% had CD4 Count less than 50 cell/ul. They concluded that PPE is a cutaneous marker of advanced HIV infection. Other researchers have also observed a significant relationship between PPE and low CD4 counts [15,18].

The clinical presentation of Eosinophilic folliculitis is similar to PPE. In eosinophilic folliculitis, patients present with chronic pruritic erythematous papules and pustules that are seen over the head, neck, proximal extremities and upper trunk with sparing

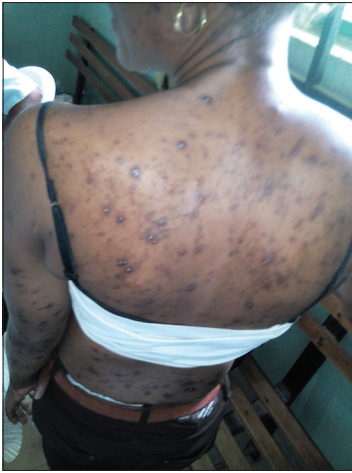

Figure 5: Pruritic papular eruptions-HIV affecting the posterior trunk and upper limb.

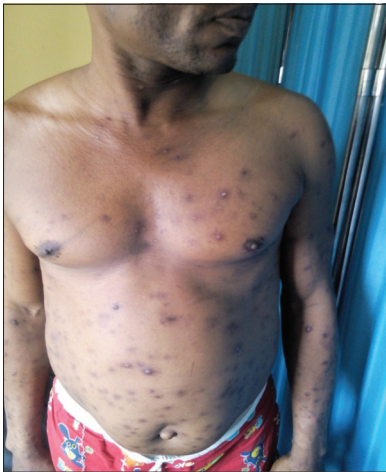

Figure 6: Patient with PPE-HIV affecting the anterior part of the trunk and upper limbs.

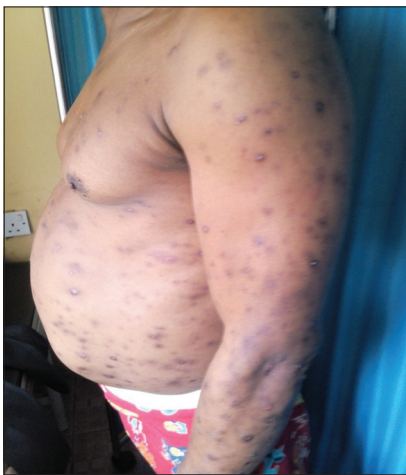

Figure 7: Patient with PPE-HIV affecting the trunk and upper limb.

affects the head, face, trunk, legs, arm, and acral sites (dorsum of hand and foot but sparing the sole and palm) without periods of improvement. Sometimes, eosinophilic folliculitis and PPE-HIV may look alike clinically making some investigators to suggest that PPE-HIV and eosinophilic folliculitis could be parts of the same disease spectrum [33]. Other skin conditions that can simulate PPE clinically include staphylococcal folliculitis, demodex folliculitis, phototoxic/photo-allergic dermatitis, scabies, secondary syphilis, onchodermatitis and papulonecrotic tuberculid [11].

Histopathologic Features of PPE-HIV

Skin biopsy has been useful in distinguishing pruritic papular eruption of HIV from other potential causes of pruritus in HIV-infected patients. Histologic findings include: perivascular dermal lymphocytic inflammatory infiltrate with increased eosinophils and CD8+ lymphocytes [34]. There is also slight epidermal hyperplasia and focal area of epidermal spongiosis.

In 2003, a study of 102 HIV-positive patients indicated that a histology of arthropod bites was highly consistent with development of PPE papules. Specifically, most of the specimens revealed “superficial and deep, perivascular and interstitial infiltrates of lymphocytes and many eosinophils beneath an epidermis that was slightly hyperplastic, whereas others showed a focal areas of epidermal spongiosis surrounded by dermal infiltrates. The investigators surmised that the occurrence of PPE could represent an abnormal and exaggerated immune response to mosquito bites in individuals with low CD4 count [11]. Papular urticaria is a histologic differential diagnosis of pruritic papular eruption of HIV [35]. Papular urticaria is commonly seen in children as a result of hypersensitivity or id reaction to bites from insects [36]. In a prospective study of papular urticaria that evaluated the histopathologic features of 30 affected patients, more than 50% of patients had mild acanthosis, mild spongiosis, exocytosis of lymphocytes, mild subepidermal edema, extravasation of erythrocytes, superficial and deep mixed inflammatory cell infiltrate of moderate density, and interstitial eosinophils [35]. In patients with papular urticaria depending on the predominant cellular infiltrates 4 subtypes (Lymphocytic, eosinophilic, neutrophilic and mixed) may be recognized [35].

of acral sites. The lesions typically waxes and wanes in severity and may spontaneously clear only to flare unpredictably [32]. In contradistinction, PPE

Ichihashi et al [37], studied the immune histochemistry of the papules of PPE and plaques of psoriasis. The

study showed that in PPE, perivascular infiltrated cells in the dermis were mostly lymphocytes; while another study found a non specific inflammatory reaction in papules of PPE on histology [10]. A clinicopathologic study of pruritic papular eruption of HIV in 1991 found on histology the presence of superficial and mid-dermal perivascular and perifollicular mononuclear cell infiltrate with numerous eosinophils [20].

Because of the difficulty in differentiating PPE and eosinophilic folliculitis clinically, histology has become an important tool in differentiating the two. In eosinophilic folliculitis there is perifollicular infiltrates of eosinophils while in PPE there is a perivascular lymphocyte infiltrates with eosinophils. Recently in 2012, Afonso et al [33] studied the association between pruritic papular eruption and eosinophilic folliculitis and HIV infection in Brazil, and postulated that eosinophilic folliculitis is characterized by a folliculocentric collection of eosinophils with some overlap of these features with PPE and suggested that the two condition could be part of the same disease spectrum.

Treatment of Pruritic Papular Eruption of HIV

Pruritic papular eruption of HIV has often been observed to be resistant to treatment. However, there are a number of different treatment approach that have been shown to be effective in some patient. Topical potent corticosteroid, emollients and oral antihistamines should be the first line approach because of their availability and effectiveness in relieving itching. Moreover, it has been documented that antihistamine is superior to topical steroid in relieving itching [38]. Also, phototherapy either ultraviolet B light (UVB) or psoralens plus ultraviolet A light (PUVA) has been shown to be effective. Ultraviolet B (UVB) light therapy given three times weekly has been shown to reduce itching and improve cosmetic appearance [39]. Although concerns have been expressed regarding the ability of UVB radiation to potentially activate HIV gene expression, however there is no significant changes in HIV RNA levels, CD4 lymphocyte count or presence of opportunistic infections seen in patients receiving UVB light therapy [40]. Another reported useful agent is pentoxifylline. This is thought to work by its TNF α inhibitory effect. Pentoxifylline, dosed at 400mg three times daily, improved pruritus in an 8-weeks trial of patients with PPE [41]. But the efficacy and safety of pentoxifylline in PPE has not been studied in a randomized controlled trial.

Whether HAART makes a difference in treatment of patients with PPE-HIV is debated and the response is variable, but some researchers have shown consistent responses of PPE to HAART hence a recommendation that PPE should be used as a criteria for initiating HAART [23,27]. Because of the association of PPE-HIV with exaggerated immune response to arthropod bites, bed nets and insecticides may play an important role in its management.

CONCLUSION

Pruritic papular eruption of HIV is a frequent cause of substantial morbidity in HIV patients. In some regions, particularly in the sub-Saharan Africa, PPE-HIV is often the presenting symptom of HIV infected patient and therefore may play a role in diagnosis of HIV, especially when serologic testing is not available or affordable [10].

Consent

The examination of the patient was conducted according to the Declaration of Helsinki principles.

REFERENCES

1. Gelfand JM, Rudikoff D. Evaluation and treatment of itching in HIV infected patients. *M Sinai J Med.* 2001;68:298-308.
2. Smith KJ, Skelton HG, Yeager J, Lee RB, Wagner KF. Pruritus in HIV-1 disease: Therapy with drugs which may modulate the pattern of immune dysregulation. *Dermatology.* 1997;195:353-8.
3. James WD, Redfield RR, Lupton GP. A papular eruption associated with human T cell lymphotropic virus type III disease. *J Am Acad Dermatol.* 1985;13:563-6.
4. Mahe A, Simon F, Coulibaly S. Predictive value of seborrheic dermatitis and other common dermatosis for HIV infection in Bamako, Mali. *J Am Acad Dermatol.* 1996;34:1084-6.
5. Pallangyo KJ. Cutaneous findings associated with HIV disease including AIDS: experience from sub Saharan African. *Trop Doct.* 1992;22:35-41.
6. Olumide YM, Dada AJ, Sogbanmu IB, Ariuna GA. Seroprevalence study of HIV-1, HIV-II and HTLV-I among patients at the Dermato-venerology clinic of the Lagos University Teaching Hospital. *Int J Dermatol.* 1997;36:741-4.
7. Pitche P, Tchchangai-Wallak, Napo-Koura G. Prevalence of skin manifestations in AIDS patients in the Lome-Tokoin University Hospital(Togo). *Sante.* 1995;5:349-52.
8. Liautaud B, Pape JW, DeHovitz JA, Thomas F, LaRoche AC, Verdier RI, et al. Pruritic skin lesions: A common initial presentation of acquired immunodeficiency syndrome. *Arch Dermatol.* 1989;125:629-32.
9. Hira SK, Wadhawan D, Kamanga J, Kavindel D, Macuacua R, Patil PS, et al. Cutaneous manifestations of human immunodeficiency virus in Lusaka, Zambia. *J Am Acad Dermatol.* 1988;19:451-7.
10. Colebunders R, Mann JM, Francis H, Bila K, Izaley L, Kakonde N, et al. Generalized pruritic papular eruption in African patients with HIV infection. *AIDS.* 1987;1:117-21.
11. Resneck JS Jr, Van Beek M, Furmanski L, Oyugi J, LeBoit PE,

- Kambugu F, et al. Etiology of pruritic papular eruptions with HIV in Uganda. *JAMA*. 2004;292:2614-21.
12. Guidelines for HIV care and treatment in infants and children. IAP and NACO with support from Clinton foundation UNICEF, WHO. 2006. Nov.
 13. Lakshmi SJ, Rao GR, Ramalakshmi, Satyasree, Rao KA, Prasad PG, et al. Pruritic papular eruptions of HIV: a clinicopathologic and therapeutic study. *Indian J Dermatol Venereol Leprol*. 2008;74:501-3.
 14. Bason MM, Berger TG, Nesbitt LT Jr. Pruritic papular eruption of HIV-disease. *Int J Dermatol*. 1993;32:784-9.
 15. Goldsteins B, Berman B, Sukenik E, Frankel SJ. Correlation of skin disorder with CD4 Lymphocyte count in patients with HIV/AIDS. *J Am Acad Dermatol*. 1997;36:262-4.
 16. Sivayathorn A, Srihra B, Lasanguankul W. Prevalence of skin disease in patients infected with human immune deficiency virus Bangkok, Thailand: *Ann Acad Med Singapore*. 1995;24:528-33.
 17. Wiwanitkit V. Prevalence of dermatological disorder in Thai HIV-infected patients correlated with different CD4 lymphocyte count status: a note on 120 cases. *Int J Dermatol*. 2004;43:265-8.
 18. Mawenzi LR, Oguttu RO, Williams CH, Joash A. Epidemiology and clinical spectrum of cutaneous diseases manifesting among newly diagnosed HIV seropositive adults in Nakuru County-kenya. *Continental J Med Res*. 2013;7:1-9.
 19. Ukou AB, Eze EU. Pattern of skin diseases at university of Benin Teaching Hospital, Benin City, Edo state, South-South Nigeria: a 12 month prospective study. *Glob J Health Sci*. 2012;4:148-57.
 20. Hevia O, Jimenez-Acosta F, Ceballos PI, Gould EW, Pennys NS. Pruritic papular eruption of the acquired immunodeficiency syndrome: a clinicopathologic study. *J Am Acad Dermatol*. 1991;24:231-5.
 21. Lowe S, Ferrand RA, Morris-Jones R, Salisbury J, Mongeya N, Dimairo M, et al. Skin Disease Among Human Immunodeficiency virus-infected Adolescents in Zimbabwe: A strong indicator of underlying HIV infection. *Pediatr Infect Dis J* 2010;29:346-51.
 22. Akinboro AO, Onayemi O, Mejiuni AD. Frequency, pattern and extent of skin disease in relation to CD4 cell Counts among adults with HIV infection or AIDS in Osogbo, southwestern Nigeria. *Int J Dermatol*. 2014;53:416-24.
 23. Eismans S. Pruritic papular eruption in HIV. *Dermatol Clin*. 2006;24:449-57.
 24. Farsani TT, Kore S, Nadole P, Ramam M, Thiemans S, Leslie K, et al. Etiology and risk factors associated with a pruritic papular eruption in people living with HIV in India. *J Int AIDS Soc*. 2013;16:25-6.
 25. Rosatelli JB, Roselino AM. Hyper-IgE, eosinophilia, and immediate cutaneous hypersensitivity to insect antigens in the pruritic papular eruption of human immunodeficiency virus. *Arch Dermatol*. 2001;137:672-673.
 26. Aires JM, Rosatelli JB, Figueiredo JF, Roselino AM. Cytokines in the pruritic papular eruption of HIV. *Int J Dermatol*. 2000;39:903-6.
 27. Castelnovo B, Byakwaga H, Menten J. Can response of a pruritic papular eruption to antiretroviral therapy be used as a clinical parameter to monitor virological outcome? *AIDS*. 2008;22:269-73.
 28. Colebunders R, Moses KR, Laurence J. A new model to monitor the virological efficacy of antiretroviral treatment in resource-poor countries. *Lancet Infect Dis*. 2006;6:53-9.
 29. Labhardt ND, Lejone T, Setoko M. A clinical prediction score in addition to WHO criteria for antiretroviral treatment failure in resource-limited settings experience from Lesotho. *PLOS One*. 2012;7:e47937.
 30. Boonchai W, Laohasrisakul R, Manonukul J, Kalthanan K. Pruritic papular eruption in HIV seropositive patients: a cutaneous marker for immune suppression. *Int J Dermatol*. 1999;38:348-50.
 31. Nnoruka NE, Chukwuka CJ, Anisuibaba B. Correlation of mucocutaneous manifestations of HIV/AIDS infection with CD4 Counts and disease progression. *Int J Dermatol*. 2007;46:14-8.
 32. Fearfield LA, Rowe A, Francis N, Bunker CB, Staughton RC. Itchy folliculitis and human immunodeficiency virus infection: Clinicopathological and immunological features, pathogenesis and treatment. *Br J Dermatol*. 1999;141:3-11.
 33. Alfonso JP, Tomimori J, Michalamy NS, Nonogaki S, Porro AM. Pruritic papular eruption and eosinophilic folliculitis associated with human immunodeficiency virus(HIV) infection: a histopathological and immunohistochemical comparative study. *J Am Acad Dermatol*. 2013;67:269-75.
 34. Ramo H, Pagliaric C, Takakura CF, Sotto MN, Duarte MI. Pruritic papular eruptions associated with HIV-etiopathogenesis evaluated by clinical, immunohistochemical and ultrastructural analysis. *J Dermatol*. 2005;32:549-56.
 35. Jordaan HF, Schneider JW. Papular urticaria: a histopathologic study of 30 patients. *Am J Dermatopathol*. 1997;19:119-26.
 36. Lewis-Jones MS. Papular Urticaria caused by *Dermestes maculatus* Degeer. *Clin Exp Dermatol*. 1985;10:181.
 37. Ichihashi N, Seishima M, Takahashi T, Muto Y, Kitajima T. A case of AIDS manifesting Pruritic papular eruptions and Psoriasiform Lesions, an immunohistochemical study of the lesional dermal infiltrates. *J Dermatol*. 1995;22:428-33.
 38. Navarini AA, Stoeckle M, Navarini S. Antihistamines are superior to topical steroids in managing human immunodeficiency virus (HIV)-associated papular pruritic eruption. *Int J Dermatol*. 2010;49:83-6.
 39. Pardo RJ, Bogaert MA, Penneys NS, Byrne GE Jr, Ruiz P. UVB Phototherapy of the pruritic papular eruption of the acquired immunodeficiency syndrome. *J Am Acad Dermatol*. 1992;26:423-8.
 40. Meola T, Soter NA, Ostreichner R, Sanchez m, Moy JA. The safety of UVB phototherapy in patients with HIV infection. *J AM Acad Dermatol*. 1993;29:216-20.
 41. Bermann B, Flores F, Burke G 3rd. Efficacy of Pentoxifylline in the treatment of pruritic papular eruption of HIV-infected person. *J Am Acad Dermatol*. 1998;38:955-9.

Copyright by Obioma Ekpe, et al. This is an open-access article distributed under the terms of the Creative Commons Attribution License, which permits unrestricted use, distribution, and reproduction in any medium, provided the original author and source are credited.
Source of Support: Nil, **Conflict of Interest:** None declared.

Epidermal cysts of scrotum

Ouiame El Jouari ¹, Anas Zaougui ², Ghita Senhaji ¹, Salim Gallouj¹, Moulay Hassan Farih², Fatima Zahra Mernissi¹

¹Department of Dermatology, University Hospital Hassan II, Fez, Morocco, ²Department of Urology, University Hospital Hassan II Fez, Morocco

Corresponding author: Dr. Ouiame El Jouari, E-mail: eljouariouiame@gmail.com

A 29-year-old man, without significant pathological antecedents. He consulted for asymptomatic scrotal papules, evolving for 5 months, gradually increasing in size and number. Clinical examination had found multiple skin color papules and nodules, firm in consistency, painless, arising from scrotal skin (Figs. 1a and 1b). A biopsy excision of a scrotal nodule was executed. The pathological study revealed an epidermoid cyst.

Epidermal cysts are benign epithelial cysts. In most cases, epidermal cysts occur in the skin of the scalp, ear, face, back and rarely scrotum. They consist of a sac lined by stratified squamous epithelium filled with laminated keratin, cholesterol crystals and debris. The main differential diagnosis is scrotal calcinosis. Treatment consists of a complete excision of the cyst to prevent recurrence.

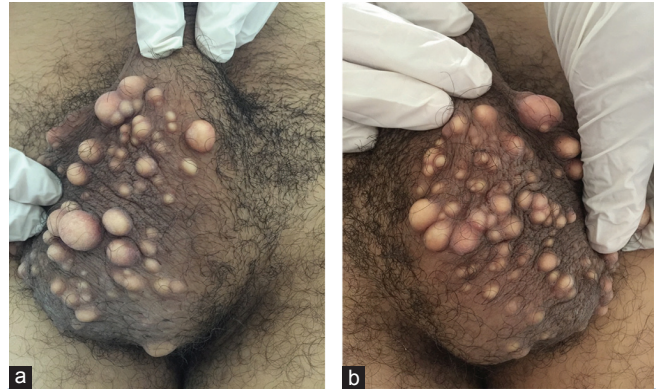

Figure 1: (a-b) Multiples epidermal cysts of scotum.

Copyright by Ouiame El Jouari. This is an open access article distributed under the terms of the Creative Commons Attribution License, which permits unrestricted use, distribution, and reproduction in any medium, provided the original author and source are credited.

Source of Support: Nil, **Conflict of Interest:** None declared.

How to cite this article: El Jouari O, Zaougui A, Gallouj S, Farih MH, Mernissi FM. Epidermal cysts of scrotum. Our Dermatol Online. 2019;10(2):197-197.

Submission: 27.05.2018; **Acceptance:** 24.09.2018

DOI:10.7241/ourd. 20192.23

Lichen planus arising through the Koebner phenomenon in areas of Hijama

Nabeel K. Al Hamzawi

Department of Dermatology, Diwaniyah teaching hospital, Diwaniyah, Iraq

Corresponding author: Dr. Nabeel K. Al Hamzawi, E-mail: alhamzawi_n@yahoo.com

The Koebner phenomenon is the appearance of isomorphic pathologic lesions in traumatized but otherwise normal skin of patients who have cutaneous disorders. These new lesions are clinically and histologically identical to those in the diseased skin. Psoriasis, lichen planus, and vitiligo appear to display the true type of isomorphic response of Koebner [1]. Herein, I describe a case of lichen planus arising through the Koebner phenomenon in the areas traumatized by Hijama.

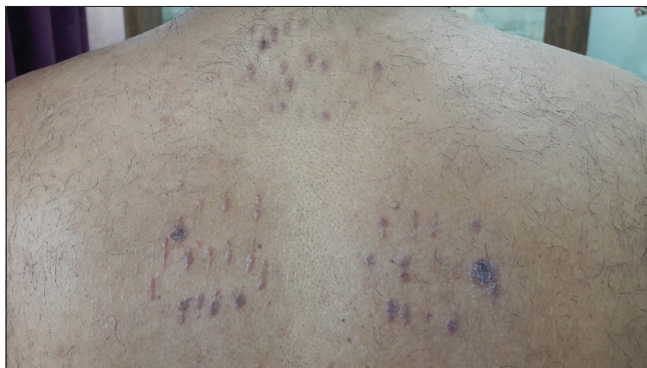

Figure 1: Three groups of violaceous flat-topped papules arising in areas of Hijama on the upper back, some of them have a linear shape and configuration.

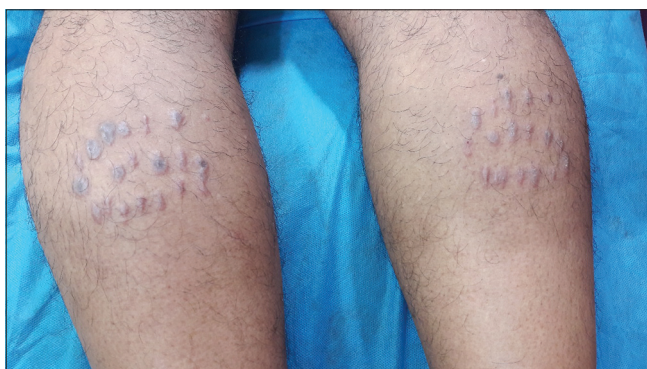

Figure 2: Groups of pruritic violaceous papules presenting on the back of the legs that traumatized by Hijama.

A 43-year-old man presented with multiple pruritic violaceous papules, arranged in groups, some of them have a linear shape and configuration. The lesions were confined to the upper back and the calf areas of the legs (Figs. 1 and 2). The patient's history showed that he was exposed to Hijama (cupping therapy) in these areas a month ago as a modality to treat the fibromyalgia that he was suffering from. A general examination revealed that he had similar previous lesions on the forehead and external genitalia (Figs. 3 and 4). The

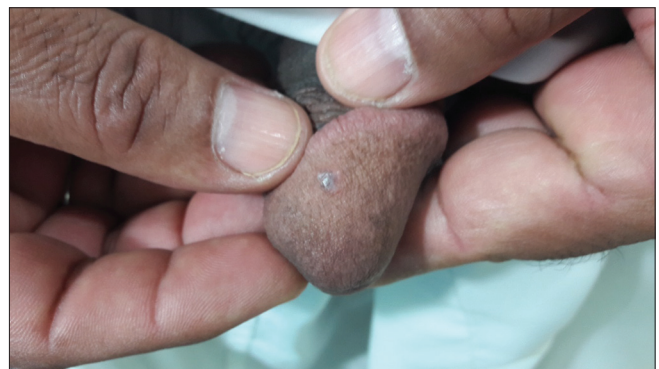

Figure 3: A violaceous plane papule of lichen planus on the glans penis.

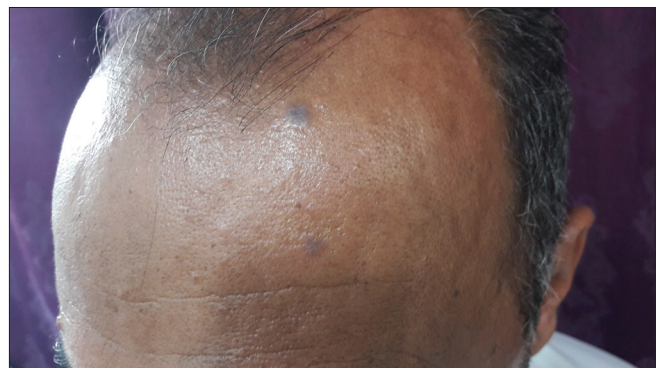

Figure 4: Lichen planus on the forehead of a 43-year-old man.

How to cite this article: Al Hamzawi NK. Lichen planus arising through the Koebner phenomenon in areas of Hijama. Our Dermatol Online. 2019;10(2):198-199.

Submission: 09.08.2018; **Acceptance:** 21.10.2018

DOI: 10.7241/ourd.20192.24

histopathologic study was consistent with lichen planus. The patient has prescribed topical and systemic corticosteroid and antihistamine, with a good clinical response.

Hijama or cupping therapy is a form of alternative medicine in which a vacuum is created in a cup and placed on the skin. The therapist then removes the cup and uses a small scalpel to make a tiny cut on the skin surface. The procedure is used to treat anxiety, depression, back pain, fibromyalgia and high blood pressure. The local adverse effects of cupping include bruises, burn and infection. There were no clear contraindications to it apart from people with health problems due to side effects [2,3]. This case has added further contraindication to the use of Hijama in patients who have dermatoses provoked by trauma, such as psoriasis, lichen planus, and vitiligo.

Consent

The examination of the patient was conducted according to the Declaration of Helsinki principles.

REFERENCES

1. Thappa DM. The isomorphic phenomenon of Koebner. *Indian J Dermatol Venereol Leprol.* 2004;70:187-9.
2. El Sayed SM, Mahmoud HS, Nabo MMH. Methods of wet cupping therapy (Al-Hijamah): In light of modern medicine and prophetic medicine. *Altern Integ Med.* 2013;2:111.
3. Cao H, Li X, Liu J. An updated review of the efficacy of cupping therapy. *PLOS One.* 2012;7:e31793.

Copyright by Nabeel K. Al Hamzawi. This is an open-access article distributed under the terms of the Creative Commons Attribution License, which permits unrestricted use, distribution, and reproduction in any medium, provided the original author and source are credited.

Source of Support: Nil, **Conflict of Interest:** None declared.

A case of widespread non-pigmented hair regrowth in diffuse alopecia areata

Younes Barbach, Hanane Baybay, Mohammed Chaouche, Sara Elloudi, Fatima Zahra Mernissi

Departement of Dermatology, CHU Hassan II, Fes, CHU Hassan II, Fès, Morocco

Corresponding author: Dr. Younes Barbach, E-mail: dr.younes2011@gmail.com

A discrete area of non-pigmented hair regrowth in patients with localized alopecia areata is a recognized phenomenon [1]. However, widespread non-pigmented hair regrowth in patients with diffuse alopecia areata has rarely been described in the literature.

This whitening appearance is thought to be attributable to two main factors. First, pigmented hairs are preferentially lost, possibly due to the presence of antibodies to melanocytes within pigmented hairs [2]. Exclamation mark hairs serve as a marker for ongoing inflammatory activity in the hair shaft and subsequent alopecia. In alopecia areata, these hairs are usually pigmented, further confirming the selectivity of disease activity. In addition, in areas of hair regrowth, reduced numbers of melanoblasts and abnormal melanogenesis have been demonstrated [3,4].

We report a case of a 20-year-old woman, with no past history suggestive of alopecia areata, and no past or family history of autoimmune disease. In particular, screening thyroid function tests were normal.

At the time of presentation, there was evidence of very active alopecia areata affecting more than 80% of her scalp hairs with sparing of non-pigmented hairs (Figs. 1a and 1b). In dermoscopy, she had a multiples short vellus and curly hairs. She was treated with a 6-month course of oral prednisolone and methotrexate and extensive hair regrowth occurred. The new hairs were non-pigmented (Figs. 2a and 2b). As a result, the patient's hair color is now white, with a normal hair density. This response has been sustained for 4 months

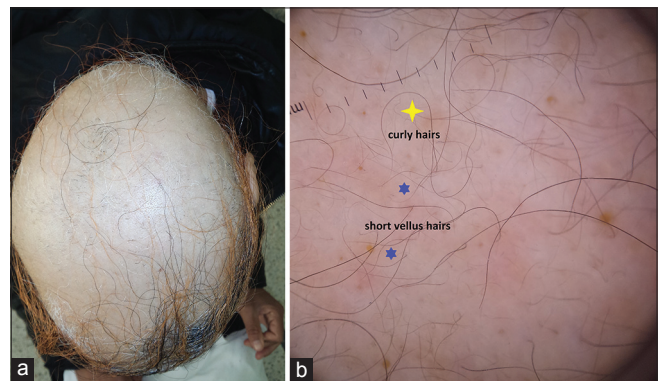


Figure 1: (a-b) Diffuse alopecia areata of the scalp. Dermoscopy: short vellus and curly hairs (before treatment).

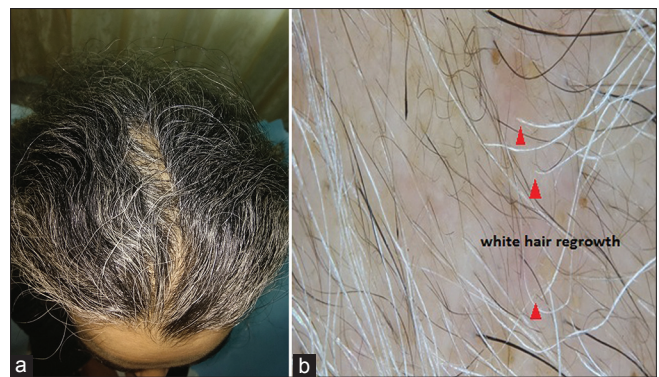

Figure 2: (a-b) Whitespread non pigmented hair regrowth. Dermoscopy: white hair regrowth (after treatment).

after cessation of treatment. Of note, there was no concurrent vitiligo on the scalp.

CONSENT

The examination of the patient was conducted according to the Declaration of Helsinki principles.

How to cite this article: Barbach Y, Baybay H, Chaouche M, Elloudi S, Mernissi FZ. A case of widespread non-pigmented hair regrowth in diffuse alopecia areata. *Our Dermatol Online*. 2019;10(2):200-201.

Submission: 15.07.2018; **Acceptance:** 30.09.2018

DOI:10.7241/ourd.20192.25

REFERENCES

1. Nahm M, Navarini AA, Kelly EW. Canities Subita: A reappraisal of evidence based on 196 case reports published in the medical literature. *Int J Trichology*. 2013;5:63–8.
2. Dinh QQ, Chong AH. A case of widespread non-pigmented hair regrowth in diffuse alopecia areata. *Australas J Dermatol*. 2007;48:221–3.
3. Jalalat SZ, Kelsoe JR, Cohen PR. Alopecia areata with white hair regrowth: case report and review of poliosis. *Dermatol Online J*. 2014;20: pii: 13030/qt1xk5b26v
4. Navarini A, Nobbe A, Marie Antoinette Syndrome. *Arch Dermatol*. 2009;145: 656.

Copyright by Younes Barbach, et al. This is an open-access article distributed under the terms of the Creative Commons Attribution License, which permits unrestricted use, distribution, and reproduction in any medium, provided the original author and source are credited.

Source of Support: Nil, **Conflict of Interest:** None declared.

Comment to: Erythroderma due to iatrogenic immunosuppression: A case of Norwegian scabies

Hubert Daisley Jr., Arlene Rampersad, Oneka Acco

Department of Pathology, General Hospital San Fernando, San Fernando, Trinidad, West Indies

Corresponding author: Prof. Hubert Daisley Jr., E-mail: profhdjr@aol.com

Sir,

We have read with interest the manuscript “Erythroderma due to iatrogenic immunosuppression: A case of Norwegian scabies” [1]. Such iatrogenic cases of crusted scabies are often seen where there is prolonged unsupervised use of steroids.

We had a similar case occurring in a 62-year-old female who suffered with rheumatoid arthritis and was treated with oral prednisolone. She defaulted from the medical clinic and continued self-medication with prednisolone for years. She developed a pruritic-generalized rash, which she treated with piriton and calamine lotion. This patient presented to the Accident and Emergency department in hypovolemic shock after several episodes of hematemesis and died shortly after presentation.

At autopsy a generalized crusted, and in some areas vesicular and erythematous rash covered her limbs, neck, chest, abdomen and back. A penetrating peptic ulcer was seen and the stomach and the rest of the gastrointestinal tract were filled with blood. A post-mortem biopsy of the crusted lesion showed sarcoptes scabiei eggs and scybala [2] within the stratum corneum (Fig. 1).

Norwegian Scabies is sequela of immunosuppression, and physicians should search for the underlying causes in each case. Patients with identifiable immunosuppressive risk factors such as organ transplantation, HIV and HTLV-1 infections, hematological malignancies and those patients with prolonged steroid use and other immunosuppressive agents are but a few who are prone to contract Norwegian Scabies [3-6]. Prolonged steroid

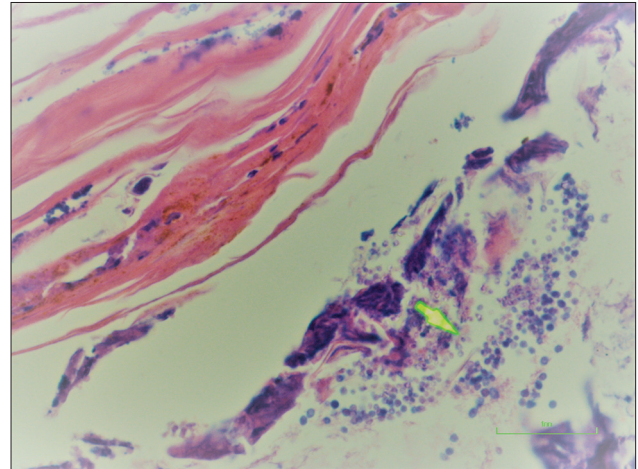


Figure 1: Sarcoptes scabiei scybala.

usage also has other complications including peptic/gastric ulcers thus physicians should be mindful of its side effects and educate patients of its usage.

Consent

The examination of the patient was conducted according to the Declaration of Helsinki principles.

REFERENCES

1. Adil M, Amin SS, Mohtashim M, Mushtaq S, Qadri S, Varshney I. Erythroderma due to iatrogenic immunosuppression: a case of Norwegian scabies. *Our Dermatol Online*. 2019;10:53-5.
2. Gary Fox. Diagnosis of scabies by dermoscopy. *BMJ Case Rep*. 2009;2009. pii: bcr06.2008.0279.
3. Ericson-Neilsen W, Kaye AD. Steroids: pharmacology, complications, and practice delivery issues. *Ochsner J*. 2014;14:203-7.
4. Bhat SA, Mounsey KE, Liu X, Walton SF. Host immune responses to the itch mite, *Sarcoptes scabiei*, in humans. *Parasit Vectors*. 2017;10:385.

How to cite this article: Daisley Jr. H, Rampersad A, Acco O. Comment to: Erythroderma due to iatrogenic immunosuppression: A case of Norwegian scabies. *Our Dermatol Online*. 2019;10(2):202-203.

Submission: 07.01.2019; **Acceptance:** 16.02.2019

DOI: 10.7241/ourd.20192.26

5. Daisley H, Charles W, Suite M. Crusted (Norwegian) Scabies as a Pre-Diagnostic Indicator for HTLV-1 Infection. *Trans R Soc Trop Med Hyg.* 1993;87:295.
6. Roberts LJ, Huffam SE, Walton SF, Currie BJ. Crusted scabies: clinical and immunological findings in seventy-eight patients and a review of the literature. *J Infect.* 2005;50:375-81.

Copyright by Hubert Daisley Jr., et al. This is an open-access article distributed under the terms of the Creative Commons Attribution License, which permits unrestricted use, distribution, and reproduction in any medium, provided the original author and source are credited.
Source of Support: Nil, **Conflict of Interest:** None declared.

A rare coexistence of alopecia areata and lichen planus

Funda Tamer¹, Haldun Umudum²

¹Ufuk University School of Medicine, Department of Dermatology, Ankara, Turkey, ²Ufuk University School of Medicine, Department of Pathology, Ankara, Turkey

Corresponding author: Dr. Funda Tamer, E-mail: fundatmr@yahoo.com

Sir,

A 45-year-old Caucasian male presented with an 18-month history of pruritic rash in the genital area and hair loss on the forearm for the last 12 months. He stated that he did not receive any treatment for these complaints before. The past medical history included a 5-year history of type 2 diabetes mellitus. The patient was taking 1000 mg of oral metformin therapy twice a day. The family history was unremarkable. Dermatological examination revealed a well demarcated, annular patch of hair loss without atrophy measuring 7x5 cm in size on the extensor surface of the right forearm. Moreover, multiple, flat, shiny erythematous papules measuring 1 to 5 mm in size were observed on the glans penis (Fig. 1). The skin biopsy was performed from both lesions to reach a definitive diagnosis. The histopathological evaluation of the alopecic patch revealed perifollicular fibrosis and mild lymphocytic infiltration (Fig. 2). However, histopathological evaluation of the glans penis revealed parakeratosis and mild acanthosis, intense lymphocytic infiltrate in the upper dermis and necrotic basal keratinocytes (Fig. 3). Laboratory tests including complete blood count, chemistry panel, sedimentation rate and C-reactive protein were all in normal limits. Venereal disease research laboratory test, anti-human immunodeficiency virus antibody, anti-hepatitis C virus antibody and hepatitis B surface antigen were negative. Thus, the patient was diagnosed with alopecia areata and lichen planus based on clinical and histopathological findings. The patient was started on 0.1% hydrocortisone butyrate ointment twice daily and he was advised to make a follow-up appointment two weeks later.

Lichen planus is a chronic inflammatory disease of mucosa, hair and nails which usually presents with pruritic, plane, purple and polygonal papules. The etiopathogenesis of lichen planus has not been identified yet. However, it is considered to be a T-cell-mediated autoimmune disease in which CD8+ T

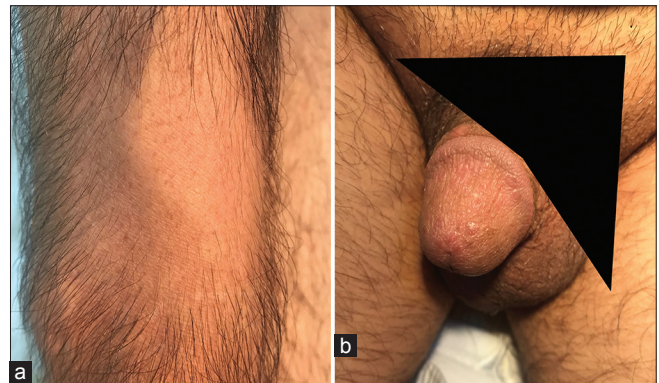


Figure 1: a. Patchy hair loss on the extensor surface of the right forearm b. Multiple erythematous papules on the glans penis.

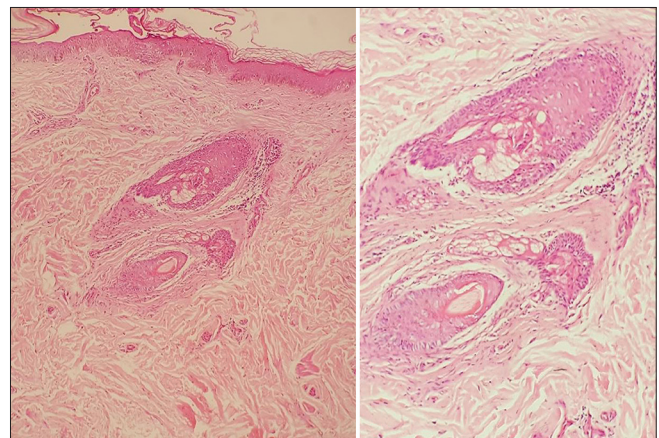


Figure 2: Perifollicular fibrosis and mild lymphocytic infiltration a. H&Ex4 b. H&Ex40.

How to cite this article: Tamer F, Umudum H. A rare coexistence of alopecia areata and lichen planus. *Our Dermatol Online*. 2019;10(2):204-205.

Submission: 22.09.2018; **Acceptance:** 07.12.2018

DOI: 10.7241/ourd.20192.27

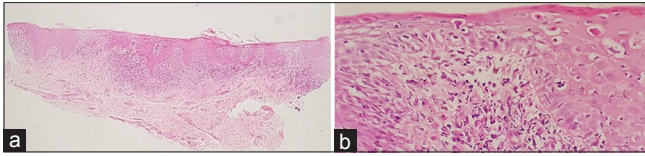


Figure 3: a. Band-like (lichenoid) lymphocytic infiltrate in the upper dermis (H&Ex2) b. Basal cell vacuolization and necrotic keratinocytes (H&Ex40)

cells damage basal keratinocytes [1]. Alopecia areata presents with non-scarring, patchy hair loss as a result of destruction of hair bulb by cytotoxic T cells. Alopecia areata is regarded as a skin-restricted autoimmune disease. However, association between alopecia areata, and various inflammatory and autoimmune disorders including lichen planus has been described [2]. Furthermore, Kar et al. and Dhar et al. reported colocalization of lichen planus and alopecia areata, previously [3,4]. Lichen planus is characterized by lymphocyte and Langerhans cell infiltration, and destruction in the basal cell layer of the epidermis whereas, alopecia areata shows perifollicular infiltrates of lymphocytes and Langerhans cells, and follicle destruction. Therefore, it has been suggested that common antigenic determinant may be a triggering factor in the onset of both diseases [4]. Hereby, we present a patient who had alopecia areata and lichen planus at the same time because of its rarity. External

surface of the forearm and glans penis were the affected areas. The onset of lichen planus was observed formerly, it was followed by alopecia areata. Our case may help to contribute the literature to determine the correlated etiologic factors in both diseases.

Consent

The examination of the patient was conducted according to the Declaration of Helsinki principles.

REFERENCES

1. Chung PI, Hwang CY, Chen YJ, Lin MW, Chen TJ, Hua TC, et al. Autoimmune comorbid diseases associated with lichen planus: a nationwide case-control study. *J Eur Acad Dermatol Venereol.* 2015;29:1570-5.
2. Garzorz N, Alsisi M, Todorova A, Atenhan A, Thomas J, Lauffer F, et al. Dissecting susceptibility from exogenous triggers: the model of alopecia areata and associated inflammatory skin diseases. *J Eur Acad Dermatol Venereol.* 2015;29:2429-35.
3. Kar BR, Ebenezer G, Job CK. Colocalisation of alopecia areata and lichen planus. *Indian J Dermatol Venereol Leprol.* 2004;70:242-3.
4. Dhar S, Dhar S. Colocalization of alopecia areata and lichen planus. *Pediatr Dermatol.* 1996;13:258-9.

Copyright by Funda Tamer, et al. This is an open-access article distributed under the terms of the Creative Commons Attribution License, which permits unrestricted use, distribution, and reproduction in any medium, provided the original author and source are credited.

Source of Support: Nil, Conflict of Interest: None declared.

Bilateral eyelid swelling: Floppy eyelid syndrome with obstructive sleep apnea

Mika Yamanaka-Takaichi¹, Hidenori Mito², Nao Kusutani¹, Daisuke Tsuruta¹

¹Department of Dermatology, Osaka City University Graduate School of Medicine, Osaka, Japan, ²Ide Eye Hospital, Yamagata, Japan

Corresponding author: Dr. Mika Yamanaka-Takaichi, E-mail: mikay0115@gmail.com

Sir,

Floppy eyelid syndrome (FES) is an eye disorder associated with obstructive sleep apnea syndrome (OSAS). First described by Culbertson and Ostler in 1981, FES is characterized by “floppy” and redundant upper eyelids with marked papillary conjunctivitis, and typically occurs in obese middle-aged and older men [1].

A 49-year-old man presented with bilateral upper eyelid swelling for several years. He was referred from an ophthalmologist after treatment with eye drops, topical corticosteroids, and steroid injection resulted in no improvement. The patient showed erythema, lichenification, and edema on both sides of the upper eyelids, causing eye-opening difficulty (Fig. 1a). The clinical differential diagnoses included thyroid-associated ophthalmopathy or dermatomyositis, but blood testing revealed normal levels of muscle-related enzymes (CK, AST, ALT, and LDH) and pituitary/thyroid hormones, and negative results for anti-nuclear antibody and anti-aminoacyl-tRNA synthetase antibody. MRI showed hyperplasia of adipose tissues in bilateral eyelids and eye sockets. The patient suffered pollinosis in spring, leading to chronic sinusitis.

The patient’s eyelids easily everted with minimal lateral traction, he was obese (body mass index: 25.2), and he suffered from snoring, daytime sleepiness, and fatigue—supporting a diagnosis of FES. A sleep physician provided the patient with an overnight respiratory portable polygraph, which revealed mild OSAS. Due to severe impairment in nocturnal minimum saturation data, the patient began continuous positive air pressure (CPAP) therapy. His eye symptom did not improve after

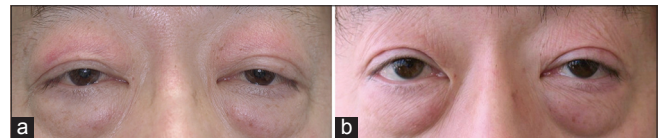


Figure 1: (a) Photo taken before surgery, showing erythema, lichenification, and edema on both sides of the upper eyelids. (b) Photo taken six months after surgery.

6 months, and he therefore underwent corrective eyelid surgery. After 12 months of post-surgery follow-up, the patient shows no apparent recurrence (Fig. 1b).

Several eye diseases have been described in association with OSAS, including optic neuropathy, glaucoma, non-arteritic anterior ischemic optic neuropathy (NAION), papilledema secondary to raised intracranial pressure (ICP), and FES [2]. Although FES pathogenesis is unclear, a number of studies clearly indicate a close relationship between FES and OSAS [2-5]. It is suspected that the affected side corresponds to habitual sleeping posture, with both sides being affected if the patient alternates sleeping sides or sleeps face down [4]. Chronic eyelid rubbing and stretching may lead to the observed eyelid changes, and such changes could accelerate once the eyelid begins to spontaneously evert during sleep [2].

Treatments for FES have not been established. Previous studies report that FES might be treated by using a lid shield at night, lid taping, nocturnal lubrication, topical steroids, lid scrubbing, and punctal plugs. Treatment with CPAP corrects apnea/hypopnea events and can reportedly improve daytime sleepiness and FES symptoms [4]. However, in our case, CPAP therapy did not yield substantial improvement of the eye symptoms. Recently, various surgical techniques have been reported

How to cite this article: Yamanaka-Takaichi M, Mito H, Kusutani N, Tsuruta D. Bilateral eyelid swelling: Floppy eyelid syndrome with obstructive sleep apnea. *Our Dermatol Online*. 2019;10(2):206-207.

Submission: 30.08.2018; **Acceptance:** 29.10.2018

DOI:10.7241/ourd.20192.28

for FES [5]. Since FES patients may visit dermatological clinic, not only ophthalmologists but also dermatologists should be aware of these ocular and periocular symptoms that can be associated with sleep apnea.

Consent

The examination of the patient was conducted according to the Declaration of Helsinki principles.

REFERENCES

1. Culbertson WW, Ostler HB. The floppy eyelid syndrome. *Am J Ophthalmol.* 1981;92:568-75.
2. McNab AA. The eye and sleep apnea. *Sleep Med Rev.* 2007;11:269-76.
3. McNab AA. The eye and sleep. *Clin Exp Ophthalmol.* 2005;33:117-25.
4. Porta R, Comini L, Barbano L, Bianchi L, Vitacca M. A case of obstructive sleep apnea syndrome associated with floppy eyelid syndrome: positive effect of CPAP therapy. *Monaldi Arch Chest Dis.* 2017;87:55-6.
5. Lee CC, Lai HT, Kuo YR, Lee SS, Lai CS. Floppy Eyelid Syndrome: An Unfamiliar Entity for Plastic Surgeons. *Ann Plast Surg.* 2018;80:40- 7.

Copyright by Mika Yamanaka-Takaichi, et al. This is an open-access article distributed under the terms of the Creative Commons Attribution License, which permits unrestricted use, distribution, and reproduction in any medium, provided the original author and source are credited.
Source of Support: Nil, **Conflict of Interest:** None declared.

Cutaneous squamous cell carcinoma arising from the hair follicle

Vladimír Bartoš

Department of Pathology, Faculty Hospital in Žilina, Slovakia

Corresponding author: Vladimír Bartoš, MD., PhD, e-mail: vladim.bartos@gmail.com

Sir,

Squamous cell carcinoma (SCC) is the second most common malignant neoplasia of the skin. It includes many subtypes with varying histomorphology and clinical behaviour. General view assumes that a vast majority of the cases arise from the surface epidermis. However, a follicular (infundibular) cutaneous SCC has also been described [1-3]. It is defined as a SCC arising from the wall of the hair follicle. Although the hair follicle structures contain a stratified squamous epithelium similar to that in the surface epidermis, in fact, it is considered to be an uncommon origin of cutaneous SCC. Here, I briefly report a case of this histopathology entity.

A 68-year old woman manifested with a slightly protuberated skin tumor on the dorsum of the nose. She claimed the lesion had been present for half year. On gross examination, it was gray-brownish and well-defined with 7 mm in diameter. A presumptive clinical diagnosis was basal cell carcinoma. A total surgical extirpation was done. Histology revealed a well differentiated keratinizing SCC deriving from a pre-existing hair follicle structure without a demonstrable epidermal point of origin (Fig. 1). A contiguous transition of normal squamous epithelium of the hair follicle and malignant tumor tissue was visible (Fig. 2). An overlying epidermis showed no keratinocyte atypia and it did not have a direct contact with cancer. This was well demonstrated by immunohistochemistry using a high molecular weight cytokeratins antibody (clone 34betaE12) (Fig. 3). At the periphery, the tumor exhibited an infiltrative growth pattern accompanied by massive chronic inflammatory cellulisation in the stroma. The Ki-67 proliferation index (clone MIB-1) of the neoplastic cells exceeded 50%, while the overlying

epidermis demonstrated a nuclear Ki-67 reactivity only in the basal cell layer. No signs of trichilemmal or hair matrix differentiation were found.

Until now, a few series of follicular (infundibular) SCC of the skin have been reported [1-3]. The largest set of the cases has been published by Shedrik et al. [1]. In a database of 5212 primary cutaneous SCCs diagnosed over 5-year period, they identified 61 cases (1.2%) of follicular SCC from 60 individuals. The mean age of the patients was 74 years. Histologically, the lesions were divided into the following two subtypes. If the tumor exclusively arose from the hair follicle, it was called „pure“ follicular SCC (49 cases). If an interfollicular epidermal origin was also demonstrated (only SCCs with < 50% of the origin from interfollicular epidermis were included), the lesions were considered „hybrid“ SCC (12 cases).

Another research addressing follicular SCCs has been conducted by Diaz-Cascajo et al. [2]. Among more than 7000 cases of cutaneous SCC, they found 16 cases of SCC developing in hair follicles (0.2%). A majority arose on sun-damaged skin, typically on the face of elderly persons. Microscopically, the tumors developed in the upper parts of hair follicles, replacing the follicular epithelium with full-thickness atypical keratinocytes and invading into the surrounding dermis. The neoplastic cells possessed features of squamous differentiation, such as abundant eosinophilic cytoplasm, hyperchromatic nuclei with prominent nucleoli, occasional dyskeratotic cells, and central keratinization. In most cases, there was an abrupt transition of malignant epithelium with the adjacent bland-appearing epidermis. All tumors were immunohistochemically negative for a broad spectrum of antibodies against human papillomaviruses, indicating no viral (HPV) etiology. They concluded,

How to cite this article: Bartoš V. Cutaneous squamous cell carcinoma arising from the hair follicle. Our Dermatol Online. 2019;10(2):208-210.

Submission: 18.07.2018; **Acceptance:** 25.09.2018

DOI:10.7241/ourd.20192.29

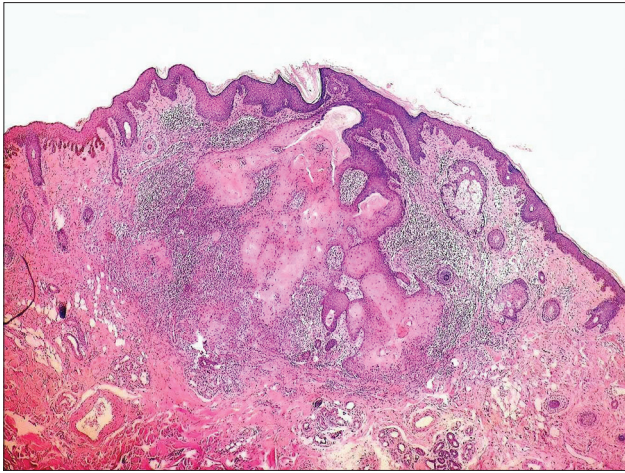


Figure 1: A conventional keratinizing SCC deriving from a pre-existing hair follicle structure. At the left side, an invasive front of tumor is visible. (hematoxylin & eosin, magnification 40x)

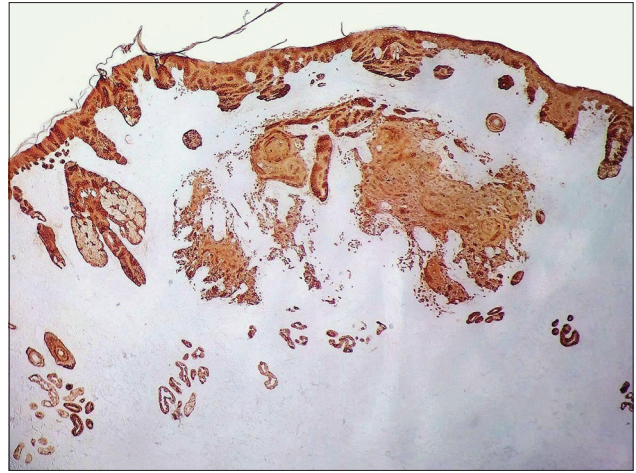


Figure 3: Strong immunoreactivity for high molecular weight cytokeratins in SCC tissue and in the surface epidermis. No contact of tumor with a surface epidermis is evident. (magnification 40x)

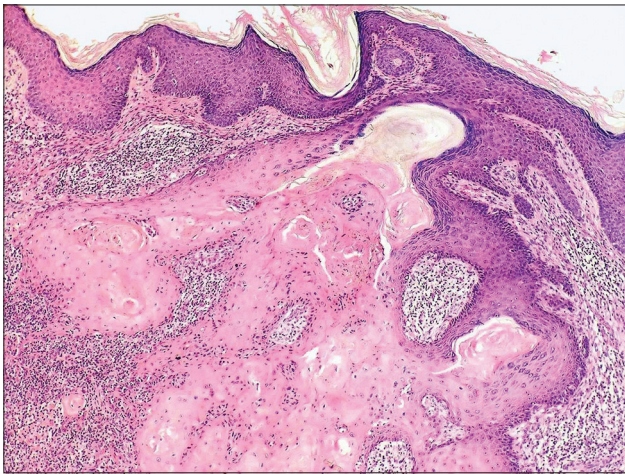


Figure 2: A contiguous transition of normal squamous epithelium of the hair follicle remnant (right) and tumor tissue (left). (hematoxylin & eosin, magnification 100x)

SCC of the hair follicle represents a poorly recognized but distinctive subset of SCC of the skin that should be considered in the differential diagnosis of other cutaneous epithelial neoplasms.

In another study, Misago et al. [3] examined 6 follicular (infundibular) SCCs, which were subclassified into: a) the common (2 cases) and, b) the crater forms (4 cases). In accordance with the previous authors, all lesions were located on the head. They had a clinical history of slow growth. Except for one case, which showed regional lymph node metastasis 3 years after the excision, no recurrence or metastasis was seen during the follow-up period.

Based on my own experience, I consider a follicular SCC of the skin to be somewhat controversial issue. Although literally reported occurrence is very low

(about 1% of all cutaneous SCCs), some authors [1,4] have suggested that an incidence is much higher and this SCC variant is under-recognized. In my opinion, it is very difficult to estimate a true incidence of follicular SCC for several reasons. I feel a crucial problem in that features of follicular differentiation or remnants of the hair follicle structures may disappear as tumor enlarges and spreads into the surrounding tissue. These histomorphologic signs are usually well identifiable in early stage of tumor growth, such as in the present case, but they may vanish over time in more advanced lesions. Further, as tumor tissue of many invasive cutaneous SCCs contain „entrapped“ hair follicles, of which the squamous epithelium underwent malignant changes, it is impossible to define, whether they represent a primary source of malignancy, or only a secondary involvement by tumor. By definition, a follicular SCC represents a truly follicular tumor demonstrating infundibular differentiation and not merely the replacement of the hair follicles by SCC. Another question arises, whether the infundibulum has a frank follicular origin that possesses distinct biological properties, or it is only an extension of the epidermis. I personally agree with a comment of Klingman and Chen [5], who did not see a practical reason to use the term follicular or infundibular cutaneous SCC as a distinct histopathologic entity. From a clinical point of view, a prognosis probably does not depend on whether cutaneous SCC arise from the surface epidermis or from the wall of the hair follicle.

Consent

The examination of the patient was conducted according to the Declaration of Helsinki principles.

REFERENCES

1. Shendrik I, Crowson AN, Magro CM. Follicular cutaneous squamous cell carcinoma: an under-recognized neoplasm arising from hair appendage structures. *Br J Dermatol*. 2013;169:384-88.
2. Diaz-Cascajo C, Borghi S, Weyers W, Bastida-Inarrea J. Follicular squamous cell carcinoma of the skin: a poorly recognized neoplasm arising from the wall of hair follicles. *J Cutan Pathol*. 2004;31:19-25.
3. Misago N, Inoue T, Toda S, Narisawa Y. Infundibular (follicular) and infundibulocystic squamous cell carcinoma: a clinicopathological and immunohistochemical study. *Am J Dermatopathol*. 2011;33:687-94.
4. Carr R, Taibjee S, Turnbull N, Attili S. Follicular squamous cell carcinoma is an under-recognised common skin tumour. *Diagn Histopathol*. 2014;20:289-96.
5. Klingman DE, Chen S. Infundibular squamous cell carcinoma: A new entity? *Am J Dermatopathol*. 2012;34:676-7.

Copyright by Vladimír Bartoš. This is an open-access article distributed under the terms of the Creative Commons Attribution License, which permits unrestricted use, distribution, and reproduction in any medium, provided the original author and source are credited.

Source of Support: Nil, **Conflict of Interest:** None declared.

Basal cell carcinoma of the leg: an unusual location

Anissa Zaouak¹, Leila Bouhajja¹, Faten Rebhi¹, Raja Jouini², Houda Hammami¹,
Samy Fenniche¹

¹Department of Dermatology, Habib Thameur Hospital, Tunis, Tunisia, ²Department of Pathology, Habib Thameur Hospital, Tunis, Tunisia

Corresponding author: Dr. Anissa Zaouak, E-mail: anissa_zauouak@yahoo.fr

Sir,

We report a 58-year-old man without a significant medical history presented to our clinic with a non-healing, slowly growing non tender ulcer on his right leg that he had for more than one year. The ulcer despite several would care measures progressively increased. Clinical signs of arterial insufficiency or venous insufficiency were not detected. Vascular studies with duplex ultrasonography failed to reveal any venous reflux. Dermatological examination revealed a well-demarcated 4x5 cm clean based ulceration with heaped-up borders located on his right leg. The base of the ulceration had normal granulation tissue (Fig. 1). Dermoscopic findings revealed arborizing vessels and short fine vessels. In addition, there were large blue grey ovoid nests. The chronic, poorly healing nature of the leg ulcer prompted us to perform a skin biopsy of the edge of the ulcer including the base which revealed large well-defined derma nodules, basaloid cells with peripheral nuclear palisading and clefting between tumor and stroma (Fig. 2). Correlation of clinical, dermoscopic and histopathological findings allowed us to confirm the diagnosis of basal cell carcinoma of the leg. The patient was referred to an oncologist for a surgical excision of the tumor.

The patient's informed consent was obtained.

Prior to the study, patient gave written consent to the examination and biopsy after having been informed about the procedure.

Basal cell carcinoma (BCC) is preferentially located in photo-exposed areas. Its occurrence on the legs is rarely reported in the literature and account for

about 8% of BCCs [1]. It is more common in males than females and is a great masquerader. In fact, BCC can mimic many dermatoses as in our case where it was misdiagnosed with a venous leg ulcer and can appear in unsuspected areas as the lower limbs. In front of a chronic leg ulcer, differential diagnosis may include venous or arterial ulcers, malignancies such as squamous cell carcinoma, amelanotic melanoma, cutaneous lymphoma and basal cell carcinoma, infectious ulcers, pyodema gangrenosum, traumatic and factitial wounds [2-4]. In our case, the chronic leg ulcer was misdiagnosed as a venous leg ulcer in the absence of clinical and ultrasonographic signs of venous insufficiency leading to an important diagnostic delay. Hence, physicians should be aware that BCC could develop de novo and that the appearance of a granulation tissue with pearly indurated borders and central ulceration should prompt suspicion. Although

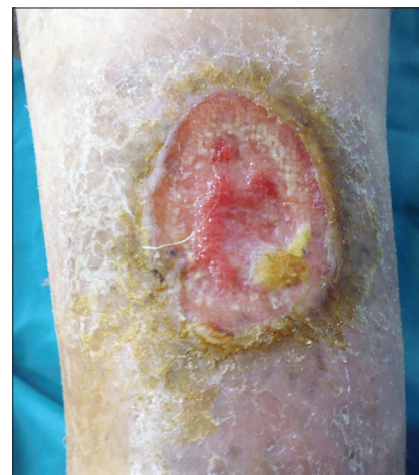

Figure 1: Well-demarcated 4x5 cm clean based ulceration with heaped-up borders located on his right leg. The base of the ulceration had normal granulation tissue.

How to cite this article: Zaouak A, Bouhajja L, Rebhi F, Jouini R, Hammami H, Fenniche S. Basal cell carcinoma of the leg: an unusual location. Our Dermatol Online. 2019;10(2):211-212.

Submission:02.09.2018; **Acceptance:** 01.11.2018

DOI:10.7241/ourd.20192.30

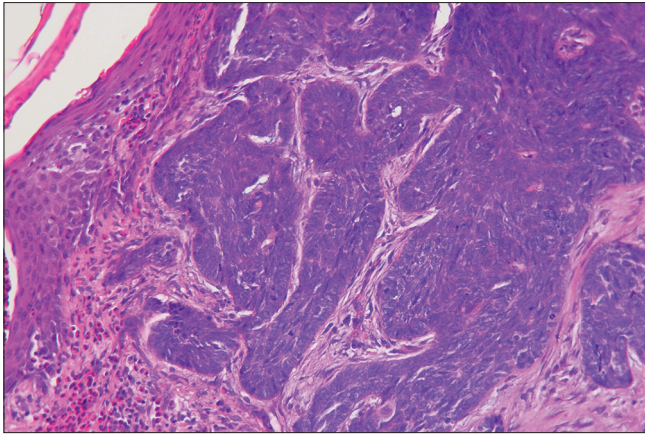


Figure 2: Large well-defined dermal nodules. Basaloïd cells with peripheral nuclear palisading and clefting between tumor and stroma (HEx100).

these tumors rarely metastasize, delayed treatment may result in significant morbidity from local invasion leading to destruction of the skin and deeper tissues. Dermoscopy could be useful in raising the suspicion of malignancy but the definitive diagnosis relies mainly on skin biopsy in front of a non healing chronic leg ulcer. Dermoscopically, basal cell carcinoma of the lower extremity is characterized by the presence of polymorphous vessels and thin serpentine vessels with lower prevalence of arborizing vessels compared to other anatomic sites [5].

The correlation of history taking, clinical examination, dermoscopic findings and histopathological findings in our case allowed us to establish the diagnosis of

basal cell carcinoma of the lower extremity. An early detection of these rare tumors in this rare localization is important in our case to avoid tumor extension and significant morbidity.

CONSENT

The examination of the patient was conducted according to the Declaration of Helsinki principles. Written informed consent was obtained from the patient for publication of this article.

REFERENCES:

1. Conde-Taboada A, De la Torre C, Flórez A, García-Doval I, Cruces M. Chronic leg ulcers and basal cell carcinoma. *J Eur Acad Dermatol Venereol.* 2006; 20:359.
2. Hwang J, Wong E. Non-healing, non-tender ulcer on shin. *J Fam Pract.* 2015; 64:421-24.
3. Celić D, Lipozenčić J, Ljubojević Hadžavdić S, Kanižaj Rajković J, Lončarić D, Borlinić T. A Giant basal cell carcinoma misdiagnosed and mistreated as a chronic venous ulcer. *Acta Dermatovenerol Croat.* 2016;24:296-98.
4. Tchanque-Fossuo CN, Millsop JW, Johnson MA, Dahle SE, Isseroff RR. Ulcerated basal cell carcinomas masquerading as venous leg ulcers. *Adv Skin Wound Care.* 2018;31:130-34.
5. Lombardi M, Pampena R, Borsari S, Bombonato C, Benati E, Pellacani G, et al. dermoscopic features of basal cell carcinoma on the lower limbs: a chameleon! *Dermatology.* 2017;233:482-88.

Copyright by Anissa Zaouak, et al. This is an open-access article distributed under the terms of the Creative Commons Attribution License, which permits unrestricted use, distribution, and reproduction in any medium, provided the original author and source are credited.

Source of Support: Nil, Conflict of Interest: None declared.

Pigmented fungiform papillae of the tongue: clinical and dermoscopic features

Niema Aqil, Mounia Bennani, Aicha Nassiri, Mariame Meziane, Salim Gallouj, Fatima Zahra Mernissi

Department of dermatology, Hassan II University Hospital Center, Fes, Morocco

Corresponding author: Dr. Niema Aqil, E-mail: niemaaqil90@gmail.com

Sir,

We present a clinical report of pigmented fungiform papillae of the tongue (PFPT), describing the dermoscopic pattern of the lesions. This case is of significance because, although PFPT is not uncommon, it is not present as an entity in most textbooks and seldom mentioned in the medical literature. Our aim is to emphasise that a prompt diagnosis will avoid further unnecessary investigations.

A 12-year-old Moroccan girl consulted our department of dermatology for multiple erythematous and hyperpigmented papules, small and asymptomatic with the tip of the tongue evolving for 5 years. The patient was not taking any medication and was in good general health. The parents did not present similar pigmentation of the oral mucosa. She was of phototype IV. Examination of the oral mucosa showed pigmentation limited to the fungiform papillae of the dorsum of the tongue (Fig. 1).

The majority of the fungiform papillae were pigmented and were present in a diffuse, symmetrical pattern, predominantly on the tip and lateral aspects of the dorsum of the tongue (Fig. 2). The fungiform papillae in the central area were not pigmented.

Dermoscopy showed that the small papules corresponded to enlarged fungiform papillae and showed linear and pointed vessels in their central part and a pinkish collar around. Some papules were pigmented in their central part and in particular at the edge of their central part with the presence of an unpigmented collar around the central pigmentation

and and dichotomized vessels that originate at the base, resembling a rose petal appearance.

Complete physical examination was normal including eyes, nails, and genitals. Laboratory values (basic metabolic panel, complete blood count, iron test, and anti nuclear antibodies) showed no alterations.

The diagnosis of racial pigmented fungiform papillae of the tongue was considered. The patient was reassured of the benign nature of the condition and no treatment was given.

The pigmented fungiform papillae of the tongue correspond to a benign change in the tongue characterized by a hyperpigmentation limited to fungiform papillae giving a dotted appearance. This pigmentation usually develops in black skinned subjects in childhood or in young adults. The lesions are classically asymptomatic. Dermoscopy shows an enlargement of the fungiform papillae with dilated vessels and pigmentation that give a “rose petal” appearance [1]. An additional element for the identification of this entity is the presence of an unpigmented collar around the central pigmentation.

The pathogenesis is unknown, but it has been hypothesized that pigmentation may develop as a result of inflammation. In fact, the cases that were biopsied showed melanophages pigmented in the lamina propria [2-4] as a possible consequence of a passage of melanin from the epithelium to the lamina propria following an inflammation that would reach the basal layer of the lamina propria [2-4]. This hypothesis is supported by the presence in dermoscopy of dilated

How to cite this article: Aqil N, Bennani M, Nassiri A, Meziane M, Gallouj S, Mernissi FZ. Pigmented fungiform papillae of the tongue: clinical and dermoscopic features. *Our Dermatol Online*. 2019;10(2):213-214.

Submission:24.06.2018; **Acceptance:** 24.09.2018

DOI:10.7241/ourd.20192.31

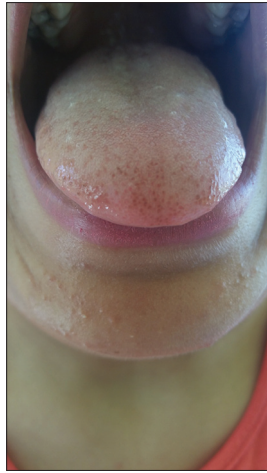


Figure 1: Pigmentation limited to the fungiform papillae of the dorsum of the tongue.

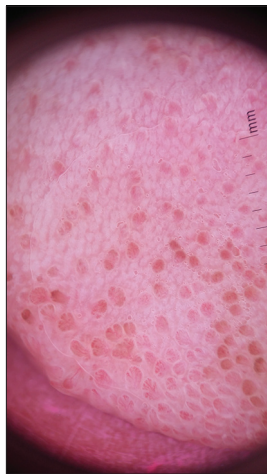


Figure 2: Dermoscopy of the pigmented fungiform papillae.

vessels inside the papillae (sign of inflammation) and by a pigmentation limited to the central part of the papillae (corresponding to the surface projection of the lamina propria) and not in the peripheral collar (corresponding to the projection of the only epithelium) [5]. Differential diagnoses of pigmented fungiform papillae of the tongue include amalgam tattoo, Peutz-Jeghers syndrome, melanocyte tumors

and Addison's disease where pigmentation is not limited to fungiform papillae.

As it is a benign condition there is no need to treat it, neither has any treatment been reported. No malignant transformation of PFPT has been described. Today, increased public awareness of the malignant potential of pigmented skin lesions has led to an increasing number of consultations. Clinicians unfamiliar with common oral and tongue changes may suggest that these alterations are pathological, leading to unnecessary investigations and dispensable biopsies. Non-invasive imaging devices like dermoscopy can avoid these unnecessary procedures.

CONSENT

The examination of the patient was conducted according to the Declaration of Helsinki principles.

REFERENCES

1. Mukamal LV, Ormiga P, Ramos-E-Silva M. Dermoscopy of the pigmented fungiform papillae of the tongue. *J Dermatol.* 2012;39:397-9.
2. Holzwanger JM, Rudolph RI, Heaton CL. Pigmented fungiform papillae of the tongue: a common variant of oral pigmentation. *Int J Dermatol.* 1974;13:403-8.
3. Werchniak AE, Storm CA, Dinulos JGH. Hyperpigmented patches on the tongue of a young girl. Pigmented fungiform papillae of the tongue. *Arch Dermatol.* 2004;140:1275-80.
4. Lin Y-T, Chou C-L. Pigmented macule on the tongue of a 12-year-old girl. *J Am Acad Dermatol.* 2013;69:e229-30.
5. Cinotti E, Labeille B, Cambazard F, Perrot JL. [Dermoscopy and reflectance confocal microscopy examination of pigmented fungiform papillae of the tongue]. *Ann Dermatol Venerol.* 2016;144:323-5.

Copyright by Niema Aqil, et al. This is an open access article distributed under the terms of the Creative Commons Attribution License, which permits unrestricted use, distribution, and reproduction in any medium, provided the original author and source are credited.

Source of Support: Nil, Conflict of Interest: None declared.

Pigmented fungiform papillae of the tongue: Moroccan case

Ouiam El Anzi, Safae Maouni, Ilham Meknassi, Badredine Hassam

Department of Dermatology-Venereology, Ibn Sina University Hospital, Mohammed V University, Rabat, Morocco

Corresponding author: Dr. Ouiam El Anzi, E-mail: elanzi.oui@gmail.com

Sir,

Fungiform papillae are red or pink, mushroom-shaped projections located on the tip, dorsal or lateral parts of the tongue, containing several taste buds. When they are brown to black in colour, they are referred as pigmented fungiform papillae of the tongue (PFPT). This condition is more common in black populations, indicating a higher susceptibility.

We report a case of a 20-year-old Moroccan woman, who presented with pigmentation on the dorsum of her tongue, which had been present for 2 years. She did not have any accompanying symptoms. Her medical and family history was not relevant, and she was not taking any medication.

On physical examination of the oral mucosa, pigmentation limited to the fungiform papillae on the tip and lateral part of the tongue were seen (Fig. 1). No other physical abnormalities were found.

Liver tests, iron serum and kidney function were normal and no other family members were known with this anomaly.

The first report of pigmented fungiform papillae of the tongue (PFPT) was by Leonard in 1905.

Pigmented fungiform papillae of the tongue develop in the second or third decade of life, few cases are described in childhood [1].

Werchniak et al. suggested autosomal dominant inheritance, based on the presence of pigmented fungiform papillae in a mother and daughter.

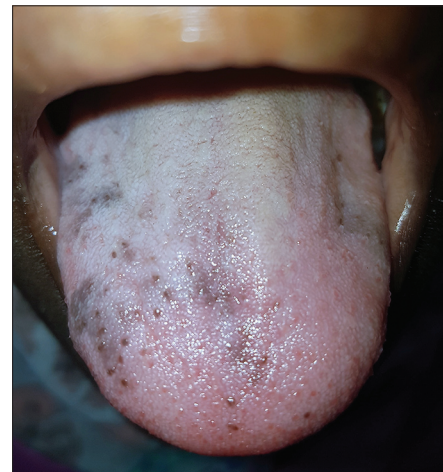

Figure 1: Pigmented fungiform papillae on the lateral border and dorsum of the tongue.

Different authors described an association with iron deficiency, haemochromatosis, anaemia or ichthyosis linearis circumflexa. In a clinical analysis of 58 Chinese cases of PFPT (2 males, 56 females), the authors hypothesise that certain pigmentary defects are possible triggered by abnormal secretion or fluctuation of sex hormones, with consequent the dropped-off melanin in the dermis [2].

The differential diagnosis of PFPT includes other causes of pigmentation of the oral mucosa, such as haemochromatosis, pernicious anaemia, amalgam tattoo, Peutz Jeghers syndrome, von Recklinghausen syndrome, Addison disease and black hairy tongue [3]. No effective treatment for PFPT has been described.

We describe the first case of PFPT in a Moroccan woman. It's a rare benign entity which often leads to unnecessary investigations.

How to cite this article: El Anzi O, Maouni S, Meknassi I, Hassam B. Pigmented fungiform papillae of the tongue: Moroccan case. Our Dermatol Online. 2019;10(2):215-216.

Submission: 22.10.2018; **Acceptance:** 10.12.2018

DOI: 10.7241/ourd.20192.32

Consent

The examination of the patient was conducted according to the Declaration of Helsinki principles.

REFERENCES

1. Karine Francine Docx M, Vandenberghe P, Govaert P. Pigmented fungiform papillae of the tongue (PFPT). *Acta Clin Belg.* 2016;71:117-8.
2. Werchniak AE, Storm CA, Dinulos JG. Hyperpigmented patches on the tongue of a young girl. Pigmented fungiform papillae of the tongue. *Arch Dermatol.* 2004;140:1275-80.
3. Marcoval J, Notario J, Martín-Sala S, Figueras I. Pigmentation of the fungiform papillae of the tongue: a report of 2 cases. *Actas Dermosifiliogr.* 2011;102:739-40.

Copyright by Ouiam El Anzi, et al. This is an open-access article distributed under the terms of the Creative Commons Attribution License, which permits unrestricted use, distribution, and reproduction in any medium, provided the original author and source are credited.

Source of Support: Nil, **Conflict of Interest:** None declared.

Cutaneous siderosis after extravasation of intravenous iron infusion

Mrinal Gupta

Department of Dermatology, Treatwell Skin Centre, Jammu and Kashmir, India

Corresponding author: Dr. Mrinal Gupta, E-mail: drmrinalgupta@yahoo.com

Sir,

A 40-year-old female presented to us with a 2-month history of an asymptomatic, hyperpigmented patch over the dorsal aspect of left forearm and wrist. There was no history of any similar lesion at any other body site or in the family members. There was no history of application of any topical medication at the site, but, the patient gave history of extravasation of iron infusion at the same site three weeks prior to onset of the lesion, which was administered to her for severe anemia. At the time of extravasation, there was diffuse swelling and erythema at the site for which she was given some analgesics and it subsided within two days. The patient noticed the lesions after three weeks which remained asymptomatic and non-progressive. On examination, a diffuse grayish-brown macule with well defined margins was present over the dorsal aspect of the left forearm and wrist (Fig. 1a). Laboratory investigations including the iron studies were normal. Histopathology of the macule revealed clustered brown granules consistent with iron pigmentation, seen mostly around the veins in the dermis, which on Prussian blue staining stained blue (Figs. 1b and 1c). On the basis of history, clinical and histopathological examination, a diagnosis of cutaneous siderosis was made and the patient was advised laser treatment for the same, which she refused owing to the long duration of treatment.

The accumulation of various metal salts in the body may result in pigmentation of the skin, like argyrosis develops after treatment with silver and chrysiasis develops after treatment with gold salts. Siderosis is a disease characterized by the accumulation of iron in various tissues, and can be seen as a side-effect in the injection area after parenteral iron treatment [1]. Cutaneous siderosis after intramuscular iron injections

is a well documented condition, but siderosis secondary to extravasation of intravenous iron infusion has been rarely reported [1-4]. It usually manifests as varying shades of grey-brown with no distinct contours at the site of injection. Histological findings in drug-induced siderosis are highly variable; however, dermal pigment particles are often concentrated in the macrophages. Numerous iron loaded macrophages can be seen with perivascular and periadnexal settlements in the entire dermis, and iron deposition can reach the subcutaneous

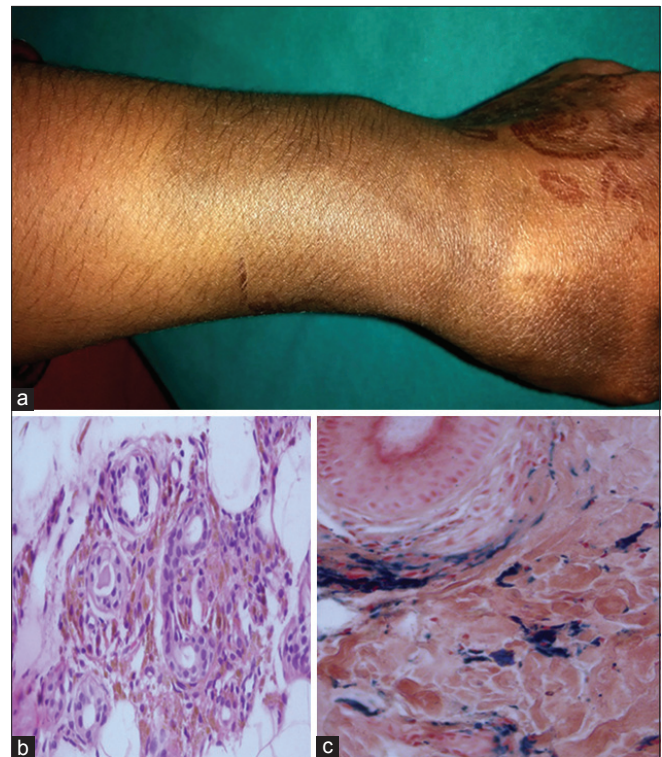


Fig 1:(a)- Greyish-brown macule over dorsal aspect of forearm and wrist. (b) – Perivascular clustered brown granules (H&E 40X). (c) – Prussian blue staining showing perivascular blue granules in the dermis (Prussian blue 40X).

How to cite this article: Gupta M. Cutaneous siderosis after extravasation of intravenous iron infusion. Our Dermatol Online. 2018;10(2):217-218.

Submission: 29.04.2018; **Acceptance:** 18.06.2018

DOI:10.7241/ourd.20192.33

tissues. Sometimes the localized deposition of pigment particles in dermal vessels and adnexal structures can be seen. The deposition of iron can be confirmed by Prussian blue staining, which stains the iron particles [5].

The treatment of drug-induced hyperpigmentation is usually cessation of the drug. Recently, laser therapy has been used in some cases, and promising results have been obtained [2-4]. Raulin et al used Q-Switch laser therapy in patients who developed hyperpigmentation after intramuscular iron therapy, obtaining significant color lightening in the lesions in all cases; however, they could not attain complete regression [3]. Lloyd et al also achieved significant clearing of the lesion with Q-switched alexandrite laser after four sittings [4].

CONSENT

The examination of the patient was conducted according to the Declaration of Helsinki principles.

REFERENCES

1. Ozlu E, Karadag AS, Bilgili SG, Baram I. Cutaneous siderosis after intramuscular iron injections: a case report. *Cutan Ocul Toxicol*. 2014;33:348–50.
2. Lloyd AA, Graves MS, Ross EV. Cutaneous siderosis secondary to intramuscular iron dextran treated with 755-nm Q-switch alexandrite laser: A case report. *Lasers Surg Med*. 2015;47:386-7.
3. Raulin C, Werner S, Greve B. Circumscribed pigmentations after iron injections-treatment with Q-switched laser systems. *Lasers Surg Med*. 2001;28:456–60.
4. Ghorbel HH, Lacour JP, Passerson T. Successful treatment with 532-nm Q-switched Nd: YAG laser of cutaneous siderosis following intravenous iron extravasation. *J Eur Acad Dermatol Venereol*. 2015;29:818-9.
5. Akimoto M, Hara H, Suzuki H. Metallosis of the skin mimicking malignant skin tumour. *Br J Dermatol*. 2003;149:653.

Copyright by Mrinal Gupta. This is an open-access article distributed under the terms of the Creative Commons Attribution License, which permits unrestricted use, distribution, and reproduction in any medium, provided the original author and source are credited.

Source of Support: Nil, **Conflict of Interest:** None declared.

Dermatology Eponyms – sign –Lexicon (T). Part 1

Piotr Brzeziński^{1,2}, Yasmeen Jabeen Bhat³, Ouiame El Jouari⁴, Rakesh Bharti⁵, Patricia Chang⁶, Anca Chiriac⁷, Lorenzo Martini², Ashwin Devasya⁸

¹Institute of Biology and Environmental Protection, Department of Cosmetology, Pomeranian Academy, Slupsk, Poland, ²University of Siena, Department of Pharmaceutical Biotechnologies, Via A. Moro 2, 53100 Siena, Italy, ³Departments of Dermatology, STD & Leprosy, Government Medical College, University of Kashmir, Srinagar, India, ⁴Department of Dermatology and Venereology, University Hospital Hassan II, Fez, Morocco, ⁵AAHIVS (American Academy of HIV Medicine), BDC Research Center, 27-D, Sant Avenue, The Mall, Amritsar, Punjab, 143001, India, ⁶Department of Dermatology, Hospital General de Enfermedades IGSS and Hospital Angeles, Guatemala, ⁷Department of Dermato-Physiology, Apollonia University Iasi, Strada Muzicii nr 2, Iasi-700399, Romania, ⁸Department of Paedodontics and Preventive Dentistry, Kannur Dental College, Anjarakkandy, Kannur, Kerala, India

Corresponding author: Dr. Piotr Brzeziński, E-mail: brzezoo77@yahoo.com

ABSTRACT

Eponyms are used almost daily in the clinical practice of dermatology. And yet, information about the person behind the eponyms is difficult to find. Indeed, who is? What is this person's nationality? Is this person alive or dead? How can one find the paper in which this person first described the disease? Eponyms are used to describe not only disease, but also clinical signs, surgical procedures, staining techniques, pharmacological formulations, and even pieces of equipment. In this article we present the symptoms starting with (T) and other. The symptoms and their synonyms, and those who have described this symptom or phenomenon.

Key words: Eponyms; Skin diseases; Sign; Phenomenon

TANA SIGN

Papulovesicular pox-type lesions on arms and legs with fever. Caused by the zoonotic tanapox virus which lives in Asian and African monkey colonies [1].

TANNA SIGN

The people of Tanna produce evelated scars on their arms and chests. This is a sign of cosmetic mutilation [2].

TARABAGAN SIGN

An epizootic disease affecting marmots (tarabagans) in Mongolia. The disease resembles Bubonic plague, and is highly infective to man [3].

TARGET SIGN

Characteristic target lesions of the skin and erythema of the iris (Fig. 1). Seen in erythema multiforme and Stevens-Johnson syndrome [4-6]. Known as Target cells of the skin sign.

ALBERT MASON STEVENS

American paediatrician (1884-1945) (Fig. 2) [7,8].

FRANK CHAMBLISS JOHNSON

American paediatrician (1894-1934) (Fig. 3). Along with Albert Mason Stevens, is eponymously affiliated with Stevens-Johnson syndrome. Amateur botanist died tragically aged 40 falling from a cliff whilst collecting plant specimens [7,8].

How to cite this article: Brzeziński P, Bhat YJ, El Jouari O, Bharti R, Chang P, Chiriac A, Martini L, Devasya A. Dermatology Eponyms – sign –Lexicon (T). Part 1. Our Dermatol Online. 2019;10(2):219-223.

Submission: 07.12.2018; **Acceptance:** 10.03.2019

DOI: 10.7241/ourd.20192.34

TELLAI'S SIGN

Pigmentation of the eyelid in Graves' disease [9,10].

TENT SIGN

Solitary nodule that elevates the epidermis. For examples pilomatrixoma (Fig. 4) [11-13].

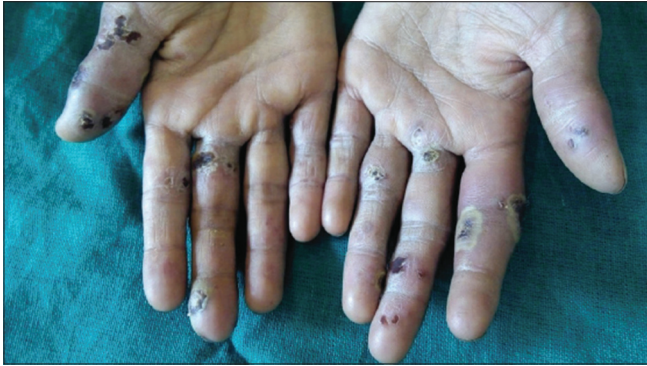

Figure 1: Target sign.




Figure 2: Albert Mason Stevens.



Figure 3: Frank Chambliss Johnson.

THEBES SIGN

An act of femininity, when a man removes hair from his torso, increasing femininity for attractiveness. A practice associated with homosexuality.

GORGIDAS

Greek military leader, c. 378 BC (Fig. 5), was the first known Theban military leader of the Sacred Band of Thebes around 378 BC. The reasoning behind the Sacred Band was that lovers would fight more fiercely and more cohesively at each other's sides than would strangers with no philadelphic bonds. The Sacred Band was 150 pairs of lovers or best friends, a total of three hundred men, led by Gorgidas to their gallant end on the blood-drenched field of Chaeronea, in 338 BC.

THEOBALD SMITH'S SIGN

Guinea pigs which have been used for standardizing diphtheria antitoxin and have thus been injected with

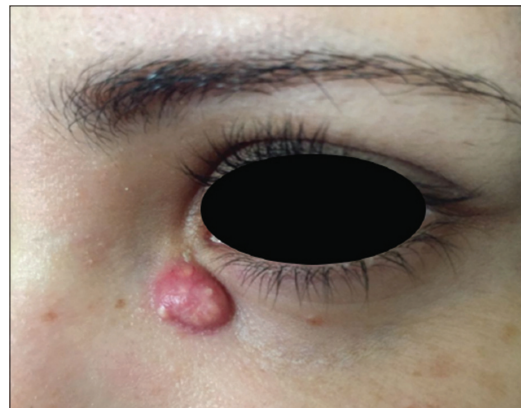

Figure 4: Tent sign.



Figure 5: Gorgidas.

a small dose of blood serum become highly susceptible to the serum and may die very promptly if given a rather large second dose of the same serum a few weeks later [14].

THEOBALD SMITH

American pathologist, 1859-1934 (Fig 6). Smith was a pioneer epidemiologist, bacteriologist, and pathologist who made many contributions to medical science that were of far-reaching importance. He is best known for his work on Texas cattle fever, in which he and his colleagues discovered the protozoan agent and its means of transmission by ticks. This was the first time that an arthropod had been definitively linked with the transmission of an infectious disease [14].

THICK TONGUE SIGN

Thickening of the tongue, an early sign found in leprosy. Also usually the patient's upper incisor teeth are very loose or have already fallen out [15].

THIMBLE SIGN

Nail changes in psoriasis include pitting (small, regularly placed pits, as on a thimble) (Fig. 7) [16-18].

THOMSON'S SIGN

Hemorrhagic lines appearing in body creases, as in the antecubital fossae, inguinal areas, and the wrists,




Figure 6: Theobald Smith.

during scarlet fever; they are visible at the onset of the rash and persist after its desquamation [19,20]. Also known as Pastia's sign.

FREDERICK HOLLAND THOMSON

British physician, 1867-1938

CONSTANTIN CHESSEC PASTIA

Romanian physician (1883-1926), known especially because of the description of Pastia's sign (or the sign Grozovici-Pastia) [21]. He made medical studies at the Faculty of Medicine in Bucharest and he prepared his doctoral thesis in medicine entitled "Opsonines and opsonic method in typhoid fever. The Influence of Some Drugs on Opsonic Power (Clinical and Experimental Research)" in Professor Cantacuzino's Experimental Medicine Laboratory and Professor Nanu-Muscel's Medical Clinic, which he defended in 1910 [22]. He studied infectious diseases and worked at Colentina Hospital.

THUMB SIGN (STEINBERG SIGN)

In patients of Marfan syndrome, the thumbs protrude from the clenched fist beyond the ulnar border of hand [23].

TISSUE PAPER SIGN

The circular tissue paper scar of a healed gumma (Fig. 8), evidence of a previous syphilitic infection [24].

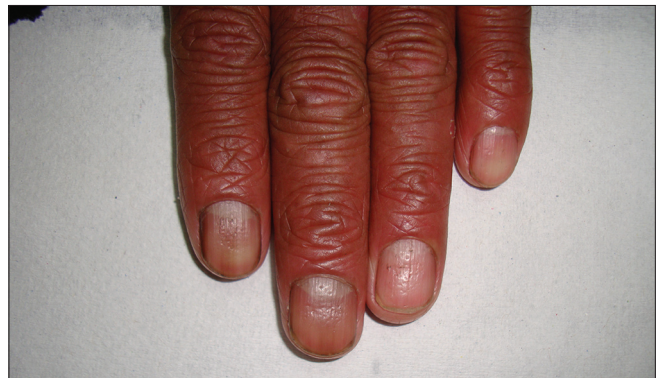

Figure 7: Thimble sign.

TIN TACK SIGN

Follicular orifices may become dilated and filled with horny plugs – the so-called tin tack sign [25,26]. Chronic discoid lupus erythematosus (CDLE)

TOMMASO'S SIGN

Alopecia on the posterolateral aspect of the legs (Anterolateral Leg Alopecia), idiopathic (Fig. 9) or found often in men with gout [27].

LODOVICO TOMMASI

Italian physician (1873-1945). Taught at the University of Modena from 1923 till 1943. he was the first who built dormitories for men and dormitories for women and let ambulatories of saerology and physics-chemistry built only at the first floor of the building, and so the department of physical education and rehabilitation and the rooms for assistants even at the first floor and amplified libraries, giving a n avalanche of volumes and books to the libraries themselves of the hospitals. Each lane of the ward was composed of 63 beds and many of those were shred in order to create new spaces for some separate living room.

Bosellini focused his teaching on the clearing of the dermatology as branch of Internal Medicine and attempted to deepen all the possible liasions between these two scientific subjects. All his individual contributions were valuable for the study of the aethiology of tuberculosis and especially for the research in the field of the hypertrophic tuberculoma, of the pustulous tuberculomas and rupias, of the cutaneous granulomas, of eczema rubrum and morva acuta and moreover of the chronic art dermatosis [28,29]. He dedicated all his life to the study of dermophysiopathology and preferred to follow a clinical and functional approach to this concern. He went on with the insertion of the Dermatology in the field of the domain of the Internal Medicine (the same route Bosellini, his master had begun). He studied deppsr all the erythrodermias, lupus eritematosus and the syphilitic milieu and dermatitities due to pyogenes, His revolutionary innovations of all this medical acquis were the rabies vaccine and the vaccine against lupus eritematosus owing to the usage of sodium salicylate.

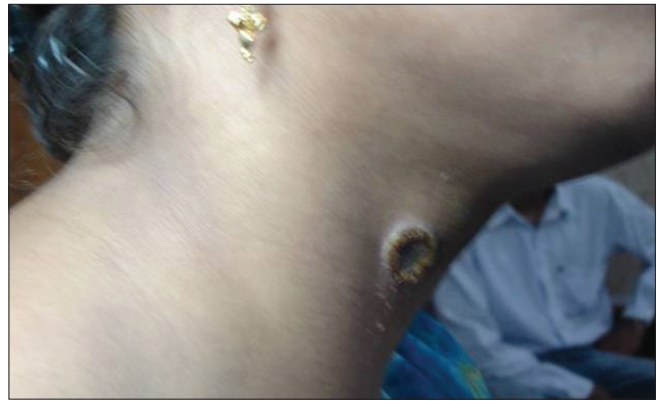

Figure 8: Tissue Paper sign.

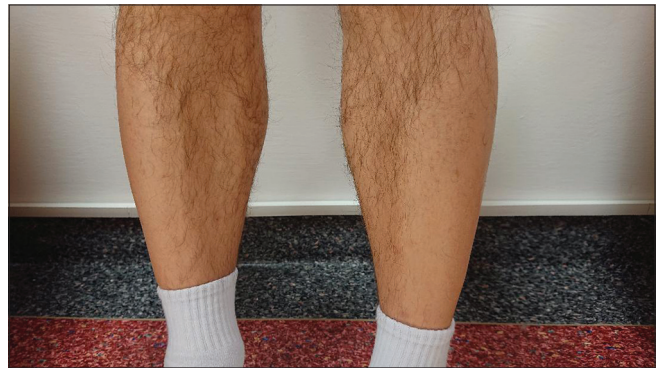

Figure 9: Tommaso's sign.

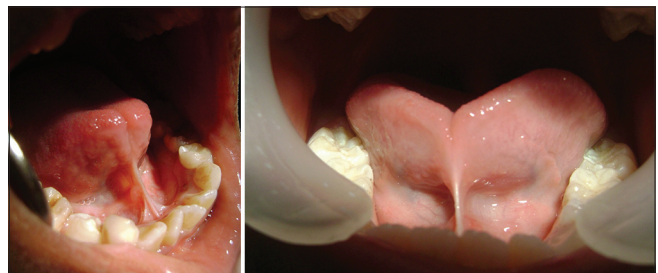


Figure 10: Tongue Tie sign.

TONGUE TIE SIGN

An abnormally broad or short lingual frenum that is attached close to the tip of the tongue. (Fig. 10) [30].

ACKNOWLEDGEMENTS

Dr Gabriel Sunil Rodrigues from General Surgery, Kasturba Medical College, Manipal Academy of Higher Education, Manipal, Karnataka, India

REFERENCES

1. Croitoru AG, Birge MB, Rudikoff D, Tan MH, Phelps RG. Tanapox virus infection. *Skinmed.* 2002;1:156-7.

2. Harris M, Nako D, Hopkins T, Powell DM, Kenny C, Carroll C, et al. Skin infections in Tanna, Vanuatu in 1989. *P N G Med J*. 1992;35:137-43.
3. Cui YJ, Yang RF. [Natural plague focus and genome diversity of tarabagan pestis in Himalayan]. *Zhonghua Yu Fang Yi Xue Za Zhi*. 2013;47:1078-9.
4. Brzezinski P. Erythema multiforme-like impetigo in 10-years-old-girl. *Our Dermatol Online*. 2017;8(4e):e3.
5. Bhat YJ, Zeerak S, Baba AN, Hassan I, Wani R. Recurrent erythema multiforme with arthritis – A rare association. *Our Dermatol Online*. 2017;8(2):179-182.
6. Wafa C, Faida A, Najeh B, Fatma A, Salah O, Habib SM. Erythema nodosum revealing acute myeloid leukemia. *Our Dermatol Online*. 2013;4:333-4.
7. Al Aboud K, Al Aboud A. Eponyms in the dermatology literature linked to the oral disorders. *Our Dermatol Online*. 2013;4:247-50.
8. Al Aboud K, Al Aboud D. Eponyms linked to vaccines and its reactions. *Our Dermatol Online*. 2013;4:559-63.
9. Anania C, Rubinfeld S. Hyperpigmentation in Graves' disease. *Thyroidology*. 1989;1:127-9.
10. Brzeziński P, Chiriac A, Munsey C, Sinjab AT. Dermatology Eponyms – Sign – Lexicon – (J). *Our Dermatol Online*. 2013;4:399-402.
11. Graham JL, Merwin CF. The tent sign of pilomatricoma. *Cutis*. 1978;22:577-80.
12. Harbaoui S, Youssef S, Ben Lagha I, Daadaa N, Jaber K, Dhaoui MR, Doss N. Multiple and giant perforating pilomatricoma: a case report. *Our Dermatol Online*. 2018;9(299-301).
13. Corredor-Osorio R, Suarez-Tata M, Orellana ME. Pilomatricoma of the orbit. *Our Dermatol Online*. 2016;7:188-90.
14. Schultz M. Theobald Smith. *Emerg Infect Dis*. 2008;14:1940-2.
15. Pallagatti S, Sheikh S, Kaur A, Aggarwal A, Singh R. Oral cavity and leprosy. *Indian Dermatol Online J*. 2012;3:101-4.
16. Tsiskarishvili NV, Katsitadze AG, Tsiskarishvili NI. [Assessment of psoriatic nail lesions therapy by means of nail psoriasis severity index]. *Georgian Med News*. 2011;(199):43-7.
17. Alanazi S, Arafat N. Unusual presentation of psoriasis. *Our Dermatol Online*. 2018;9:187-9.
18. Puri N, Puri A. A study on tinea capitis in the pre school and school going children. *Our Dermatol Online*. 2013;4:157-60.
19. Brzezinski P, Chang P, Fan R-Y, Krishnan V, Peh WCG, Francès P, et al. Eponyms – sign – Lexicon (P). Part 1. *Our Dermatol Online*. 2016;7:244-52.
20. Al Aboud K, Al Aboud K. Names of „Lines” in dermatology literature. *Our Dermatol Online*. 2013;4:251-3.
21. Marcu N. Viata si activitatea Doctorului Constantin C. Pastia (1883-1926). *Rev Ig Bacteriol Virusol Parazitol Epidemiol Pneumoftiziol Bacteriol Virusol Parazitol Epidemiol*. 1983;;28:89-95.
22. Pastia CC. Opsoninele si metoda opsonică în febra tifoidă. Influenta cătorva substante medicamentoase asupra puterei opsonice (cercetări clinice si experimentale). Bucuresti, Institutul de Arte Grafice „Speranta”, 1910.
23. Inamadar AC, Palit A. Cutaneous signs in heritable disorders of the connective tissue. *Indian J Dermatol Venereol Leprol*. 2004;70:253-5.
24. Bharti R. Gummas. *N Dermatol Online*. 2011;2:153.
25. Paramsothy Y, Lawrence CM. ‘Tin-tack’ sign in localized pemphigus foliaceus. *Br J Dermatol*. 1987;116:127-9.
26. Hassan ML, Sanchez GF, Calb IL, Casas JG. [Chronic hypertrophic discoid lupus erythematosus mimicking squamous-cell neoplasia]. *Our Dermatol Online*. 2016;7:30-6.
27. Srinivas SM, Sacchidanand S, Jagannathan B. Anterolateral Leg Alopecia. *Int J Trichology*. 2016;8:49-50.
28. Schiavo AL, Ruocco V, Marino F, Ferraiolo S, Pinto F, Orlando G. Tommaso de Amicis, Augusto Ducrey, Lodovico Tommasi: three Neapolitan stars in the dermatovenereology firmament. *Int J Dermatol*. 1996;35:57-62.
29. Bosco I. [In memory of Lodovico Tommasi]. *Ann Ital Dermatol Sifilogr*. 1956;11:1-4.
30. Devasya A, Sarpangala M. Familial ankyloglossia -A rare Report of three cases in a family. *J Clin Diagn Res*. 2017;11:ZJ03-4.

Copyright by Piotr Brzeziński, et al. This is an open-access article distributed under the terms of the Creative Commons Attribution License, which permits unrestricted use, distribution, and reproduction in any medium, provided the original author and source are credited.
Source of Support: Nil, **Conflict of Interest:** None declared.

Dermatology Eponyms – sign –Lexicon (T). Part 2

Piotr Brzeziński^{1,2}, Lorenzo Martini², Beatriz María Di Martino Ortiz³, Vijaya Sajjan⁴, Masashi Narita⁵, Yuko Ono⁶, Ramesh Parajuli⁷, Biswajit Dey⁸, Guilherme Moraes Krüger⁹, Patrice Bourée¹⁰

¹Institute of Biology and Environmental Protection, Department of Cosmetology, Pomeranian Academy, Slupsk, Poland, ²University of Siena, Department of Pharmaceutical Biotechnologies, Via A. Moro 2, 53100 Siena, Italy, ³Department of Dermatology, Clinicas Hospital, Faculty of Medical Sciences, National University of Asuncion, Paraguay, ⁴Department of Dermatology, Venereology and Leprosy, Jawaharlal Nehru Medical College, Belgaum, Karnataka, India, ⁵Department of Medicine, Ohta Nishinouchi General Hospital, Nishinouchi 2-5-20 Koriyama, Fukushima, Japan, ⁶Critical Care Center, Ohta General Hospital Foundation, Ohta Nishinouchi Hospital 2-5-20 Nishinouchi, Koriyama, Fukushima, Japan, ⁷Department of Otorhinolaryngology, Chitwan Medical College Teaching Hospital, Chitwan, Nepal, ⁸Department of Pathology, Andaman and Nicobar Islands Institute of Medical Sciences, Port Blair, Andaman and Nicobar, ⁹Dermatology Service of the Universidade Federal do Mato Grosso do Sul (UFMS) - Campo Grande (MS), Brazil, ¹⁰Unité des maladies parasitaires, Hôpital Cochin, 75014 Paris, France

Corresponding author: Dr. Piotr Brzeziński, E-mail: brzezoo77@yahoo.com

ABSTRACT

Eponyms are used almost daily in the clinical practice of dermatology. And yet, information about the person behind the eponyms is difficult to find. Indeed, who is? What is this person's nationality? Is this person alive or dead? How can one find the paper in which this person first described the disease? Eponyms are used to describe not only disease, but also clinical signs, surgical procedures, staining techniques, pharmacological formulations, and even pieces of equipment. In this article we present the symptoms starting with (T) and other. The symptoms and their synonyms, and those who have described this symptom or phenomenon.

Key words: Eponyms; Skin diseases; Sign; Phenomenon

TORI SIGN

Hyperostosis occurring in the midline of the hard palate (Fig. 1), called torus palatinus or hyperostosis located on the lingual aspect of the mandible, termed torus mandibularis [1].

TRAMP STAMP SIGN

Tattoos on women that are not religious or ceremonially required for their culture. Often on the lower back area; they were originally used to signify a life of prostitution. This practice continues today but sometimes these tattoos are now seen in the non-prostitute population, as sign of admiration for the romanticized prostitution

lifestyle which is linked to drug abuse, physical violence, and sexually transmitted diseases. The origin of the term dates from the 17th century Yakuza practice of tattooing prostitutes on the back. Prostitutes in the Edo period, called 'Yujo' tattooed themselves with the name of their regular customer as a sign of their loyalty. This tattoo is referred to as 'Irezumiko', which starts with the customer's name and ends with the kanji character 命 (inochi), which means life, so this tattoo means "I give my life to 'name'."

TOY SOLDIER SIGN

Linear aggregation of neoplastic lymphocytes along the dermal-epidermal junction seen in histopathology of mycosis fungoides (Fig. 2) [2].

How to cite this article: Brzeziński P, Martini L, Di Martino OB, Sajjan V, Narita M, Ono Y, Parajuli R, Dey B, Krüger GM, Bourée P. Dermatology Eponyms – sign –Lexicon (T). Part 2. Our Dermatol Online. 2019;10(2):224-228.

Submission: 07.12.2018; **Acceptance:** 12.03.2019

DOI:10.7241/ourd.20192.35

TRENCH MOUTH SIGN

Linear gingival erythema, an erythematous band on the free gingiva that follows the contour with a reddish chevron appearance (Fig. 3). An indication of HIV disease [3-6]. Painful, acute necrotizing ulcerative gingivitis. Also called HiVR and NUP signs, ulceromembranous gingivitis, Vincent's infection, Vincent's War sign, and ANUG sign.

HENRI VINCENT

French physician, 1862-1950. His name is associated with Vincent's Disease or Vincent's Angina. It is also

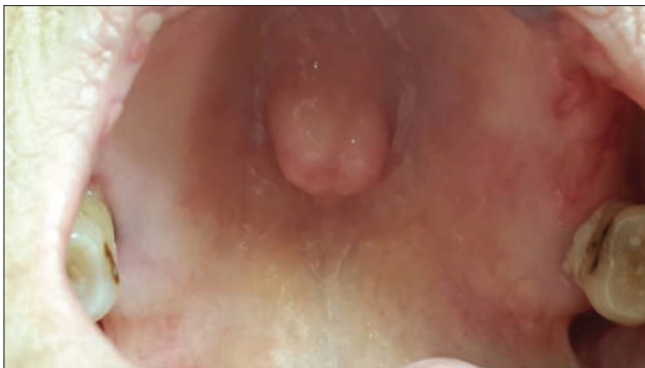

Figure 1: Tori sign.

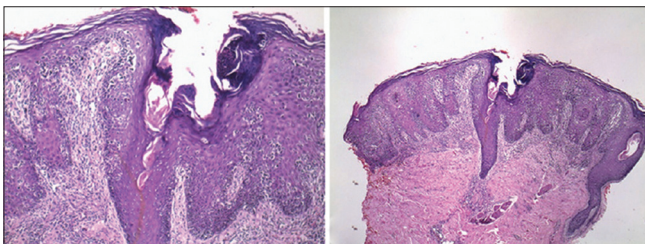


Figure 2: Toy Soldier sign.

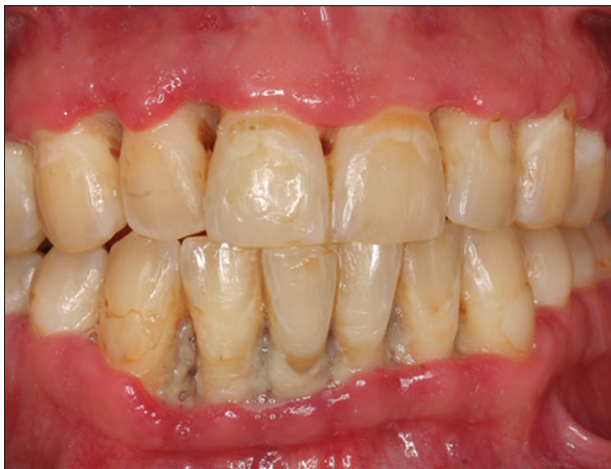

Figure 3: Trench Mouth sign.

widely known as Trench Mouth, due to an outbreak in soldiers in trenches during World War One. *Borrelia vincentii* used to be spread out worldwide, but is now mainly in countries that are not very developed [3,4].

TSUTSUGAMUSHI SIGN

An epidemic disease of Japan due to a zoonotic proteus implanted by the bite of a mite (kedani). It is marked by fever, swelling of the lymph-glands, and an exanthematous eruption fever [7]. Synonym: akamushi disease, flood fever, inundation fever, island disease, island fever, Japanese river fever, kedani fever, mite typhus, scrub typhus (Fig. 4), shimamushi disease, tropic typhus, tsutsugamushi.

TUBERCULOUS ULCER SIGN

An ulcer that is characterized by undermined edges and is usually painful (Figs. 5A and B) [8,9].

TUNGA EYE SIGN

A skin boil that has the resemblance of a small eye (Fig. 6). It can have a 10mm white area with a black center. The black center is the abdomen's caudal tip of the parasitic chigoe flea that has burrowed into the skin to lay eggs [10,11].

TURNER'S SIGN

Discoloration (bruising) of the skin of the loin in acute hemorrhagic pancreatitis; adverse prognostic (Fig. 7). Also known as Grey Turner's sign [12].

GEORGE GREY TURNER

English surgeon, 1877-1951 (Fig. 8). Served with the Royal Army Medical Corps in the First World War. First described in 1920 Grey Turner's sign, in the British Journal of Surgery, it was described as a sign of hemorrhagic pancreatitis. As a young surgeon, he travelled around the world, being received by the Pope, Benito Mussolini, the King of Italy and King Alfonso of Spain. Five years before his death, Grey Turner was made President of the International Society of Surgeons. After the war, Grey Turner was briefly famous for performing one of the earliest operations to attempt the removal of a bullet from a soldier's heart. The bullet

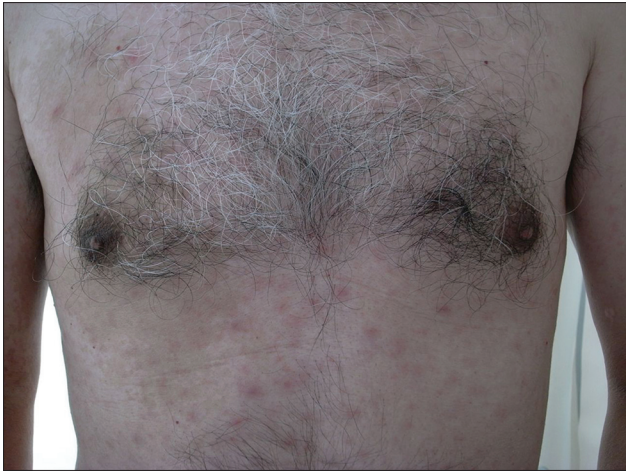

Figure 4: Tsutsugamushi sign.

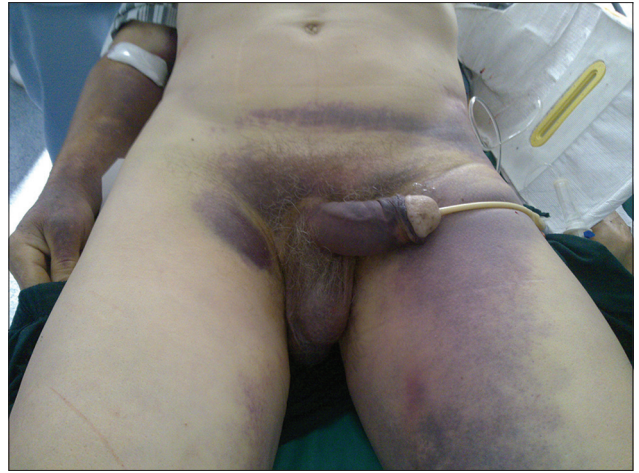

Figure 7: Turner's sign.

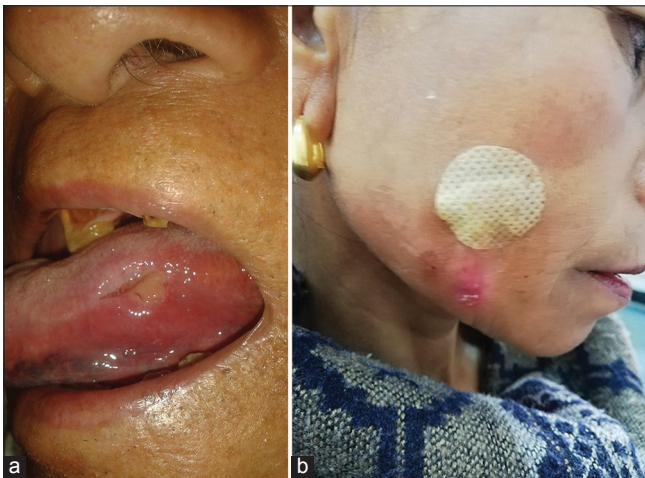

Figure 5: (a and b) Tuberculous Ulcer sign.



Figure 8: George Grey Turner.

TWIN NEVUS PHENOMENON (TWIN-SPOTTING' PHENOMENON)

The 'twin-spotting' phenomenon due to loss of heterozygosity and somatic recombination during late embryogenesis. The earlier the mutation during embryogenesis, the wider is the involvement of the skin, central nervous system and other structures, and, in contrast, later postzygotic mutations generate only skin involvement. Twin spotting phenomenon of Happle and Steijen has been proposed to explain this phenomenon (Phakomatosis pigmentovascularis) [13-15]. In this hypothesis, somatic mutations on nearby genes leads to mosaic spots in close proximity to one another. Phakomatosis pigmentovascularis has been classified into four types namely; type I: Nevus flammeus and epidermal nevus, type II: Nevus flammeus, Mongolian spots, \pm nevus anemicus, type III: Nevus

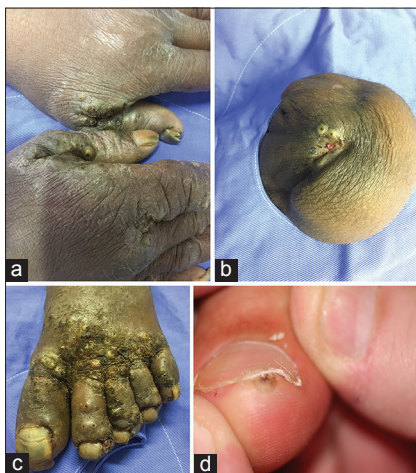

Figure 6: (a-d) Tunga Eye sign.

was never removed, but Grey Turner's surgery saved the patient's life. Worked with early cancer research, and anticipated the development of chemotherapy [12].

flammeus, nevus spilus, ± nevus anemicus, and type IV: Nevus flammeus, Mongolian spots, nevus spilus, ± nevus anemicus.

TWO GLASSES SIGN

This is sign in gonorrhoea. It should be remembered that purulent leakage from the coil is not enough to definitively diagnose the disease, because it can also be caused by many other causes. Confirmation of anterior urethral involvement may be so-called try two glasses. It consists in the fact that if the urine is put into two glasses, it will be cloudy in the first glass and in the second glass it will be transparent. The cloudy urine in both glasses indicates that the rear coil is also occupied.

TWORT-D'IERELLE SIGN

The phenomenon of transmissible bacterial lysis; bacteriophagia. When to a broth culture of typhoid or dysentery bacilli there is added a drop of filtered broth emulsion of the stool from a convalescent typhoid or dysentery patient, complete lysis of the bacterial culture will occur in a few hours. If a drop of this lysed culture is added to another culture of the bacilli, lysis will take place exactly as in the first. A drop of this culture will then dissolve a third culture, and so on through hundreds of transfers, d'I Ierelle attributes this phenomenon to the action of an ultramicroscopic parasite of bacteria which he named the bacteriophage [16].

FREDERICK WILLIAM TWORT

British bacteriologist, 1877-1950 (Fig. 9). Fellow of the Royal Society was an English bacteriologist and was the original discoverer in 1915 of bacteriophages (viruses that infect bacteria). He studied medicine at St Thomas's Hospital, London, was superintendent of the Brown Institute for Animals (a pathology research centre), and he was also professor of bacteriology at the University of London. He researched into Johne's disease, a chronic intestinal infection of cattle, and also discovered that vitamin K is needed by growing leprosy bacteria [17].

FELIX HUBERT D'HERELLE

French-Canadian microbiologist, 1873-1949 (Fig. 10). Generally known as the discoverer of the bacteriophage,



Figure 9: Frederick William Twort (by National Portrait Gallery).



Figure 10: Felix Hubert d'Herelle (by Institut Pasteur – Musée Pasteur)

a virus that infects bacteria. He experimented with the possibility of phage therapy. D'Herelle has also been credited for his contributions to the larger concept of applied microbiology. After studying medicine in Paris and Leiden, Hérelle went to Guatemala City to direct the bacteriology laboratory of the municipal hospital and teach microbiology at the local medical school. In 1909 he was sent by the Mexican government to study microbiology at the Pasteur Institute in Paris. While there, he experimented with a bacterium known to cause enteritis (digestive tract inflammation) in certain insects. In the course of his work Hérelle occasionally noticed clear spots (areas free of bacteria) on gelatin cultures of the bacterium under study. Subsequently he investigated a form of dysentery afflicting a French cavalry squadron during World War I, and he happened to mix a filtrate of the clear areas with a culture of dysentery bacteria. The bacteria were quickly and totally destroyed by an unknown agent in the filtrate

that Hérelle termed an “invisible microbe”; he later renamed it a bacteriophage [18].

TYNDALL PHENOMENON

Tyndall effect blue appearance of melanin in dermal lesions due to selective light absorption [19,20].

TYPHUS SIGN

A rash that spreads from the armpits to the chest, abdomen, and thighs [21]. A sign of Typhus.

REFERENCES

1. Re Domínguez ML, Riveros R, Moreno T, Di Martino Ortiz BM, Rodríguez Masi M, Knopfmacher O, et al. Torus palatinus. Report of two cases. *Our Dermatol Online*. 2016;7:169-71.
2. Sajjan V, Chandela M, Pandit AM, Manjunathswamy B. Mycosis fungoides: The great imitator. *Our Dermatol Online*. 2015;6:76-9.
3. Brzeziński P, Sinjab AT, Campbell CM, Kentorp N, Sand C, Karwan K. *Dermatology Eponyms – phenomenon/sign –Lexicon* (supplement). *Our Dermatol Online*. 2012;3:147-55.
4. Brzeziński P, Pessoa L, Galvão V, Barja Lopez JM, Adaskevich UP, Niamba PA, et al. *Dermatology Eponyms – Sign – Lexicon – (H)*. *Our Dermatol Online*. 2013;4:130-43.
5. Brzezinski P, Chiriac A, Rath SK. *Dermatology Eponyms – Sign – Lexicon – (M)*. *Our Dermatol Online*. 2014;5:442-7.
6. Brzezinski P, Chiriac A, Arenas R, Dori GU, Monteiro R, Cairncross S, et al. *Dermatology Eponyms – Sign – Lexicon – (L)*. *Our Dermatol Online*. 2014;5:217-30.
7. Brzezinski P, Fiorentino DF, Arunachalam P, Katafigiotis I, Matuszewski L, Narita M, et al. *Dermatology Eponyms – Sign – Lexicon – (K)*. *Our Dermatol Online*. 2014;5:95-102.
8. Parajuli R, Maharjan S. Tubercular ulcer of tongue in an elderly patient masquerading as a traumatic ulcer. *Case Rep Otolaryngol*. 2017;2017:8416963.
9. Rana S, Monga S, Khan S, Khetrpal S, Jetley S. Tubercular abscess of the lower lip: a rare case of mistaken identity. *Our Dermatol Online*. 2014;5:169-71.
10. Krüger GM, Loro LS, Takita LC, Hans G Filho. Disseminated tungiasis. *An Bras Dermatol*. 2017;92:727-8.
11. Martini L. The way to cure a complicate syndrome caused by an insect (parasite) using a cerumen extracted from another insect (no parasite, that lives in some countries where the first disease is endemic). *Our Dermatol Online*. 2018;9:140-3.
12. Brzezinski P, Sinjab AT, Masferrer E, Gopie P, Naraysingh V, Yamamoto T, et al. *Dermatology Eponyms – sign –Lexicon (G)*. *Our Dermatol Online*. 2012;3:243-57.
13. Jehangir M, Quyoom S, Bhat J, Sajad P, Sofi I, Amin A, et al. Phacomatosis pigmentovasularis with lower limb vascular abnormalities in a young Kashmiri male child-Report of a first child from Kashmir Valley (India) and review of literature. *Our Dermatol Online*. 2016;7:87-90.
14. Happle R. Allelic somatic mutations may explain vascular twin nevi. *Hum Genet*. 1991;86:321-2.
15. Karia DR, Solanki AN, Jagati AG, Shah BJ. Phacomatosis pigmentokeratocica: A very rare twin spotting phenomenon. *Indian J Dermatol Venereol Leprol*. 2018;84:120.
16. Zaviľgel'skiĭ GV, Kotova VIu, Rastorguev SM. [Antimodification activity of the Arda and Ocr proteins]. *Genetika*. 2011;47:159-67.
17. Thomas GH. Frederick William Twort: Not just bacteriophage. *Microbiology Today*. 2014;41:70-3.
18. Summers WC Félix Hubert d'Herelle (1873-1949): History of a scientific mind. *Bacteriophage*. 2017;6:e1270090.
19. Xue R, Valdebran M, Terrero D, Yang B. Plaque with pearly raised borders on the forearm. *Our Dermatol Online*. 2016;7:103-4.
20. Valdebran M, Salinas RI, Ramirez N, Rodriguez A, Guzman L, Marte S, et al. Fixed drug eruption of the eyelids. A dermoscopic evaluation. *Our Dermatol Online*. 2013;4:344-6.
21. Brzeziński P, Passarini B, Nogueira A, Sokolowska-Wojdylo M. *Dermatology eponyms – phenomenon/sign –dictionary (C)*. *N Dermatol Online*. 2011;2:81-100.

Copyright by Piotr Brzeziński, et al. This is an open access article distributed under the terms of the Creative Commons Attribution License, which permits unrestricted use, distribution, and reproduction in any medium, provided the original author and source are credited.
Source of Support: Nil, **Conflict of Interest:** None declared.



O u r D e r m a t o l o g y O n l i n e

w w w . o d e r m a t o l . c o m

2.2019 (09 April.2019)